

Focal HIFU	<p><i>Comparing High-Intensity Focal Ultrasound Hemiablation to Robotic Radical Prostatectomy in the Management of Unilateral Prostate Cancer: A Matched-Pair Analysis.</i> Simone Albisinni et al. - Journal of Endourology - Volume 31, Number 1, January 2017: Pp. 14–19 - DOI: 10.1089/end.2016.0702.</p>
	<p><i>Focal High Intensity Focused Ultrasound of Unilateral Localized Prostate cancer: A Prospective Multicentric Hemiablation Study of 111 Patients.</i> Pascal Rischmann et al. – Eur Urol 2017 ; 71 :267-73</p>
	<p><i>Focal High-intensity Focused Ultrasound Targeted Hemiablation for Unilateral Prostate Cancer: A Prospective Evaluation of Oncologic and Functional Outcomes</i> Ernesto R. Cordeiro Feijoo et al. - Eur Urol 2015 : j.eururo.2015.06.018</p>
	<p><i>Hemi salvage high-intensity focused ultrasound (HIFU) in unilateral radio-recurrent prostate cancer: a prospective two-centre study</i> Baco E et al. – BJU Int. 2013 Oct 31. [Epub ahead of print]</p>
First-line HIFU	<p><i>Whole-gland Ablation of Localized Prostate Cancer with High-intensity Focused Ultrasound: Oncologic Outcomes and Morbidity in 1002 Patients</i> Crouzet S et al. – Eur Urol. 2014 May ;65(5) :907-14</p>
	<p><i>Evolution and outcomes of 3 MHz High intensity focused ultrasound therapy for localized prostate cancer over 15 years.</i> Thüroff S et al. - Journal of Urology 2013 Feb (online)</p>
	<p><i>Fourteen-year oncological and functional outcomes of high-intensity focused ultrasound in localized prostate cancer.</i> Ganzer R et al. - BJUI 2013 Jan (online)</p>
	<p><i>Multicentric Oncologic Outcomes of High-Intensity Focused Ultrasound for Localized Prostate Cancer in 803 Patients</i> Crouzet S et al. - Eur Urol. 2010 Oct;58(4):559-66</p>
Salvage HIFU after EBRT	<p><i>Salvage high-intensity focused ultrasound (HIFU) for locally recurrent prostate cancer after failed radiation therapy: Multi-institutional analysis of 418 patients.</i> Sebastien Crouzet et al. - 2017 BJU International doi:10.1111/bju.13766</p>
	<p><i>Locally recurrent prostate cancer after initial radiation therapy: Early salvage high-intensity focused ultrasound improves oncologic outcomes</i> Crouzet S et al. - Radiotherapy and Oncology 2012; Nov;105(2):198-202</p>
	<p><i>A prospective study of salvage high-intensity focused ultrasound for locally radio-recurrent prostate cancer: Early results</i> Berge V et al. – Scand. J. Urol. Nephrol. 2010; Sep;44(4):223-7.</p>

HIFU publications

The essential peer reviewed articles



Review article	<p><i>Transrectal High Intensive Focused Ultrasound (HIFU) for the treatment of Prostate Cancer: A historical review</i></p> <p>Chaussy CG et al. - June 2017 Internal Medicine Review. All Rights Reserved. Vol 3, Issue 4..</p>
Salvage Radical Prostatectomy	<p><i>HIFU as salvage first-line treatment for palpable, TRUS-evidenced, biopsy-proven locally recurrent prostate cancer after radical prostatectomy: A pilot study</i></p> <p>Asimakopoulos AD et al. - Urol Oncol. 2011 Feb 1</p>
Salvage EBRT after HIFU	<p><i>Salvage Radiotherapy After High-Intensity Focussed Ultrasound for Recurrent Localised Prostate Cancer</i></p> <p>Riviere J et al. - Eur Urol. 2010 Oct;58(4):567-73</p>



Comparing High-Intensity Focal Ultrasound Hemiablation to Robotic Radical Prostatectomy in the Management of Unilateral Prostate Cancer: A Matched-Pair Analysis

Simone Albisinni, MD, Fouad Aoun, MD, Simon Bellucci, MD, Ibrahim Biaou, MD, Ksenija Limani, MD, Eric Hawaux, MD, Alexandre Peltier, MD, and Roland van Velthoven, MD, PhD

Abstract

Introduction: Although still experimental, focal treatment is being increasingly implemented in the management of prostate cancer (PCa). Aim of the current study was to compare functional and oncologic outcomes of high-intensity focal ultrasound (HIFU) hemiablation of the prostate to robot-assisted laparoscopic prostatectomy (RALP) in the management of unilateral PCa.

Materials: Fifty-five men with unilateral, clinically localized PCa underwent HIFU hemiablation of the affected prostatic lobe between 2007 and 2015. All patients were found to have unilateral disease on the basis on full concordance between multiparametric magnetic resonance imaging (MRI) and MRI-guided biopsies. These patients were matched 1:1 with patients who underwent RALP for PCa in which pT2a-b disease (unilateral) was found on final pathologic analysis. Matching criteria were Gleason score, prostate specific antigen (PSA), and cT stage. Treatment failure was defined as the need for salvage external beam radiotherapy or systemic androgen deprivation therapy (ADT) due to disease progression. Kaplan–Meier curves and log-rank tests were constructed to assess differences in salvage treatment free survival across surgical techniques.

Results: Matching was effective with no significant differences across the two groups, although men treated with HIFU were older ($p < 0.001$). Median follow-up was 36 months (interquartile range 16–56). HIFU was associated to better and faster recovery of continence, with most men (82%) showing no signs of urinary incontinence even right after surgery. Moreover, the risk of *de novo* erectile dysfunction was significantly lower after HIFU. No significant difference was found in the need for salvage external beam radiation therapy or ADT across the two surgical approaches: 7/55 men underwent salvage therapy in the HIFU vs 6/55 in the RALP group ($p = 0.76$). Nonetheless, seven more patients in the HIFU arm required a complementary treatment on the contralateral lobe during follow-up, after developing a contralateral PCa. No patient died of PCa on follow-up, while six men died of other causes (five HIFU vs one RALP, $p = 0.11$).

Conclusion: In this matched pair analysis, HIFU hemiablation was comparable to RALP in controlling localized unilateral PCa, with no significant differences in the need for salvage therapies. HIFU was also associated to significantly better functional outcomes. Accurate patient selection remains vital, and larger prospective trials are needed to confirm our findings.

Keywords: HIFU, prostate cancer, robotic, unilateral

Introduction

PROSTATE CANCER (PCa) is a major health concern worldwide, being the second most common neoplasm and sixth cause of cancer-related death in the world.¹ Radical prostatectomy, today mainly performed using a robot-assisted ap-

proach (robot-assisted laparoscopic prostatectomy [RALP]), is a mainstay in the local control of disease. Nonetheless, the procedure is associated to significant morbidity and decline in quality of life due to continence and erectile deterioration after surgery.² In the effort to reduce such postoperative burden, pioneers have begun to explore the feasibility of focal therapy

in selected PCa patients.^{3–5} Although PCa is mainly multifocal, investigators have attempted to treat the so-called “index” lesion, which is considered the major determinant in the future pathologic evolution of the disease.⁶ Among the energy sources used for focal therapy, high-intensity focal ultrasound (HIFU) emerged as a valid minimally invasive therapy for selected patients,⁷ and recent studies have reported encouraging results for focal therapy delivered with HIFU.^{4,8,9} With increasing specificity of preoperative characterization of PCa, thanks to multiparametric magnetic resonance imaging (MRI) and MRI-guided targeted biopsies, patient selection is becoming increasingly precise, allowing optimal selection of patients for such a focal approach.

In our department we began performing HIFU hemiablation of the prostate 9 years ago,⁹ in patients with unilateral disease, proven by full correspondence between multiparametric MRI and MRI-guided targeted biopsies.¹⁰ In the same period we were also performing RALP for patients with low and intermediate risk PCa, of which some also harbored unilateral disease as demonstrated by final pathologic analysis. Aim of the current study was to compare functional and oncologic outcomes of HIFU hemiablation of the prostate to RALP in the management of unilateral PCa.

Patients and Methods

After institutional review board approval, we retrospectively analyzed patients undergoing HIFU prostatic hemiablation for unilateral disease and patients who underwent RALP for pT2a–pT2b (unilateral) PCa between 2007 and 2015.

For HIFU hemiablation, patients were selected if the positive biopsy pattern was in complete concordance with the PCa lesions identified by MRI with precise loci matching on multiparametric approach. We included men with localized PCa (\leq cT2), a prostate specific antigen (PSA) <15 ng/mL, a life expectancy of at least 5 years, and a prostate volume <40 cm³. We excluded patients who had extraprostatic extension on multiparametric MRI, suspected regional lymph nodes or distant metastases on cross-sectional imaging or bone scan, and/or previous HIFU or radiation therapy to the prostate. All patients underwent hemiablation using HIFU delivered by the Ablatherm integrated imaging system (EDAP-TMS, Vaulx-en-Velin, France), performed by a single surgeon (R.v.V.) with a high level of experience in whole-gland HIFU. HIFU hemiablation was defined as ablation of one lobe of the prostate and not just the index lesion because of device technical limitations. HIFU energy was delivered only to the hemi prostate gland, with no treatment of the ipsilateral neurovascular bundle within the technical feasibility of the approach.

Matching

Patients treated by HIFU prostatic hemiablation were matched 1:1 by propensity score analysis with patients undergoing RALP in the same years, in which unilateral PCa was detected on final pathologic report (pT2a–2b, unilateral disease). RALP was performed by three expert surgeons (R.v.V., A.P., and E.H.), all using the same surgical technique. A bilateral nerve sparing approach was performed in all cases. Urinary catheter was usually retrieved at day 5 postoperatively, after a retrograde cystography showed no leakage. The matching procedure was blinded to the out-

come, guaranteeing the sorting of patients according to the matching parameters without bias in their outcomes. Matching criteria were, in order: Gleason score, preoperative PSA, and cT stage (cT1c vs cT2). To confirm an appropriate matching, the absence of significant clinical and pathologic differences between the two cohorts of patients treated was assessed using Wilcoxon Rank-sum or χ^2 -test, as appropriate.

Functional follow-up

Urinary functional outcomes and erectile function were reported using patient-reported rates. Continence was considered in a categorical manner as 0 vs ≥ 1 pad. Patients were considered potent if erections, with or without iPDE5, were sufficient for intercourse.

Oncologic follow-up

Given the inherent difference across the two surgical approaches (organ-sparing vs radical extirpation), comparison of biochemical recurrence rates using PSA is inadequate. Moreover, there is currently no accepted definition for disease control following HIFU.^{11,12} We therefore decided to test difference in treatment failures, identified as the need for local salvage therapy (radiotherapy of surgery), hormonal therapy, or metastases.

High-intensity focal ultrasound. Given the presence of an untreated half-prostate, an individual PSA nadir was identified in each patient. Biochemical recurrence according to Phoenix criteria (Nadir $+2$ ng/mL)¹³ was used as a threshold to offer a new set of bilateral biopsies. Treatment failure was defined as positive biopsy of the treated area independent of the percentage of core involvement or if salvage radiation or hormonal therapy was needed during follow-up. Contralateral positive biopsy was not considered as a clinical failure, but as a metachronous development of a contralateral disease and was treated by a secondary contralateral hemiablation according to our protocol.

Robot-assisted laparoscopic prostatectomy. Biochemical recurrence was defined by a PSA level >0.2 ng/mL and subsequent rise.¹⁴ The date of the first PSA ≥ 0.2 ng/mL was used to define biochemical recurrence. Salvage radiotherapy or hormone therapy was offered according to PSA doubling time, pathologic Gleason score, and final pathologic report.

Kaplan–Meier curves and log-rank tests were performed to analyze the influence of the surgical approach on salvage treatment free survival. Statistical significance was considered for $p \leq 0.05$. Analyses were performed using STATA version 11.1 (StataCorp, TX).

Results

Fifty-five patients treated by HIFU hemiablation were identified and included in the study. These were matched 1:1 to 55 men who had undergone RALP with pT2a–2b stage in the same period. Matching was effective with no significant differences across the two groups (Table 1), although men treated with HIFU were older ($p < 0.001$).

TABLE 1. PATIENT CHARACTERISTICS AFTER MATCHING

	Focal HIFU	RALP	p
No. of patients	55	55	
Age (years)			<0.001 ^a
Median (IQR)	73 (70–77)	63 (57–68)	
Mean ± SD	73 ± 7	63 ± 7	
PSA (ng/mL)			0.98 ^b
Median (IQR)	6.9 (4.5–9.5)	6.5 (4.5–9.3)	
Mean ± SD	7.4 ± 4.8	7.8 ± 5.3	
Gleason score			0.89 ^a
≤6	36 (65%)	36 (65%)	
3+4	13 (24%)	13 (24%)	
4+3	4 (7%)	2 (4%)	
≥8	2 (4%)	4 (7%)	
cT			0.70 ^b
cT1c	23 (42%)	25 (45%)	
cT2	32 (58%)	30 (55%)	
D'Amico risk score			0.28 ^b
Low	26 (47%)	32 (58%)	
Intermediate	26 (47%)	18 (33%)	
High	3 (6%)	5 (9%)	

^aMann–Whitney test.

^b χ^2 -test.

HIFU = high-intensity focal ultrasound; IQR = interquartile range; PSA = prostate specific antigen; RALP = robot-assisted laparoscopic prostatectomy.

Concerning early postoperative complications, these were detected in 8/55 (15%) in the HIFU group and 11/55 (20%) in the RALP group ($p=0.71$). These events were mainly Clavien I complications, as prolonged acute urinary retention after HIFU and anastomotic leakage required

TABLE 2. PERIOPERATIVE AND POSTOPERATIVE OUTCOMES

	Focal HIFU	RALP	p
Hospital stay (days)	4 (3–5) 4 ± 1	7 (7–8) 8 ± 2	<0.001 ^a
Early complications	8 (15%)	11 (20%)	0.45 ^b
Grade early complications			0.71 ^b
Clavien I	7	7	
Clavien II	1	2	
Clavien III	0	0	
Clavien IV	0	1	
Continence (0 pads)			<0.001 ^b
1 month	82% (45)	40% (22)	
3 months	87.5% (48)	55% (30)	
6 months	89.5% (49)	71% (39)	
12 months	94.5% (52)	87% (48)	
24 months	94.5% (52)	91% (50)	
Incontinent	5.5% (3)	9% (5)	
Erectile dysfunction			0.03 ^b
Preop potent and active	30	48	
Potent at 1 month	80% (24)	15% (7)	
Potent at 12 months	80% (24)	38% (18)	
Potent at 24 months	80% (24)	56% (27)	
De novo persistent ED	20% (6)	44% (21)	

^aWilcoxon Rank-sum.

^b χ^2 .

Bold type indicates statistically significant values.

extra catheter days in the RALP group. All Clavien II complications were urinary tract infections. One patient developed malignant hypertension requiring intensive care in the RALP group. Length of stay was 4 days (interquartile range [IQR] 3–5) in the HIFU group and 7 (IQR 7–8) in the RALP group ($p<0.001$). Of note, our patients are allowed to leave the ward only after all catheters and drains are withdrawn.

Median follow-up was 36 months (IQR 16–56). Concerning functional outcomes (Table 2), HIFU was associated to better and faster recovery of continence, with most men (82%) showing no signs of urinary incontinence (0 pads) even just after surgery. This rate was significantly more elevated compared to patients undergoing RALP, in which 40% had 0 pads at 1 month control ($p<0.001$). Moreover, the risk of *de novo* erectile dysfunction was significantly lower after focal HIFU. Indeed, a higher rate of patients in the RALP group presented *de novo*, persistent erectile dysfunction after surgery (44% vs 20%, $p=0.03$). It must be highlighted that patients in the HIFU arm were also older, thus at increased risk of postoperative erectile dysfunction.¹⁵

Specific biochemical outcomes of HIFU hemiablation have been previously published.⁹ When analyzing oncologic outcomes, we did not observe a significant difference in terms of salvage therapy free survival across the two groups (Fig. 1). In fact, 7/55 patients in the HIFU arm vs 6/55 patients in the RALP arm required salvage external beam radiation therapy, androgen deprivation therapy, or both during follow-up ($p=0.76$), with a nonsignificant difference in time to salvage therapy (Table 3). In the HIFU arm, 2/7 patients had ipsilateral recurrence and 5/7 had bilateral disease: in particular, two patients presented Gleason 6 (3+3) recurrence, two patients had Gleason 7 (3+4), two had Gleason 7 (4+3), and one had a Gleason 8 (4+4) recurrence. Nonetheless, 7 (13%) more patients in the HIFU arm required a complementary HIFU treatment on the contralateral lobe during follow-up, after developing a contralateral PCa. No patient died of PCa on follow-up, while 6 men died of other causes (5 HIFU vs 1 RALP, $p=0.11$).

Discussion

Urology is a dynamic surgical specialty, with revolutionary changes which are constantly occurring. Focal therapy for PCa, which is still considered experimental,¹⁶ is a promising approach for localized PCa, as new genetic and clinical data are suggesting that the outcome of the disease is mainly driven by the index lesion.⁶ The focalized treatment of the index lesion could therefore obtain similar oncologic outcomes to whole gland therapy, although reducing morbidity, particularly concerning continence and sexual potency.¹⁷

In this retrospective matched-pair analysis, we compared functional and oncologic results of two diametrically different approaches to unilateral PCa. On the one hand, we offered radical treatment using RALP: indeed these patients had worse functional outcomes, with a slower recuperation of continence and a worse recovery of sexual function. On the other hand, patient undergoing focal therapy achieved better functional results, and this is not surprising given the inherent tissue

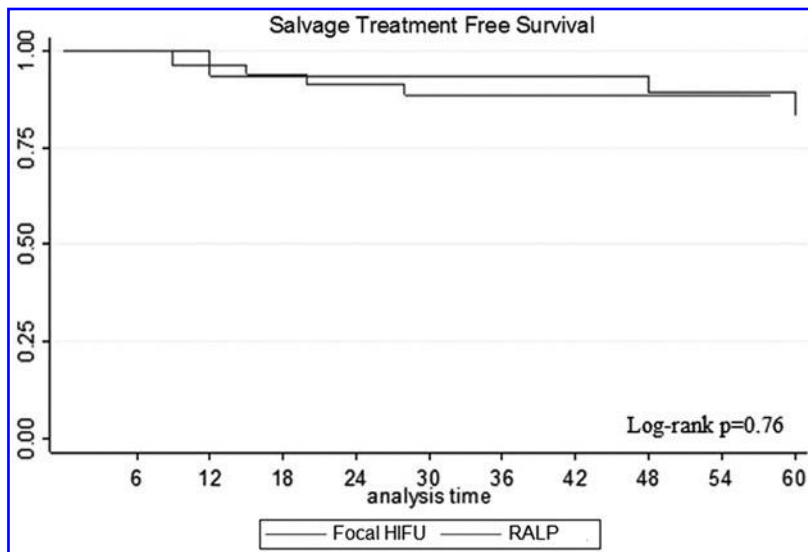


FIG. 1. Exploring salvage treatment free survival across the two techniques for unilateral prostate cancer. HIFU=high-intensity focal ultrasound; RALP=robot-assisted laparoscopic prostatectomy.

sparing approach of focal therapy. Of note, median age in the focal therapy arm was 73 years, and it is known that age is the most important risk factor for urinary incontinence following radical treatment of PCa.^{18,19} As such, an 82% full continence rate at 1 month after surgery, in such an “old” group of men, is not only better than our RALP results but also is indeed appealing especially for older men in whom surgery may determine major aggravation of continence status.^{18,19} A similar consideration can be made for our potency results: clearly, a tissue sparing approach determined a much lower negative impact of erectile function, especially in older men with a baseline worse erectile function.^{18,20} Concerning postoperative complications, these are low across both techniques and are mainly represented by the need of prolonged urinary drainage or urinary tract infections, both classified as minor complications.²¹

All the other comparing oncologic outcomes of a radical vs focal therapy can be tricky. Indeed, in a tissue sparing procedure as HIFU hemiablation, healthy prostatic glands (which physiologically produce PSA) are by definition left behind. As such, the definition of biochemical recurrence is still a matter of debate across experts in the field and no consensus exists.⁵ Frequently, researchers have used the Phoenix criteria used after radiotherapy for PCa¹³: yet, these

criteria are suboptimal in focal therapy. In our center, we use Phoenix criteria to prompt diagnostic work-up, including multiparametric MRI and prostate biopsies. In the RALP group, BCR was experienced by 6/55 patients (11%), as similar to other low and intermediate risk series.^{16,22,23} Similarly, 7/55 patients in the HIFU arm required salvage treatment as a consequence of the failure of HIFU hemi-ablation to control PCa. Thus, it appears that the oncologic control of the index lesion determined by HIFU hemiablation was similar to that obtained by RALP, when considering treatment failure (i.e., the need for salvage radio or hormone therapy). These results are encouraging, although they must be handled with care. A great difference across the two arms of our study is that in the RALP group, unilateral disease is determined on whole-mount pathologic examination, while in the HIFU such “unilateral status” is defined by MRI and targeted biopsies. As such, while in the RALP group we are sure that all patients truly harbored only unilateral disease, in the HIFU groups there might have been patients with bilateral disease, erroneously found to have unilateral PCa, contributing to the number of men who failed treatment and required salvage therapy. Clearly, adequate patient selection and perfect preoperative diagnosis are vital when performing focal therapy. As such, it may be possible that part of the disease progressions observed in the HIFU arm (requiring salvage treatment) is due to inaccurate diagnosis, rather than treatment failure.

When leaving a prostatic lobe untreated, patients remain at risk of developing contralateral PCa.⁵ This is an inherent aspect of focal therapy, which is normally discussed with the patient before surgery. In fact, it can be considered that active surveillance and focal therapy are two complementary strategies of the same therapeutic pathway.²⁴ Moreover, PCa can be already present in the contralateral untreated lobe as a consequence of a missed diagnosis on biopsy. In our center, where mp-MRI is incorporated to MRI-guided fusion targeted biopsies,¹⁰ this is especially true in the case of OMS 2016 Grade I PCa (Gleason 6), which can be underdiagnosed on multiparametric MRI.²⁵ In the current study, 7/55 (13%) extra patients required secondary HIFU hemiablation of the

TABLE 3. ONCOLOGIC OUTCOMES

	<i>Focal HIFU</i>	<i>RALP</i>	<i>p^a</i>
Salvage therapy	7/55	6/55	0.76
Treatment description			0.76
EBRT	1	3	
EBRT + ADT	2	3	
ADT	3	0	
Salvage prostatectomy	1	0	
Time to salvage (months)	23 (12–61)	34 (15–50)	0.81

^aχ²-test.

ADT= androgen deprivation therapy; EBRT= external beam radiation therapy.

contralateral lobe, due to the development of contralateral PCa, which is generally considered acceptable by experts of focal therapy.⁵ These patients may be considered a failure of our approach and must be kept in mind when counseling men on PCa treatment. Although the consequences of contralateral recurrence are usually minor compared to salvage therapy, its exclusion from failures in the current study may have induced a bias with undue advantage for HIFU hemiablation over RALP and as such represents a limitation of the study.

Our study is not devoid of limitations. First, comparing focal therapy to radical surgery may seem like comparing apples and pears; our results must be interpreted with caution. Moreover, the follow-up is limited and insufficient to draw definite conclusions on oncologic control obtained by our focal therapy. Finally, the study is retrospective in nature, and the number of patients is limited.

Conclusions

In this retrospective matched-pair analysis, HIFU hemiablation of the prostate was comparable to RALP in controlling localized unilateral PCa, with no significant differences in the need for salvage therapies. However, patients undergoing focal treatment of PCa remain at risk of contralateral PCa, which required a contralateral hemiablation in 7/55 (13%) of our patients. HIFU hemiablation of the prostate was also associated to significantly better urinary continence and erectile potency recovery. Accurate patient selection remains vital, and larger prospective trials are needed to confirm our findings.

Author Disclosure Statement

No competing financial interests exist.

References

- Center MM, Jemal A, Lortet-Tieulent J, Ward E, Ferlay J, Brawley O, et al. International variation in prostate cancer incidence and mortality rates. *Eur Urol* 2012;61:1079–1092.
- Wagner AA, Cheng PJ, Carneiro A, Dvirak O, Khosla A, Taylor KN, et al. Clinical use of EPIC for clinical practice (EPIC-CP) to assess patient-reported prostate cancer quality-of-life following robot-assisted radical prostatectomy. *J Urol* 2016 [Epub ahead of print]; DOI: 10.1016/j.juro.2016.07.080.
- Passoni NM, Polascik TJ. How to select the right patients for focal therapy of prostate cancer? *Curr Opin Urol* 2014; 24:203–208.
- Valerio M, Ahmed HU, Emberton M, Lawrentschuk N, Lazzeri M, Montironi R, et al. The role of focal therapy in the management of localised prostate cancer: A systematic review. *Eur Urol* 2014;66:732–751.
- Donaldson IA, Alonzi R, Barratt D, Barret E, Berge V, Bott S, et al. Focal therapy: patients, interventions, and outcomes—A report from a consensus meeting. *Eur Urol* 2015;67:771–777.
- Liu W, Laitinen S, Khan S, Vihinen M, Kowalski J, Yu G, et al. Copy number analysis indicates monoclonal origin of lethal metastatic prostate cancer. *Nat Med* 2009;15:559–565.
- Perez-Reggeti JI, Sanchez-Salas R, Sivaraman A, Linares Espinos E, de Gracia-Nieto AE, Barret E, et al. High intensity focused ultrasound with Focal-One® device: Prostate-specific antigen impact and morbidity evaluation during the initial experience. *Actas Urol Esp* 2016 [Epub ahead of print]; DOI: 10.1016/j.acuro.2016.04.016.
- Shah TT, Kasivisvanathan V, Jameson C, Freeman A, Emberton M, Ahmed HU. Histological outcomes after focal high-intensity focused ultrasound and cryotherapy. *World J Urol* 2015;33:955–964.
- van Velthoven R, Aoun F, Marcelis Q, Albisinni S, Zanaty M, Lemort M, et al. A prospective clinical trial of HIFU hemiablation for clinically localized prostate cancer. *Prostate Cancer Prostatic Dis* 2016;19:79–83.
- Peltier A, Aoun F, Albisinni S, Marcelis Q, Ledinh D, Paesmans M, et al. Results of a comparative analysis of magnetic resonance imaging-targeted versus three-dimensional transrectal ultrasound prostate biopsies: Size does matter. *Scand J Urol* 2016;50:144–148.
- Dickinson L, Arya M, Afzal N, Cathcart P, Charman SC, Cornaby A, et al. Medium-term outcomes after whole-gland high-intensity focused ultrasound for the treatment of non-metastatic prostate cancer from a Multicentre Registry Cohort. *Eur Urol* 2016 [Epub ahead of print]; DOI: 10.1016/j.eururo.2016.02.054.
- Warmuth M, Johansson T, Mad P. Systematic review of the efficacy and safety of high-intensity focussed ultrasound for the primary and salvage treatment of prostate cancer. *Eur Urol* 2010;58:803–815.
- Roach M, Hanks G, Thames H, Schellhammer P, Shipley WU, Sokol GH, et al. Defining biochemical failure following radiotherapy with or without hormonal therapy in men with clinically localized prostate cancer: Recommendations of the RTOG-ASTRO Phoenix Consensus Conference. *Int J Radiat Oncol* 2006;65:965–974.
- Cookson MS, Aus G, Burnett AL, Canby-Hagino ED, D'Amico AV, Dmochowski RR, et al. Variation in the definition of biochemical recurrence in patients treated for localized prostate cancer: The American Urological Association Prostate Guidelines for Localized Prostate Cancer Update Panel report and recommendations for a standard in the reporting of surgical outcomes. *J Urol* 2007;177: 540–545.
- Kumar A, Samavedi S, Bates AS, Giedelman Cuevas CA, Coelho RF, Rocco B, et al. Age stratified comparative analysis of perioperative, functional and oncologic outcomes in patients after robot assisted radical prostatectomy—A propensity score matched study. *Eur J Surg Oncol J Eur Soc Surg Oncol Br Assoc Surg Oncol* 2015;41: 837–843.
- Heidenreich A, Bastian PJ, Bellmunt J, Bolla M, Joniau S, van der Kwast T, et al. EAU guidelines on prostate cancer. part 1: Screening, diagnosis, and local treatment with curative intent-update 2013. *Eur Urol* 2014;65: 124–137.
- Mendez MH, Joh DY, Gupta R, Polascik TJ. Current trends and new frontiers in focal therapy for localized prostate cancer. *Curr Urol Rep* 2015;16:35.
- Mandel P, Graefen M, Michl U, Huland H, Tilki D. The effect of age on functional outcomes after radical prostatectomy. *Urol Oncol* 2015;33:203.e11–e18.
- Magheli A, Rais-Bahrami S, Humphreys EB, Peck HJ, Trock BJ, Gonzalgo ML. Impact of patient age on biochemical recurrence rates following radical prostatectomy. *J Urol* 2007;178:1933–1937; discussion 1937–1938.

20. Catalona WJ, Carvalhal GF, Mager DE, Smith DS. Potency, continence and complication rates in 1,870 consecutive radical retropubic prostatectomies. *J Urol* 1999;162:433–438.
21. Dindo D, Demartines N, Clavien P-A. Classification of surgical complications: A new proposal with evaluation in a cohort of 6336 patients and results of a survey. *Ann Surg* 2004;240:205–213.
22. Budäus L, Isbarn H, Eichelberg C, Lughezzani G, Sun M, Perrotte P, et al. Biochemical recurrence after radical prostatectomy: Multiplicative interaction between surgical margin status and pathological stage. *J Urol* 2010;184:1341–1346.
23. Tanimoto R, Fashola Y, Scotland KB, Calvaresi AE, Gomella LG, Trabulsi EJ, et al. Risk factors for biochemical recurrence after robotic assisted radical prostatectomy: A single surgeon experience. *BMC Urol* 2015;15:27.
24. Klotz L, Polascik TJ. Low-risk and very-low-risk prostate cancer: Is there a role for focal therapy in the era of active surveillance? Yes, the two approaches complement each other. *Oncology (Williston Park)* 2014;28:950–C3.
25. De Visschere P, Briganti A, Fütterer JJ, Ghadjar P, Isbarn H, Massard C, et al. Role of multiparametric magnetic resonance imaging in early detection of prostate cancer. *Insights Imaging* 2016;7:205–214.

Address correspondence to:
Simone Albinini, MD
Department of Urology
Jules Bordet Institute
Université Libre de Bruxelles
Boulevard de Waterloo 121
Brussels 1000
Belgium

E-mail: albinini.simone@gmail.com


Abbreviations Used

ADT = androgen deprivation therapy
EBRT = external beam radiation therapy
HIFU = high-intensity focal ultrasound
IQR = interquartile range
MRI = magnetic resonance imaging
PCa = prostate cancer
PSA = prostate specific antigen
RALP = robot-assisted laparoscopic prostatectomy

available at www.sciencedirect.com
journal homepage: www.europeanurology.com



European Association of Urology



Prostate Cancer

Focal High Intensity Focused Ultrasound of Unilateral Localized Prostate cancer: A Prospective Multicentric Hemiablation Study of 111 Patients

Pascal Rischmann^{a,*}, Albert Gelet^{b,c,d}, Benjamin Riche^{c,e}, Arnauld Villers^f, Gilles Pasticier^g, Pierre Bondil^h, Jean-Luc Jungⁱ, Hubert Bugel^j, Jacques Petit^k, Harry Toledano^l, Stéphane Mallick^m, Olivier Rouvière^{c,d,n}, Muriel Rabilloud^{c,e}, Hélène Tonoli-Catez^b, Sébastien Crouzet^{b,c,d}

^a Department of Urology, Rangueil University Hospital, Toulouse, France; ^b Department of Urology and Transplantation Surgery, Edouard Herriot Hospital, Lyon, France; ^c Department of Urology, Université de Lyon, Lyon, France; ^d INSERM Unit 1032, LabTau, Université de Lyon, Lyon, France; ^e Hospices Civils de Lyon, Service de Biostatistiques, Lyon, France; ^f Department of Urology, Huriez Hospital, Lille University, France; ^g Department of Urology, CHU Pellegrin, Bordeaux, France; ^h Department of Urology, General Hospital of Chambéry, Chambéry, France; ⁱ Department of Urology, Pasteur Hospital, Colmar, France; ^j Department of Urology, University Hospital of Rouen, Rouen, France; ^k Department of Urology and Transplantation, South Hospital of Amiens, Amiens, France; ^l Department of Surgical Urology, North Hospital of Marseille, Marseille, France; ^m Department of Urology, Saint-Michel Clinic, Toulon, France; ⁿ Department of Radiology, Edouard Herriot Hospital, Lyon, France

Article info

Article history:

Accepted September 25, 2016

Associate Editor:

Giacomo Novara

Keywords:

Prostate cancer
Focal therapy
High-intensity focused ultrasound
Hemiablation
Prospective trial

Abstract

Background: Up to a third of patients with localized prostate cancer have unilateral disease that may be suitable for partial treatment with hemiablation.

Objective: To evaluate the ability of high intensity focused ultrasound (HIFU) to achieve local control of the tumor in patients with unilateral localized prostate cancer.

Design, setting, and participants: The French Urological Association initiated a prospective IDEAL multi-institutional study (2009–2015), to evaluate HIFU-hemiablation as a primary treatment.

Intervention: Multiparametric magnetic resonance imaging and biopsy were used for unilateral cancer diagnosis and control, and HIFU-hemiablation.

Outcome measurements and statistical analysis: Primary: absence of clinically significant cancer (CSC) on control biopsy at 1 yr (CSC: Gleason score ≥ 7 or cancer core length > 3 mm regardless of grade or > 2 positive cores). Secondary: presence of any cancer on biopsy, biochemical response, radical treatment free survival, adverse events, continence (no pad), erectile function (International Index of Erectile Function-5 ≥ 16), and quality of life (European Organization for Research and Treatment of Cancer QLQ-C28) questionnaires.

Results and limitations: One hundred and eleven patients were treated (mean age: 64.8 yr [standard deviation 6.2]; mean prostate-specific antigen: 6.2 ng/ml [standard deviation 2.6]; 68% low risk, 32% intermediate risk). Of the 101 patients with control biopsy, 96 (95%) and 94 (93%) had no CSC in the treated and contralateral lobes, respectively. Mean prostate-specific antigen at 2 yr was 2.3 ng/ml (standard deviation 1.7). The radical treatment-free survival rate at 2 years was 89% (radical treatments: six radical prostatectomies, three radiotherapies, and two HIFU). Adverse events were

* Corresponding author. Department of Urology, Centre Hospitalier Universitaire de Rangueil, 1, Avenue Jean Poulhès TSA 50032, Toulouse, 31059 Cedex 9, France. Tel. +33 5 61 32 32 40; Fax: +33 5 61 32 32 30.
E-mail address: rischmann.p@chu-toulouse.fr (P. Rischmann).

<http://dx.doi.org/10.1016/j.eururo.2016.09.039>

0302-2838/© 2016 European Association of Urology. Published by Elsevier B.V. All rights reserved.

Please cite this article in press as: Rischmann P, et al. Focal High Intensity Focused Ultrasound of Unilateral Localized Prostate cancer: A Prospective Multicentric Hemiablation Study of 111 Patients. Eur Urol (2016), <http://dx.doi.org/10.1016/j.eururo.2016.09.039>

Grade 3 in 13%. At 12 mo continence and erectile functions were preserved in 97% and 78%. No significant decrease in quality of life score was observed at 12 mo. One limitation is the number of low-risk patients included in this study.

Conclusions: At 1 yr, HIFU-hemiablation was efficient with 95% absence of clinically significant cancer associated with low morbidity and preservation of quality of life. Radical treatment-free survival rate was 89% at 2 yr.

Patient summary: This report shows that high intensity focused ultrasound half-gland treatment of unilateral prostate cancer provides promising results with high cancer control and low morbidity.

© 2016 European Association of Urology. Published by Elsevier B.V. All rights reserved.

1. Introduction

Treatment of favorable-risk localized prostate cancer remains controversial. Because prostate cancer is multifocal in 40% of men, whole gland therapy is used as standard treatment of localized prostate cancer [1]. However, the Prostate Cancer Intervention versus Observation Trial failed to demonstrate a significant survival advantage for radical surgery compared with the watchful waiting [2]. Active surveillance (AS) has been adopted as an option to decrease the risk of overtreatment in men who have favorable-risk disease and long-term outcomes of large AS series are now available [3]. Focal therapy is emerging as an alternative in the management of selected patients [4]. The aim is to achieve a good long-term control of the cancer with a minimal morbidity and to minimize the risk of subsequent radical therapy. Approximately 20% of men who are candidates for radical surgery have unilateral cancers and could be amenable for hemiablation [5]. The fundamental challenge is to accurately assess the spatial distribution of cancer within the gland [6]. High intensity focused ultrasound (HIFU) might be one of the best techniques for focal therapy because it is performed under real-time control. It can also be repeated while standard curative therapies (external beam radiotherapy [EBRT] and radical surgery) remain viable options if necessary. The French Association of Urology conducted a multi-institutional study to evaluate HIFU-hemiablation as a primary treatment for unilateral prostate cancer. The primary objective was the local control of the tumor.

2. Patients and methods

This prospective Stage 2b early dispersion and exploration IDEAL paradigm [7] study was conducted in 10 centers in France and was nationally approved by the Lyon Sud-Est III Ethics Committee (registration: 2009-034B) under EudraCT 2009-A00664-53 (Lyon, France). All participants provided written informed consent.

Treatment-naïve patients with T1/T2 clinical stage were considered for inclusion. Before inclusion, all patients underwent multiparametric magnetic resonance imaging (mpMRI) including T2-weighted, diffusion-weighted, and dynamic contrast-enhanced imaging at 1.5T or 3T. Focal lesions were scored using the Likert 5-level suspicion score from 1 (definitely benign) to 5 (definitely malignant) [8]. Diagnostic biopsies were random (≥ 12 cores) and targeted on any mpMRI lesions with a suspicion score ≥ 3 (at least two cores per lesion). All suspicious MRI targets on the contralateral side were rebiopsied before inclusion. Only patients showing unilateral cancer (≤ 2 adjacent sextants) with a

Gleason score ≤ 7 (3 + 4) were included. Patients with a biopsy confirmed mpMRI lesion located <6 mm from the apex or <5 mm from the sagittal midline were excluded.

transurethral resection of the prostate (TURP) were performed to either reduce the prostate volume (for those with a prostate > 50 cc) or for those with pretreatment obstructive symptoms. TURP was performed either >2 mo prior to HIFU or combined with the HIFU procedure under the same anesthesia.

Hemiablation was performed with the Ablatherm Integrated Imaging medical device (EDAP TMS France, Vaulx-en-Velin, France) under spinal or general anesthesia in patients in the right lateral decubitus position. The hemiablation treatment was performed with a 4-mm safety prostate tissue margin (untreated zone) at the apex in order to optimize sphincter preservation. The midline was defined by the urethra or Foley catheter position. Ipsilateral nerve sparing was not attempted.

Patients were seen at 3 mo, 6 mo, 12 mo, and every 6 mo. Follow-up mpMRI with subsequent 12-core random biopsies and targeted biopsies to any suspicious lesion at MRI were scheduled 6–12 mo after treatment.

The primary outcome was the absence of clinically significant cancer (CSC) defined as cancer with a Gleason score ≥ 7 or cancer core length >3 mm regardless of grade or >2 positive cores.

Secondary outcomes were the presence of any cancer on biopsy, biochemical (PSA variations) response, and radical treatment-free survival rate. All adverse events were collected and Clavien classified. Additionally, urinary function was evaluated using the International Prostate Symptom Score (IPSS). Incontinence was defined by the need of pads. Erectile dysfunction was defined as an International Index of Erectile Function (IIEF-5) score <16 [9]. Health-related quality of life was measured using the third version of the European Organization for Research and Treatment of Cancer Quality of Life Questionnaire (EORTC QLQ-C28).

The description of patients' characteristics was carried out using the relative and absolute frequencies for the qualitative characteristics, and the mean and standard deviation (SD) for the quantitative ones. The duration of follow-up and time to reach the PSA nadir were described using the median, minimum, and maximum values.

The probability of positive control biopsy was estimated with its 95% confidence interval (CI), built using the normal approximation of the binomial distribution. The probability of radical treatment-free survival at 24 mo was estimated using the Kaplan-Meier method. The evolutions of the different scores (ie, the IPSS score, the IIEF-5 score, and the EORTC QLQ-C28 score) between inclusion and 12 mo were described by the median, minimum, and maximum values. The evolutions were tested using the Wilcoxon test. All the analysis was carried out using the SAS software, version 9.3 (SAS Institute Inc., Cary, NC, USA).

3. Results

Between November 2009 and August 2014, 111 patients were included at 10 centers. Demographics and preoperative data are presented in Table 1.

Table 1 – Pre-high intensity focused ultrasound (HIFU) characteristics

	HIFU (N = 111)
Mean age, yr (median) [Q1–Q3] ^a	64.8 ± 6.2 (64.9) [61–69]
Mean prostate volume at diagnostic, cc (median) [Q1–Q3]	44.2 ± 22.2 (40.0) [28–55]
Mean prostate volume before HIFU, cc (median) [Q1–Q3]	31.6 ± 12.3 (28.3) [23–39]
Mean PSA, ng/ml (median) [Q1–Q3]	6.2 ± 2.5 (5.6) [4.7–7.6]
Clinical stage, n (%)	
T1	77 (69)
T2	33 (30)
Unknown	1 (1)
No. of diagnostic biopsies sessions before treatment, n (%)	
Unknown	1
=1	45 (41)
=2	30 (27)
≥3	35 (32)
Side of positive biopsies, n (%)	
Right	55 (49)
Left	56 (51)
Mean no. of biopsy samples analyzed, (median) [Q1–Q3]	20.6 ± 8.9 (18.0) [12–28]
Positive samples, n (%)	
=1	45 (41)
≥2	66 (59)
Sextant affected, n (%)	
1 sextant	75 (68)
2 sextants (base + med, med + apex)	36 (32)
Gleason score, n (%)	
≤6	82 (74)
=7	29 (26)

^a Eight-one percent of patients had a life expectancy over 10 yr, 19% had a life expectancy between 5 yr and 10 yr. PSA = prostate-specific antigen.

Of the 111 patients, 43 (39%) had Prostate Cancer Research International Active Surveillance (PRIAS) criteria; out of them 33 had mpMRI target. Two patients did not undergo mpMRI because of a pacemaker ($n = 1$) or a hip prosthesis ($n = 1$).

TURP was performed prior to treatment in 26 patients who had a mean prostate volume of 69.9 cc (SD 23.3). Additionally, 41 patients had concomitant TURP. The mean treated volume was 16.1 cc (SD 5.1), representing 51% of the pre-HIFU prostate volume.

No patient was lost to follow-up. Control biopsy was performed in 101 patients. The 10 missing biopsies were due to patient refusal, contraindication, or death from other cause. Results are summarized in Table 2. One patient who presented with a T2 disease had only seven samples because of anticoagulation treatment.

Of the 101 patients, 12 (12%; 95% CI: 6–18) had CSC (five ipsilateral and seven contralateral). Twenty-one patients (21%; 95% CI: 13–29) had a non-CSC (seven ipsilateral, 12 contralateral, and two bilateral).

Absence of any cancer in the treated lobe was 86% (95% CI: 79–93; 87/101). Absence of any cancer in the whole gland was 67% (95% CI: 58–77; 68/101).

Positive biopsies in the treated lobe were situated at the apex in eight of 12 patients (67%) of which five (63%) were CSC.

Table 2 – Follow-up biopsy results

	HIFU (N = 101)
Mean no. of cores ± SD, (median) [Q1–Q3]	12.4 ± 3.3 (12) [12–14]
Biopsy findings, n (%)	
(–) Negative	68 (67)
(+) Untreated lobe	19 (19)
(+) Treated lobe	12 (12)
(+) Bilateral	2 (2)
Mean size of cancer core length ± SD (median) [Q1–Q3] (N = 33)	2.5 ± 2.0 (2.0) [1–4]
Gleason score, n (%)	
≤6	26 (79)
=7	4 (12)
ND (foci < 1 mm)	3 (9)
Sextant affected, n (%) (N = 33)	
1 sextant	22 (67)
2 sextants (base + med, med + apex)	9 (27)
3 sextants (base + med + apex)	2 (6)
Localization, n (%) (N = 33)	
Apex	9 (27)
Apex + base + TZ	1 (3)
Apex + middle	6 (18)
Apex + base + middle	1 (3)
Base	5 (15)
Base + middle	3 (9)
Middle	8 (24)
Clinically significant cancer, n (%)	
Treated lobe	5 (5)
Untreated lobe	7 (7)

HIFU = high intensity focused ultrasound; ND = not determined; SD = standard deviation; TZ = transition zone.

The mean follow-up was 30.4 mo (SD 14.1), with 71% followed-up longer than 24 mo. Mean PSA nadir was 1.9 ng/ml (SD 1.5), median time to nadir was 5.7 mo (Q1–Q3: 2.8–9.9). Mean PSA at 6 mo, 12 mo, and 24 mo were 2.3 (SD 1.7) ng/ml, 2.5 (SD 2.1) ng/ml, and 2.3 (SD 1.7) ng/ml, respectively. At 2 yr, the mean PSA level decrease was 63% compared with baseline.

Second line treatments were 16 AS, six radical prostatectomies, three EBRT, nine second HIFU treatments (seven focal HIFU and two radical HIFU [with one due to rising PSA without control biopsy]). Four patients had a third line treatment (two EBRT, one radical prostatectomy, and one androgen deprivation therapy; Fig. 1). The radical treatment-free survival rate at 2 yr was 89% (95% CI: 81–94; Fig. 2).

Robotic radical prostatectomies were performed with unilateral preservation of neurovascular bundles. Gleason score was 6 in one patient and 7 in six patients (3 + 4 $n = 4$; 4 + 3 $n = 2$). The pathological stage was pT2 in four patients and pT3a in three patients. Positive margins were observed in three patients. The mean postoperative PSA nadir was 0.06 ng/ml.

Patients treated with EBRT received a mean dose of 75.6 Gy. The mean nadir PSA was 0.24 ng/ml.

Eighty patients completed the IPSS questionnaire at both inclusion and 12 mo follow-up showing an improvement with a mean decrease of 3 (95% CI: 1.6; 4.4; Fig. 3A).

Continence was evaluated for 102 patients at both baseline and 12 mo. At 1 yr, the proportion of pad-free patients was 97% compared with 99% at inclusion. These three (3%) had Grade I stress incontinence.

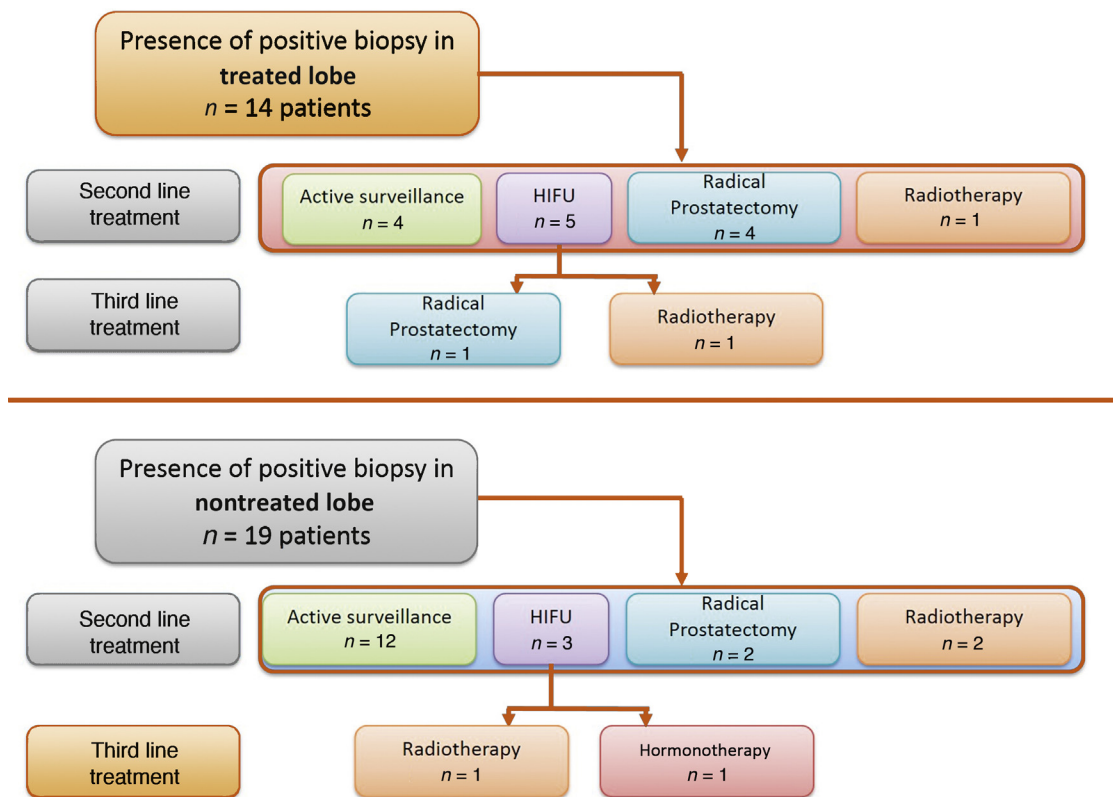


Fig. 1 – Additional treatments.
HIFU = high intensity focused ultrasound.

At baseline, 51 patients had good erectile function (IIEF-5 ≥ 16) and 40 (78%) returned to this status at 12 mo. The mean difference of IIEF-5 score from baseline to 12 mo was 1.2 (95% CI: -0.4; 2.7; Fig. 3B).

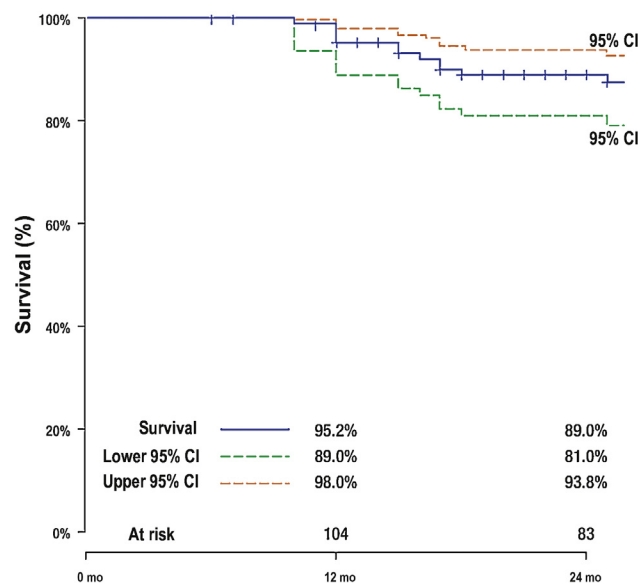


Fig. 2 – Radical treatment-free survival rate curve.
CI = confidence interval.

Seventy-six patients completed both inclusion and 12 mo EORTC QLQ-C28 questionnaire. The mean increase from baseline to 12 mo was 0.4 (95% CI: -1.0; 1.7; Fig. 3C).

Fourteen patients underwent Clavien Grade III adverse events: 11 Grade IIIa and three Grade IIIb (chronic urine retention leading to TURP). Complications are detailed in Table 3. Two patients died from other causes: pancreatic and ethmoidal bone cancers.

4. Discussion

Whole-gland HIFU for localized prostate cancer started in the early 1990s and several centers have reported long-term results [10-12]. The 10-yr cancer specific and metastasis free survivals ranged from 94% to 97% and 94% to 95%, respectively [9,10]. Literature evidence of focal HIFU is limited due to the recent development of this concept. Donaldson et al [13] defined, in a 2014 consensus meeting, several metrics for the evaluation of focal therapies. Of note, acceptable cancer control after focal therapy was defined as a retreatment rate <20%, and a whole-gland salvage treatment rate $\leq 10\%$ which is in line with our 8.1% and 10.8% rates, respectively. Focal or multifocal nonwhole-gland HIFU was considered as feasible, but safety and effectiveness were to be improved [14,15].

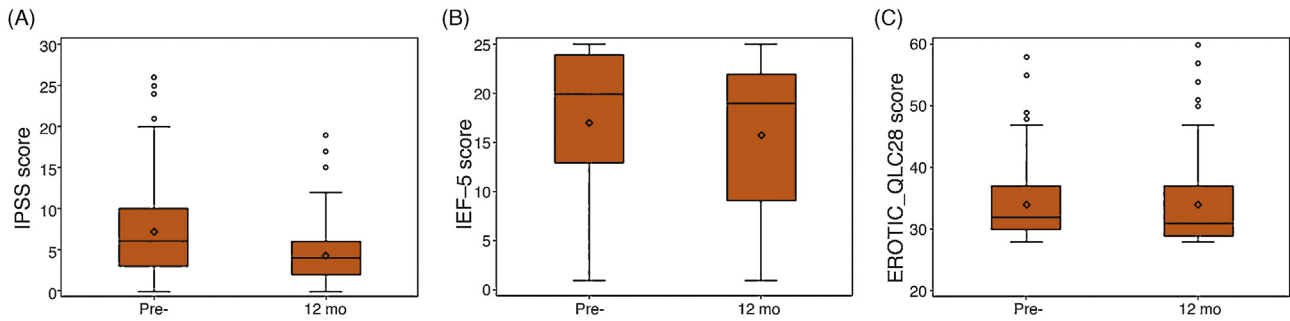


Fig. 3 – Functional results over a 12-mo follow-up period. (A) Evaluation of lower urinary tract symptoms (International Prostate Symptom score [IPSS]). (B) Evaluation of erectile function (International Index of Erectile Function [IIEF-5] score). (C) Evaluation of general quality of life (European Organization for Research and Treatment of Cancer Quality of Life Questionnaire [EORTC QLQ-C28] score).

Hemiablation is different from the index tumor ablation or multifocal approach used by the Ahmed et al [16–18]. The main advantage of hemiablation is to minimize the problem of safety margin to apply around the MRI target and to be a more reproducible and standardizable strategy.

Our CSC definition is consistent with the 2014 consensus meeting [13]. In our series 88.1% of patients had histological absence of CSC after treatment, which exceeds the 80.8% absence of CSC after index lesion treatment published by Ahmed et al [18] and is in line with the 92% absence of CSC of the multifocal study [17]. In the treated side, 5% of our patients still have CSC. This rate might be due to the apical safety margin defined in the treatment protocol (100% of positive ipsilateral control biopsies are localized at the apex). The Ablatherm HIFU technical limitations (penetration depth of 26 mm) may explain some residual disease at the anterior part.

The 6.9% rate of CSC in the untreated lobe is in concordance with the 5% negative predictive value of mpMRI and biopsies [19]. While our patients’ recruitment started in 2009 we should expect that the recent improvements of both MR-imaging and HIFU technology may

overcome these limitations and provide even better results. Of note, the apical and anterior technical limitations are no longer an issue with the Focal One HIFU device (EDAP TMS France, Vaulx-en-Velin, France). This new device also allows for peri-procedure evaluation of the treatment effect with contrast-enhanced ultrasound allowing live adjustment of the treatment.

A strength of our study is the combination of the longest follow-up in literature with more than 90% control biopsy compliance. Our 86.1% negative biopsy rate in the treated lobe is similar to other recently published HIFU studies: 65.4% in the Ahmed et al [18] study and 83.6% in the Feijoo et al [20] study. Van Velthoven et al [21] reported the outcomes of 50 hemi-HIFU patients but follow-up biopsies were not performed in patients with stable PSA.

In our study, 11 patients received a salvage radical treatment (six radical prostatectomy, three EBRT, and two HIFU) which were uneventful with no observed increase in complexity or morbidity. This underscores the fact that HIFU-hemiablation strategy does not burn bridges for further curative treatments.

Functional outcomes: the 97.2% rate of pad-free continent patients in our study is consistent with outcomes reported in literature (90%, 100%, 92.3%, and 94%) [16–18,20,21]. The preservation of potency was obtained in 52.3%, 76.9%, and 80% in previous published studies and 78.4% in our study [18,20,21] and preservation of erection sufficient for penetration was 100% in the Ahmed et al [17] multifocal study. These functional outcomes likely contributed to the observed quality of life preservation with no statistical difference between baseline and follow-up evaluation. The rate of Grade IIIb complications of 2.7% in our study was similar to the 2.8% observed by Feijoo et al [20] using the Ablatherm device and not dissimilar from the 7.2% observed by Ahmed et al [18] using the Sonablate device.

Some limitations should be discussed. The 30.4 mo follow-up of our series could be considered as too short, but is actually the longest follow-up in literature of focal treatment studies with systematic control biopsy. However, assuming that patients are properly followed on a long-term basis, we have shown that further treatments were feasible without additional morbidity. Furthermore, definitive oncological results should need more than 10 yr to be

Table 3 – High intensity focused ultrasound-related or possibly related adverse events (105 patients having completed the 12-mo follow-up visit)

Clavien grading system score			N
III	IIIa	Transient acute urine retention	5
		Urinary meatus stricture	1
		Gross hematuria	5
	IIIb	Chronic urine retention or poor urinary flow	3
		Deep phlebitis	1
II	Superficial phlebitis	1	
	Urinary tract infection	18	
	Orchitis	8	
	Prostatitis	8	
	I	Transient urge incontinence	4
I	Transient dysuria	17	
	Tissue sloughing/lower urinary tract symptoms	7	
	Hemospermia	2	
	Anejaculation	16	
	Transient anal and perineal pain	10	

validated which is far too long for new treatment modality evaluation. Out of our baseline population, 10 patients fulfilled the PRIAS criteria and did not have MRI target thus might not have been treated initially [22]. However, all had refused AS and were candidates for conservative treatment.

Hemiablation is one of the options for partial prostate gland treatment. Although no consensus has been reached on candidate selection or on treatment modality, the use of focal therapy has been proposed as ideal for patients with low-risk features and visible lesions at mpMRI and/or significant cancer at biopsy (cancer core length > 3 mm and/or Gleason score 3 + 4) [13].

Partial gland treatment could be considered as an intermediate option between AS and radical treatments. Long-term outcomes of large AS series of men with favorable-risk prostate cancer are available [3]. Our rate of 10.8% radical treatments at 2 yr is better than the 16% and 24% rates of conversion to radical treatment described in the Klotz et al [23] study and PRIAS series [22]. Beside these oncological outcomes, one should not underestimate the psychological burden associated with AS-delay therapy versus the value of an immediate and effective therapy in 89% of the patients.

AS and partial gland therapy should be viewed as complementary options. Among patients unfit for AS, those with unilateral localized Gleason 7 tumor could potentially benefit from tissue-preserving treatment. The best candidates for AS are patients without any mpMRI target; conversely, patients with suspicious mpMRI findings (lesion > 10 mm and Prostate Imaging Reporting and Data System [PI-RADS] 4–5) with positive targeted biopsies might be good candidates for partial gland therapy [24]. Nevertheless PI-RADS was challenged [25] and revised PI-RADS provides moderately reproducible MR-imaging scores for the detection of clinically relevant disease [26]. Further research should determine whether the presence of a lesion on mpMRI is predictive of progression in AS patients and therefore justify a more aggressive—but not radical—approach.

5. Conclusions

HIFU-hemiablation of unilateral localized prostate cancer provides promising local control with 95% absence of clinically significant cancer at 1 yr. The morbidity was low with preservation of the quality of life. Radical treatment-free survival rate was 89% at 2 yr. The efficacy of HIFU partial prostate gland therapy should be evidenced by comparative studies conducted versus standards of care.

Author contributions: Pascal Rischmann had full access to all the data in the study and takes responsibility for the integrity of the data and the accuracy of the data analysis.

Study concept and design: Rischmann, Gelet, Villers, Pasticier.

Acquisition of data: Rischmann, Gelet, Villers, Pasticier, Bondil, Jung, Bugel, Petit, Toledano, Mallick, Rouvière, Tonoli-Catez, Crouzet.

Analysis and interpretation of data: Rischmann, Crouzet, Gelet, Rouvière.

Drafting of the manuscript: Rischmann, Crouzet, Gelet.

Critical revision of the manuscript for important intellectual content: Villers, Rouvière.

Statistical analysis: Riche, Rabilloud, Gelet, Tonoli-Catez.

Obtaining funding: Rischmann.

Administrative, technical, or material support: None.

Supervision: Rischmann, Gelet.

Other: None.

Financial disclosures: Pascal Rischmann certifies that all conflicts of interest, including specific financial interests and relationships and affiliations relevant to the subject matter or materials discussed in the manuscript (eg, employment/affiliation, grants or funding, consultancies, honoraria, stock ownership or options, expert testimony, royalties, or patents filed, received, or pending), are the following: Rischmann is a consultant for EDAP-TMS, Vaulx-en-Velin, France, and stock owner of EDAP TMS shares; Gelet is a consultant for EDAP-TMS, Vaulx-en-Velin, France; Crouzet is a consultant for EDAP-TMS, Vaulx-en-Velin, France; Pasticier is a consultant for EDAP-TMS, Vaulx-en-Velin, France; Toledano is a consultant for EDAP-TMS, Vaulx-en-Velin, France; Mallick is a consultant for EDAP-TMS, Vaulx-en-Velin, France.

Funding/Support and role of the sponsor: None.

Acknowledgments: Grant from the Association Française d'Urologie.

Appendix A. Supplementary data

Supplementary data associated with this article can be found, in the online version, at <http://dx.doi.org/10.1016/j.eururo.2016.09.039>.

References

- [1] Nevoux P, Ouzzane A, Ahmed HU, et al. Quantitative tissue analyses of prostate cancer foci in an unselected cystoprostatectomy series. *BJU Int* 2012;110:517–23.
- [2] Wilt TJ, Brawer MK, Jones KM, et al. Radical prostatectomy versus observation for localized prostate cancer. *N Engl J Med* 2012;367:203–13.
- [3] Klotz L, Vesprini D, Sethukavalan P, et al. Long-term follow-up of a large active surveillance cohort of patients with prostate cancer. *J Clin Oncol* 2015;33:272–7.
- [4] Onik G, Narayan P, Vaughan D, Dineen M, Brunelle R. Focal “nerve-sparing” cryosurgery for treatment of primary prostate cancer: a new approach to preserving potency. *Urology* 2002;60:109–14.
- [5] Mouraviev V, Mayes JM, Sun L, et al. Prostate cancer laterality as a rationale of focal ablative therapy for the treatment of clinically localized prostate cancer. *Cancer* 2007;110:906–10.
- [6] Rouvière O, Gelet A, Crouzet S, Chapelon JY. Prostate focused ultrasound focal therapy—imaging for the future. *Nat Rev* 2012;9:721–7.
- [7] Barkun JS, Aronson JK, Feldman LS, et al. Evaluation and stages of surgical innovations. *Lancet* 2009;374:1089–96.
- [8] Portalez D, Mozer P, Cornud F, et al. Validation of the European Society of Urogenital Radiology Scoring System for prostate cancer diagnosis on multiparametric magnetic resonance imaging in a cohort of repeat biopsy patients. *Eur Urol* 2012;62:986–96.
- [9] Rosen RC1, Cappelleri JC, Smith MD, Lipsky J, Peña BM. Development and evaluation of an abridged, 5-item version of the International Index of Erectile Function (IIEF-5) as a diagnostic tool for erectile dysfunction. *Int J Impot Res* 1999;11:319–26.
- [10] Ganzer R, Fritsche HM, Brandtner A, et al. Fourteen-year oncological and functional outcomes of high-intensity focused ultrasound in localized prostate cancer. *BJU Int* 2013;112:322–9.
- [11] Thüroff S, Chaussy C. Evolution and outcomes of 3 MHz high intensity focused ultrasound therapy for localized prostate cancer during 15 years. *J Urol* 2013;190:702–10.

- [12] Crouzet S, Chapelon JY, Rouvière O, et al. Whole-gland ablation of localized prostate cancer with high-intensity focused ultrasound: oncologic outcomes and morbidity in 1002 patients. *Eur Urol* 2014;65:907–14.
- [13] Donaldson IA, Alonzi R, Barratt D, et al. Focal therapy: patients, interventions, and outcomes—a report from a consensus meeting. *Eur Urol* 2015;67:771–7.
- [14] Lazzeri M, Guazzoni G, Montorsi F. Focal HIFU for prostate cancer. *Lancet Oncol* 2012;13:e281–2.
- [15] Valerio M, Ahmed HU, Emberton M, et al. The role of focal therapy in the management of localised prostate cancer: a systematic review. *Eur Urol* 2014;66:732–51.
- [16] Ahmed HU, Freeman A, Kirkham A, et al. Focal therapy for localized prostate cancer: a phase I/II trial. *J Urol* 2011;185:1246–54.
- [17] Ahmed HU, Hindley RG, Dickinson L, et al. Focal therapy for localized unifocal and multifocal prostate cancer: a prospective development study. *Lancet Oncol* 2012;13:622–32.
- [18] Ahmed HU, Dickinson L, Charman S, et al. Focal ablation targeted to the index lesion in multifocal localized prostate cancer: a prospective development study. *Eur Urol* 2015;68:927–36.
- [19] Haffner J, Lemaitre L, Puech P, et al. Role of magnetic resonance imaging before initial biopsy: comparison of magnetic resonance imaging-targeted and systematic biopsy for significant prostate cancer detection. *BJU Int* 2011;108:E171–8.
- [20] Feijoo ER, Sivaraman A, Barret E, et al. Focal high-intensity focused ultrasound targeted hemiablation for unilateral prostate cancer: a prospective evaluation of oncologic and functional outcomes. *Eur Urol* 2016;69:214–20.
- [21] van Velthoven R, Aoun F, Marcelis Q, et al. A prospective clinical trial of HIFU hemiablation for clinically localized prostate cancer. *Prostate Cancer Prostatic Dis* 2016;19:79–83.
- [22] Bul M, Zhu X, Valdagni R, et al. Active surveillance for low-risk prostate cancer worldwide: the PRIAS study. *Eur Urol* 2013;63:597–603.
- [23] Klotz L, Zhang L, Lam L, et al. Clinical results of long-term follow-up of a large, active surveillance cohort with localized prostate cancer. *J Clin Oncol* 2012;28:126–31.
- [24] Lee DH, Koo KC, Lee SH, et al. Tumor lesion diameter on diffusion weighted magnetic resonance imaging could help predict insignificant prostate cancer in patients eligible for active surveillance: preliminary analysis. *J Urol* 2013;190:1213–7.
- [25] Vaché T, Bratan F, Mège-Lechevallier F, et al. Characterization of prostate lesions as benign or malignant at multiparametric MR imaging: comparison of three scoring systems in patients treated with radical prostatectomy. *Radiology* 2014;272:446–55.
- [26] Muller BG, Shih JH, Sankineni S, et al. Prostate cancer: interobserver agreement and accuracy with the revised prostate imaging reporting and data system at multiparametric MR imaging. *Radiology* 2015;277:741–50.

available at www.sciencedirect.com
journal homepage: www.europeanurology.com



European Association of Urology



Platinum Priority – Prostate Cancer
Editorial by XXX on pp. x–y of this issue

Focal High-intensity Focused Ultrasound Targeted Hemiblation for Unilateral Prostate Cancer: A Prospective Evaluation of Oncologic and Functional Outcomes

Ernesto R. Cordeiro Feijoo, Arjun Sivaraman, Eric Barret^{*}, Rafael Sanchez-Salas, Marc Galiano, Francois Rozet, Dominique Prapotnich, Nathalie Cathala, Annick Mombet, Xavier Cathelineau

Department of Urology, Institut Montsouris, Université Paris-Descartes, Paris, France

Article info

Article history:

Accepted June 14, 2015

Associate Editor:

Giacomo Novara

Keywords:

Prostate cancer
Focal therapy
High-intensity focused ultrasound
Hemiblation

Abstract

Background: In selected patients with unilateral, organ-confined prostate cancer (PCa), hemiblation of the affected lobe might be feasible to achieve acceptable cancer control with fewer complications.

Objectives: To assess the oncologic and functional outcomes of focal high-intensity focused ultrasound (HIFU) hemiblation in unilateral organ-confined PCa.

Design, setting and patients: Single-center prospective evaluation of HIFU hemiblation for unilateral organ-confined PCa was performed from July 2009 through December 2013.

Intervention: Cancer localization was done with transrectal ultrasound-guided biopsy and multiparametric magnetic resonance imaging followed by HIFU hemiblation.

Outcome measurement and statistical analysis: Oncologic outcomes were analyzed with control biopsies and prostate-specific antigen (PSA) measurement. Functional outcomes were assessed with validated questionnaires for genitourinary symptoms.

Results and limitations: Of 71 HIFU hemiblation patients, 67 completed the study protocol. The mean age was 70.2 yr (standard deviation: 6.8 yr), and median PSA was 6.1 ng/ml (interquartile range [IQR]: 1.6–15.5 ng/ml). Median maximum cancer-core length was 3 mm (IQR: 2–10 mm), and total cancer length was 6.5 mm (IQR: 2–24 mm). Gleason score was 6 (3 + 3) in 58 patients (86.6%) and 7 (3 + 4) in 9 patients (13.4%). Median follow-up was 12 mo (IQR: 6–50 mo), and at 12 mo, 56 of 67 patients had a negative control biopsy in the treated lobe. At 3 mo, all patients were continent, and potency was maintained in 11 of 21 preoperatively potent patients (confidence interval, 0.18–0.69). Complications included 8% Clavien–Dindo grade 2 and 2.8% grade 3 events.

Conclusions: Focal HIFU hemiblation appears to achieve acceptable oncologic outcomes with low morbidity and minimal functional changes. Longer follow-up will establish future considerations.

Patient summary: This study showed that high-intensity focused ultrasound hemiblation in selected patients with unilateral organ-confined prostate cancer can be used for satisfactory cancer control with minimal effect on genitourinary functions.

© 2015 European Association of Urology. Published by Elsevier B.V. All rights reserved.

^{*} Corresponding author. Department of Urology, Institut Montsouris, Université Paris-Descartes, 42, Bd Jourdan, 75674 Paris Cedex 14, France.
E-mail address: eric.barret@imm.fr (E. Barret).

<http://dx.doi.org/10.1016/j.eururo.2015.06.018>

0302-2838/© 2015 European Association of Urology. Published by Elsevier B.V. All rights reserved.

Please cite this article in press as: Feijoo ERC, et al. Focal High-intensity Focused Ultrasound Targeted Hemiblation for Unilateral Prostate Cancer: A Prospective Evaluation of Oncologic and Functional Outcomes. Eur Urol (2015), <http://dx.doi.org/10.1016/j.eururo.2015.06.018>

1. Introduction

The incidence of prostate cancer (PCa) is steadily increasing worldwide, and PCa is the most frequently diagnosed cancer in men [1]. Current screening strategies have led to earlier diagnosis of PCa at lower clinical stages, lower grades, and smaller volumes [2]. A wide variety of ablative methods have been introduced and applied in recent years as focal treatment (FT) alternatives with which cancer foci can be eradicated within the prostate gland, thus greatly reducing the associated side effects of radical treatment. Although FT is not yet the standard for organ-confined PCa, it is the therapeutic approach with the most important potential [3]. Among the multiple options for ablation, high-intensity focused ultrasound (HIFU) and cryoablation—the present authors have ample experience with both—have been clinically available during the past 15 yr and have undergone continuous development over time. In this context, HIFU is a promising technique that has proven medium- to long-term cancer control with a low rate of complications, comparable with those of established therapies [4]. In the present study, we assessed the oncologic and functional outcomes at 1-yr follow-up of patients with unilateral low-risk organ-confined PCa treated at our center with focal HIFU hemiablation.

2. Patients and methods

2.1. Study design and patients

From July 2009 to December 2013, focal HIFU hemiablation was offered to patients who had a diagnosis of unilateral localized PCa in our institution. Inclusion criteria were unilateral disease, clinical stage T1c–T2a, maximum positive biopsies <33%, Gleason score ≤ 7 (3+4), prostate-specific antigen (PSA) <15 ng/ml, no extraprostatic extension disease on multiparametric magnetic resonance imaging (mp-MRI), and life expectancy >10 yr. Patients with previous PCa-related treatment were excluded.

2.2. Study intervention

2.2.1. Cancer localization

Cancer grade and laterality were confirmed with transrectal ultrasound (TRUS)-guided biopsy and mp-MRI. For TRUS biopsy, a conventional two-dimensional gray-scale TRUS probe was used, and all patients had a minimum of 20 cores for cancer localization. For mp-MRI, all patients underwent 1.5-T MRI without endorectal coil for assessment of the prostate. The multiparametric components used were diffusion and perfusion images; however, all hemiablation was based on the TRUS biopsy results, including cases with a discrepancy in laterality between biopsy and MRI and “MRI-invisible” PCa.

2.2.2. Treatment

Hemablation was carried out using the Ablatherm HIFU system (EDAP TMS, Lyon, France). This system includes a treatment table, a probe-positioning system, an ultrasound power generator, a cooling system for preservation of the rectal wall, a computerized control module with specific software, and an endorectal probe with a biplane imaging probe working at 7.5 MHz and a 3-MHz treatment transducer focused at a maximum of 45 mm. In addition, automatic applicator adjustment and multiple security circuits excluded accidental focusing on the rectal wall, avoiding rectal injury.

For this procedure, the transducer was inserted into the rectum and was covered by a condom through which cooled water was circulated to cool the rectal wall; multiple gland images were taken. Because of the proximity of the prostate, the focal lengths of the transducer could be kept short, permitting the use of ultrasound frequencies in the range of 3–4 MHz. They produced small but very precisely defined lesions, with the aim of treating the gland partially (hemablation) by juxtaposition of elementary lesions. Larger areas were ablated by moving the transducer electronically and adding one lesion to another. The main sonication parameters were acoustic intensity, duration of exposure, on:off ratio, the distance between two elementary lesions, and the displacement path when multiple lesions were made. A safety margin of 4–6 mm from the sphincter was given to prevent sphincter damage. The entire procedure was carried out within 120 min, and an indwelling urethral catheter was placed after the procedure.

2.2.3. Follow-up

The Clavien–Dindo classification system was used to grade postoperative complications. Oncologic and functional outcomes were analyzed during follow-up. Control biopsies were performed within the first year of follow-up, constituting the primary end point. Prostate biopsies at 12 mo (12 core, bisextant, TRUS guided) were performed according to the mandatory protocol and directed at both treated and untreated portions of the prostate. Treatment failure was defined as a positive biopsy in the treated lobe or a need for salvage therapy.

Follow-up visits consisted of taking a history and a physical examination and completing International Continence Society (ICS), International Prostate Symptom Score (IPSS), and International Index of Erectile Function (IIEF-5) questionnaires, which were filled in at preoperative and follow-up visits. Continence was defined as the patient having no involuntary urine leak and being completely pad free. Potency was defined as an IIEF score ≥ 22 without any medications to improve erection. In addition, PSA evaluation was performed at 3, 6, and 12 mo and every 6 mo thereafter. Data were collected prospectively and analyzed retrospectively.

2.3. Statistical analysis

The Wilcoxon signed-rank test was used to compare variation in distribution of IPSS, ICS, and IIEF-5 scores between the preoperative and 3-mo follow-up scores. Box plot graphics were computed to describe PSA values over the follow-up period. Cross-tabs applying chi-square or Fisher exact tests were used to assess the relationships among categorical variables. A p value <0.05 was considered statistically significant. Statistical analysis was performed using PASW Statistics 18.0 for Windows (IBM Corp, Armonk, NY, USA).

3. Results

3.1. Demographic and cohort data

During the period of inclusion, 71 patients with localized PCa were assigned to the focal HIFU hemiablation single-institution protocol. Four patients (5.6%) refused the control biopsy and thus were excluded from the final analysis. Sixty-seven patients (94.3%) had complete follow-up data and formed the study population. The mean age at time of treatment was 70.2 yr (standard deviation [SD]: 6.8 yr). Mean body mass index was 25.5 kg/m² (SD: 6.5 kg/m²). The median number of biopsy cores was 22 (interquartile range [IQR]: 20–69). Median maximum cancer-core length (MCCL) was 3 mm (IQR: 2–10 mm), and the total cancer length (TCL) was

Table 1 – Demographics and preoperative data

Variable	Value
No. of patients	67
Age, yr, mean (SD)	70.2 (6.8)
Follow-up, mo, median (IQR)	12 (6–50)
Body mass index, kg/m ² , mean (SD)	25.5 (6.5)
Number of biopsies, median (IQR)	22 (20–69)
MRI prostate volume, ml, mean (SD)	39.3 (13.7)
Preoperative PSA, ng/ml, median (IQR)	6.1 (1.6–15.5)
Gleason score, entry biopsy, n (%)	
3 + 3	58 (86.6)
3 + 4	9 (13.4)

IQR = interquartile range; MRI = magnetic resonance imaging; PSA = prostate-specific antigen; SD = standard deviation.

6.5 mm (IQR: 2–24 mm). At baseline, Gleason score was 3 + 3 and 3 + 4 in 58 (86.6%) and 9 (13.4%) patients, respectively. Preoperative median PSA was 6.1 ng/ml (IQR: 1.6–15.5 ng/ml), and mean prostate volume was 39.3 ml (SD: 13.7 ml). Forty-two (62.7%) and 25 (37.3%) patients received HIFU hemiablation on the right and on the left prostatic lobes, respectively. Preoperative mp-MRI was performed in all patients, and 62.7% (42 of 67) had an index lesion detectable at MRI. All index lesions were detected at the side of the planned hemiablation, and the median maximal diameter of the index lesion was 6 mm (IQR: 4–9 mm). Baseline characteristics are shown in Table 1.

3.2. Postoperative data: early oncologic control at 12 months

The median follow-up was 12 mo (IQR: 6–50 mo), with 52 patients followed >16 mo. The negative control biopsy was noted in 50 of the 67 evaluated patients; specifically,

negative biopsy in the treated lobe was seen in 56 patients. Eleven patients presented with positive biopsies in the treated lobe; of those, 1 patient had a bilateral positive biopsy (nine positive biopsies on the right lobe and two on the left lobe), and 6 patients presented positive biopsies in the nontreated lobe along with negative biopsies in the treated lobe. Median MCCL of the positive control biopsy was 1 mm (IQR: 1–2 mm), and TCL was 2 mm (IQR: 1–3 mm). The patient flowchart is shown in Figure 1.

Failure was observed in 11 cases; of these, positive control biopsies were identified in the right side in 9 cases and in left side in 2 cases. Biopsies were positive at the base in four cases, at the midpart in six, and at the apex in one. Failure was significantly higher following right-lobe hemiablation than left hemiablation (21.4% vs 8%, *p* < 0.05); however, no significant differences were noted regarding the location of recurrence within the prostatic lobe.

The median PSA concentration dropped by 43% at 3 mo (*p* < 0.001), and this decline persisted throughout the follow-up period. No undetectable PSA was reported. The PSA results at follow-up are shown in Figure 2. The median PSA nadir was 2.6 ng/ml (IQR: 0.2–11.1 ng/ml). Of the 67 evaluable patients, biochemical recurrence was verified in 6 patients (9.7%) based on Phoenix criteria.

3.3. Postoperative data: functional outcomes

At baseline, preoperative mean scores were 6.24 (range: 0–26), 0.42 (range: 0–8), and 17.97 (range: 0–25) for the IPSS, ICS, and IIEF-5 questionnaires, respectively. All patients were continent before and after treatment. Evaluation at the 3-mo postoperative period showed no significant changes for both IPSS (*p* = 0.217) and ICS scores (*p* = 0.840). In the same time

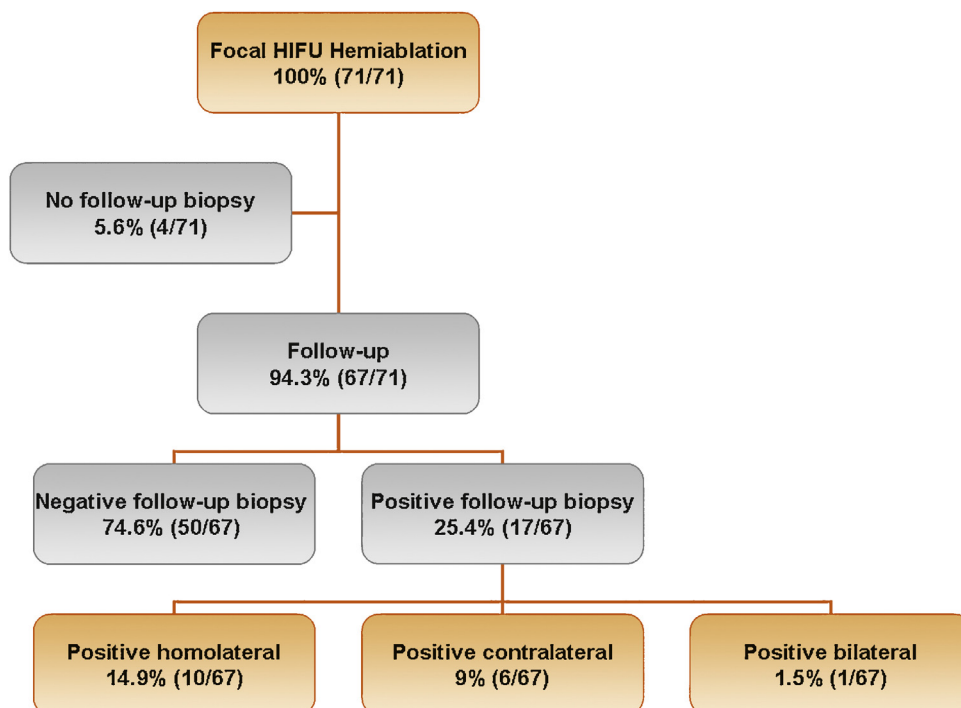


Fig. 1 – Patient flowchart.

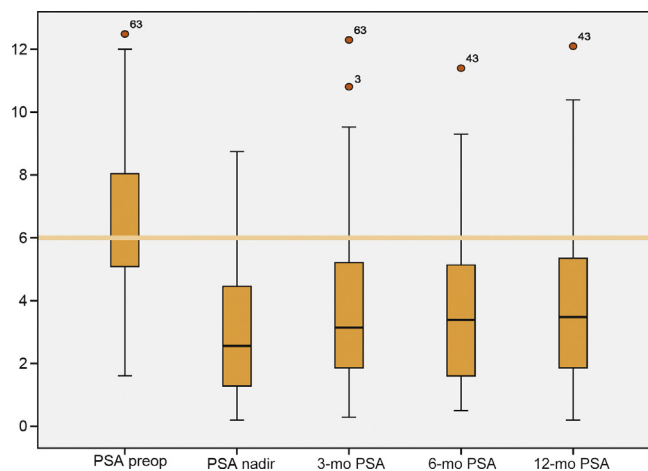


Fig. 2 – Prostate-specific antigen values over time in the follow-up period. Preop = preoperatively; PSA = prostate-specific antigen.

period, potency (defined by IIEF-5 score ≥ 22) was maintained in 11 of 21 preoperatively potent patients (confidence interval, 0.18–0.69). Data for IPSS and IIEF-5 scores over the follow-up period are shown in Figure 3.

3.4. Complications

All complications were encountered within the first postoperative month. Ten patients (14%) had postoperative complications: Eight complications were grade 2 (11.2%; four urinary infections and four urinary retentions) and two were grade 3b (2.8%; two urinary retentions treated with transurethral resection of the prostate [TURP]).

4. Discussion

Since the 1990s, HIFU has been used for the treatment of PCa [4]. Worldwide experience (whole gland, either as primary or salvage therapies) showed significant improvement in both

oncologic and functional outcomes with fewer complications [5–9]. To date, however, the available evidence for HIFU focal ablation is recent but limited.

Currently, the consensus definition states that FT is “any approach able to preserve part of the prostatic tissue, whether by targeted ablation, hemiablation and zonal ‘hockey stick’ ablation” [10,11]. Clinically acceptable cancer control following FT is generally agreed for retreatment rates of $\leq 20\%$ [12]. The goal of FT is to achieve “trifecta” outcomes: cancer control, fewer complications, and preservation of genitourinary function comparable to radical treatment options. In this context, our preliminary results are encouraging, as shown by the high efficacy rate with low morbidity rates and minimal functional changes.

In the present study, the rate of negative biopsy in the treated area was 83.6%, and the overall negative biopsy rate was 74.6%. PSA declined significantly at 3 mo and persisted throughout follow-up. These outcomes are consistent with the initial reports of reported HIFU hemiablation by Ahmed et al [13]. At 12-mo follow-up, mean PSA decreased to 1.5 ± 1.3 ng/ml, and 89% had no cancer in the treated area [13]. More recently, the same group published a prospective series of 41 patients, with HIFU FT delivered using the Sonablate 500 (SonaCare Medical, Charlotte, NC, USA) to all suspected tumor lesions and a maximum of 60% of the prostate ablated. Negative biopsy was noted in 30 of 39 patients (77%) at 6 mo, with a significant decrease in PSA from 6.6 to 1.9 ng/ml at 12 mo [14].

As for the functional outcomes, we found that both continence and urinary symptoms were not affected, but there was a significant negative impact on erection. This result is consistent with those of Ahmed et al [14], who reported significant deterioration between baseline and 12 mo for erectile ($p = 0.042$) and orgasmic ($p = 0.03$) function domains, followed by gradual return to baseline by 12 mo [14]. Data on contemporary oncologic and functional outcomes of HIFU focal ablation for PCa are shown in Table 2.

Complications noted in the present series were predominantly low grade and comparable to the consolidated outcomes of various energies in FT, as shown by Barret et al [16]. Prostate volume appears to be an important

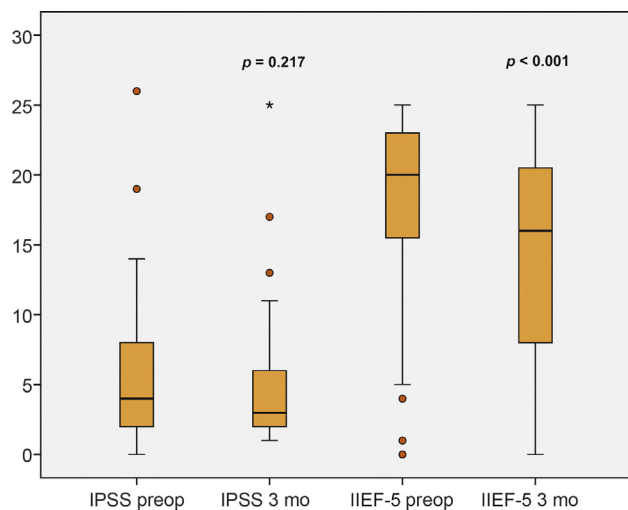


Fig. 3 – International Prostate Symptom Score and International Index of Erectile Function scores over the follow-up period. IIEF-5 = 5-item International Index of Erectile Function; IPSS = International Prostate Symptom Score; preop = preoperatively.

Table 2 – Contemporary outcomes on high-intensity focused ultrasound focal ablation for prostate cancer

Study	Patients, n	Mean preprocedural PSA	Mean prostate volume	Gleason score	Cancer localization	Mean follow-up	Biopsy recurrence	Continence, %	Potency
Ahmed et al (2011) [13]	20	7.3	NA	≤4 + 3	MRI and transperineal template-guided mapping biopsy	12 mo	11% at 6 mo	90	95%
El Fegoun et al (2011) [15]	12	7.3	37	≤4 + 3	TRUS biopsy	10 yr	8% at 1 yr	100	NA
Ahmed et al (2012) [14]	41	6.6		≤4 + 3	MRI and transperineal template-guided mapping biopsy	12 mo	23% at 6 mo	100	89%
Barret et al (2013) [16]	21	6	43	3 + 3	Transperineal template-guided mapping biopsy	12 mo	NA	100	Mean IIEF decreased from 20 to 19
Present study (2015)	67	6.1	36	≤3 + 4	MRI and TRUS biopsy	12 mo	16.4% at 1 yr	100	Mean IIEF decreased from 17.9 to 15.4

IIEF = International Index of Erectile Function; MRI = magnetic resonance imaging; NA = not available; PSA = prostate-specific antigen; TRUS = transrectal ultrasound.

factor in post-HIFU urinary retention. Although we did not perform statistical analysis, pretreatment TURP in large prostates can reduce urinary retention and improve treatment efficacy.

Another interesting finding of this study has not been reported in the literature previously. Significantly more positive control biopsies resulted following hemiablation of the right lobe than the left. We believe this trend of failure following right hemiablation might be related to the technical difficulties of the HIFU probe reaching the right side of the prostate, since patients lie on their left flank on the Ablatherm operating table; however, no statistical differences were found between the initial cancer location

in the treated area and the location of failure within the prostatic lobe. This finding needs verification in future studies with larger patient populations.

4.1. Clinical implications

The present study highlights the feasibility of tissue-preserving FT with acceptable trifuca rates for PCa. Nonetheless, we understand that several key issues require standardization for routine use of FT in clinical practice. Accurate index lesion localization in terms of laterality and grade is vital for the success of FT. In our study, mp-MRI and TRUS biopsy were used, and Tables 2 and 3 show the

Table 3 – Comparison of outcomes among different energy modalities on high-intensity focused ultrasound hemiablation for prostate cancer

Study	Patients, n	Mean preprocedural PSA	Energy	Route of delivery	Gleason score	Cancer localization	Mean follow-up	Biopsy recurrence	Continence, %	Potency
Bahn et al (2006) [17]	31	4.9	Cryotherapy	Transperineal	≤7	Color Doppler ultrasonography with target and systemic biopsies	5.8 yr	4%	100	88.9%
Lambert et al (2007) [18]	25	6	Cryotherapy	Transperineal	≤7	TRUS biopsy	28 mo	1 patient treated of 7 biopsied patients	100	68%
Ellis et al (2007) [19]	60	7.2	Cryotherapy	Transperineal	3 + 3	TRUS biopsy	15.2 mo	23.3%	96	70.5%
Truesdale et al (2010) [20]	77	6.5	Cryotherapy	Transperineal	≤4 + 4	TRUS biopsy	24 mo	3 patient treated of 22 biopsied patients	100	NA
Bahn et al (2012) [21]	70	5.9	Cryotherapy	Transperineal	≤7	Color Doppler ultrasonography with target and systemic biopsies	3.7 yr	1 patient treated of 36 biopsied patients	100	86%
Cosset et al (2013) [22]	21	6.9	Brachytherapy	Transperineal	≤3 + 4	Saturation biopsy	12 mo	None of 6 patients biopsied had ipsilateral recurrence	100	Mean IIEF decreased from 20.1 to 19.8
Moore et al (2006) [23]	6	1.9–15	Photodynamic therapy	Transperineal	3 + 3	NA	NA	100%	NA	100%

IIEF = International Index of Erectile Function; NA = not available; PSA = prostate-specific antigen; TRUS = transrectal ultrasound.

localization techniques used in the previously published hemiablation series. Currently, mp-MRI appears to be a promising tool for accurate cancer detection, but real-time monitoring of FT appears to be technically demanding. Recent advances in multiparametric ultrasonography (shear wave elastography, contrast-enhanced ultrasound) will have interesting applications in FT for cancer localization and possibly real-time monitoring of therapy.

Presently, FT is often criticized as a psychological treatment for patients requiring active surveillance, with questionable oncologic control. Our series represents patients with longer MCCL and TCL and Gleason 7 (3 + 4) cancers. The early, encouraging oncologic control can potentially prompt the extension of FT to patients undergoing RP for small-volume, intermediate-risk PCa.

With regard to follow-up after primary HIFU with curative intent, we found that control biopsies and biochemical recurrence (BCR) were not systematically associated. The index lesion accounts for 80% of the PSA value, and the untreated insignificant satellite lesions, remaining prostate volume, and body mass index influence the postoperative PSA [24]. We believe BCR needs to be clearly defined, and both the Phoenix and the American Society for Therapeutic Radiology and Oncology (ASTRO) criteria are of questionable value in FT. Recently, the Stuttgart definition (PSA increase of 1.2 ng/ml above the PSA nadir value) has been suggested for HIFU treatment [25]; however, this definition remains to be validated in prospective trials and seems difficult to use in so far as it has been established for the treatment of the whole prostate and does not take into account the residual PSA secretion from the untreated lobe.

The altered anatomy following FT limits the utility of imaging in follow-up. We strongly emphasize the need for systematic biopsies of both lobes at a 12-mo period for reliable cancer detection.

4.2. Limitations

First, the study size was relatively small, and the study was nonrandomized and had shorter follow-up. A larger study population with comparison of whole-gland treatment or radical treatment might have highlighted the specific advantages and drawbacks of HIFU hemiablation. Second, we used TRUS biopsy and MRI for index lesion localization, followed by control TRUS biopsies at 12 mo. Although this strategy was developed from previous experiences, we are still unaware of the percentage of significant disease missed; only longer follow-up will allow these cancers to surface. Third, the inclusion criteria resulted in involvement of low-volume, low-risk patients in FT; however, we included relatively larger cancers after encouraging early results. With the availability of MRI targeted biopsies, stringent inclusion criteria based on target and cancer core length with MRI grading will enable accurate reporting of the treated cancers.

4.3. Future directions

The emergence of FT as an intermediate treatment option between radical prostatectomy and active surveillance has

resulted in several energy modalities being developed (Table 3). Future research should focus on ultrafocal ablation of index lesions with maximal tissue preservation and reduction of the invasiveness of the therapy. The concept of the index lesion needs stronger validation, and genetic analysis should be explored as a potential guide for patient selection. Despite the high negative predictive value of mp-MRI, a few MRI-invisible, aggressive cancers can limit FT application. Improved reporting strategies like panel discussion and multiparametric ultrasonography fusion techniques for equivocal findings can potentially reduce errors. The role of imaging and PSA in follow-up should be critically analyzed and defined.

5. Conclusions

Focal HIFU hemiablation constitutes an attractive therapeutic alternative for selected patients with localized PCa. Our preliminary results are encouraging, as shown by the high efficacy rate along with low morbidity rates and minimal functional changes. Longer follow-up is expected to establish further considerations of this novel approach.

Author contributions: Eric Barret had full access to all the data in the study and takes responsibility for the integrity of the data and the accuracy of the data analysis.

Study concept and design: Cordeiro Feijoo, Barret.

Acquisition of data: Cordeiro Feijoo, Barret, Sanchez-Salas.

Analysis and interpretation of data: Cordeiro Feijoo, Sivaraman.

Drafting of the manuscript: Cordeiro Feijoo, Sivaraman.

Critical revision of the manuscript for important intellectual content: Rozet, Galiano.

Statistical analysis: Cordeiro Feijoo, Sanchez-Salas.

Obtaining funding: None.

Administrative, technical, or material support: Cathala, Mombet, Prapotnich.

Supervision: Barret, Cathelineau.

Other (specify): None.

Financial disclosures: Eric Barret certifies that all conflicts of interest, including specific financial interests and relationships and affiliations relevant to the subject matter or materials discussed in the manuscript (eg, employment/affiliation, grants or funding, consultancies, honoraria, stock ownership or options, expert testimony, royalties, or patents filed, received, or pending), are the following: None.

Funding/Support and role of the sponsor: None.

References

- [1] Siegel R, Ma J, Zou Z, Jemal A. Cancer statistics, 2014. *CA Cancer J Clin* 2014;64:9–29.
- [2] Stattin P, Holmberg E, Johansson JE, Holmberg L, Adolfsen J, Hugosson J. Outcomes in localized prostate cancer: National Prostate Cancer Register of Sweden follow-up study. *J Natl Cancer Inst* 2010;102:950–8.
- [3] Heidenreich A, Bastian PJ, Bellmunt J, et al. EAU guidelines on prostate cancer. part 1: screening, diagnosis, and local treatment with curative intent-update 2013. *Eur Urol* 2014;65:124–37.
- [4] Madersbacher S, Pedevilla M, Vingers L, Susani M, Marberger M. Effect of high-intensity focused ultrasound on human prostate cancer in vivo. *Cancer Res* 1995;55:3346–51.

- [5] Cordeiro ER, Cathelineau X, Thuroff S, Marberger M, Crouzet S, de la Rosette JJ. High-intensity focused ultrasound (HIFU) for definitive treatment of prostate cancer. *BJU Int* 2012;110:1228–42.
- [6] Vallancien G, Prapotnich D, Cathelineau X, Baumert H, Rozet F. Transrectal focused ultrasound combined with transurethral resection of the prostate for the treatment of localized prostate cancer: feasibility study. *J Urol* 2004;171:2265–7.
- [7] Rebillard X, Soulie M, Chartier-Kastler E, et al. High-intensity focused ultrasound in prostate cancer; a systematic literature review of the French Association of Urology. *BJU Int* 2008;101:1205–13.
- [8] Crouzet S, Poissonnier L, Murat FJ, et al. Outcomes of HIFU for localised prostate cancer using the Ablatherm Integrate Imaging® device [in French]. *Prog Urol* 2011;21:191–7.
- [9] Lukka H, Waldron T, Chin J, et al. High-intensity focused ultrasound for prostate cancer: a systematic review. *Clin Oncol (R Coll Radiol)* 2011;23:117–27.
- [10] Valerio M, Ahmed HU, Emberton M, et al. The role of FT in the management of localised prostate cancer: a systematic review. *Eur Urol* 2014;66:732–51.
- [11] Van den Bos W, Muller BG, Ahmed H, et al. FT in prostate cancer: international multidisciplinary consensus on trial design. *Eur Urol* 2014;65:1078–83.
- [12] Donaldson IA, Alonzi R, Barratt D, et al. Focal therapy: patients, interventions, and outcomes—a report from a consensus meeting. *Eur Urol* 2015;67:771–7.
- [13] Ahmed HU, Freeman A, Kirkham A, et al. FT for localized prostate cancer: a phase I/II trial. *J Urol* 2011;185:1246–54.
- [14] Ahmed HU, Hindley RG, Dickinson L, et al. FT for localised unifocal and multifocal prostate cancer: a prospective development study. *Lancet Oncol* 2012;13:622–32.
- [15] El Fegoun AB, Barret E, Prapotnich D, et al. FT with high-intensity focused ultrasound for prostate cancer in the elderly. A feasibility study with 10 years follow-up. *Int Braz J Urol* 2011;37:213–9.
- [16] Barret E, Ahallal Y, Sanchez-Salas R, et al. Morbidity of FT in the treatment of localized prostate cancer. *Eur Urol* 2013;63:618–22.
- [17] Bahn DK, Silverman P, Lee Sr F, Badalament R, Bahn ED, Rewcastle JC. Focal prostate cryoablation: initial results show cancer control and potency preservation. *J Endourol* 2006;20:688–92.
- [18] Lambert EH, Bolte K, Masson P, Katz AE. Focal cryosurgery: encouraging health outcomes for unifocal prostate cancer. *Urology* 2007;69:1117–20.
- [19] Ellis DS, Manny Jr TB, Rewcastle JC. Cryoablation as primary treatment for localized prostate cancer followed by penile rehabilitation. *Urology* 2007;69:306–10.
- [20] Truesdale MD, Cheetham PJ, Hruby GW, et al. An evaluation of patient selection criteria on predicting progression-free survival after primary focal unilateral nerve-sparing cryoablation for prostate cancer: recommendations for follow up. *Cancer J* 2010;16:544–9.
- [21] Bahn D, de Castro Abreu AL, Gill IS, et al. Focal cryotherapy for clinically unilateral, low-intermediate risk prostate cancer in 73 men with a median follow-up of 3.7 years. *Eur Urol* 2012;62:55–63.
- [22] Cosset J-M, Cathelineau X, Wakil G, et al. Focal brachytherapy for selected low-risk prostate cancers: a pilot study. *Brachytherapy* 2013;12:331–7.
- [23] Moore CM, Nathan TR, Lees WR, et al. Photo dynamic therapy using meso tetra hydroxy phenyl chlorine (mTHPC) in early prostate cancer. *Lasers Surg Med* 2006;38:356–63.
- [24] Ahmed HU. Introduction—targeting the lesion, not the organ. *Urol Oncol* 2014;32:901–2.
- [25] Blana A, Brown SC, Chaussy C, et al. High-intensity focused ultrasound for prostate cancer: comparative definitions of biochemical failure. *BJU Int* 2009;104:1058–62.

Hemi salvage high-intensity focused ultrasound (HIFU) in unilateral radiorecurrent prostate cancer: a prospective two-centre study

Eduard Baco, Albert Gelet*[†], Sébastien Crouzet*[†], Erik Rud[¶], Olivier Rouvière^{†‡§}, Hélène Tonoli-Catez*, Viktor Berge, Jean-Yves Chapelon[†] and Heidi B. Eggesbø^{††}

*Division of Surgery and Cancer Medicine, Department of Urology Oslo University Hospital, Aker, Norway, * Hospices Civils de Lyon, Department of Urology and Transplantation Surgery, Edouard Herriot Hospital, Lyon, France, [†]Inserm, U1032, LabTau, [‡]Department of Urinary and Vascular Imaging, and [§]Faculté de Médecine, Hospices Civils de Lyon, Edouard Herriot Hospital, Lyon, France, [¶]Division of Diagnostic and Intervention, Department of Radiology and Nuclear Medicine, Oslo University Hospital, Aker, and ^{††}Division of Diagnostic and Intervention, Department of Radiology and Nuclear Medicine, Oslo University Hospital, Rikshospitalet, Norway*

E.B. and A.G. contributed equally to this work

Objective

- To report the oncological and functional outcomes of hemi salvage high-intensity focused ultrasound (HSH) in patients with unilateral radiorecurrent prostate cancer.

Patients and Methods

- Between 2009 and 2012, 48 patients were prospectively enrolled in two European centres. Inclusion criteria were biochemical recurrence (BCR) after primary radiotherapy (RT), positive magnetic resonance imaging and ≥ 1 positive biopsy in only one lobe.
- BCR was defined using Phoenix criteria (a rise by ≥ 2 ng/mL above the nadir prostate specific antigen [PSA] level).
- The following schemes and criteria for functional outcomes were used: Ingelman-Sundberg score using International Continence Society (ICS) questionnaire (A and B), International prostate symptom score (IPSS), International Index of Erectile Function-5 (IIEF-5) points, the European Organisation for the Research and Treatment of Cancer (EORTC) quality of life questionnaires (QLQ C-30).
- HSH was performed under spinal or general anaesthesia using the Ablatherm[®] Integrated Imaging device. Patients with obstructive voiding symptoms at the time of treatment underwent an endoscopic bladder neck resection or incision during the same anaesthesia to prevent the risk of postoperative obstruction.

Results

- After HSH the mean (SD) PSA nadir was 0.69 (0.83) ng/mL at a median (interquartile range) follow-up of 16.3 (10.5–24.5) months.

- Disease progression occurred in 16/48 (33%). Of these, four had local recurrence in the untreated lobe and four bilaterally, six developed metastases, and two had rising PSA levels without local recurrence or radiological confirmed metastasis. Progression-free survival rates at 12, 18, and 24 months were 83%, 64%, and 52%.
- Severe incontinence occurred in four of the 48 patients (8%), eight (17%) required one pad a day, and 36/48 (75%) were pad-free. The ICS questionnaire showed a mean (SD) deterioration from 0.7 (2.0) to 2.3 (4.5) for scores A and 0.6 (1.4) to 1.6 (3.0) for B.
- The mean (SD) IPSS and erectile function (IIEF-5) scores decreased from a mean (SD) of 7.01 (5.6) to 8.6 (5.1) and from 11.2 (8.6) to 7.0 (5.8), respectively.
- The mean (SD) EORTC QLC-30 scores before and after HSH were 35.7 (8.6) vs 36.8 (8.6).

Conclusion

- HSH is a feasible therapeutic option in patients with unilateral radiorecurrent prostate cancer, which offers limited urinary and rectal morbidity, and preserves health-related quality of life.

Keywords

external beam radiotherapy, hemi-salvage treatment, high-intensity focused ultrasound (HIFU), local recurrence, prostate cancer, oncological outcomes, functional outcomes, EORTC QLC-30

Introduction

Patients who receive radiotherapy (RT) for localised prostate cancer have a risk of disease recurrence [1]. The Cancer of the Prostate Strategic Urologic Research Endeavor (CaPSURE) study found a two-fold higher likelihood of cancer-specific mortality in patients treated with RT vs radical prostatectomy (RP) [2]. However, for patients with high-risk prostate cancer, no significant difference in long-term cancer control was found when comparing external beam RT (EBRT) combined with androgen-deprivation therapy (ADT) with RP [3]. Using the Phoenix criteria, the GETUG 06 study found the estimated risk of biochemical recurrence (BCR) after EBRT to be 32% in patients treated with 70 Gy and 23.5% when treated with 80 Gy, after 5 years [4]. After brachytherapy (BT), the Seattle group reported a BCR rate close to 20% at 15 years follow-up and a cancer-specific mortality rate of 16% [5]. Most patients (>90%) with BCR receive ADT, that suppresses the PSA output.

Every whole-gland salvage therapy approach, e.g. RP, high-intensity focused ultrasound (HIFU) or cryotherapy, carries the potential of serious morbidity, such as development of severe urinary incontinence, urethral stenosis, and urethrorectal fistula [6–9]. To date, the best predictor of successful treatment outcome is pre-salvage therapy serum PSA level, with better outcomes associated with PSA levels of ≤ 5 ng/mL [10]. MRI-guided targeted prostate biopsy may be valuable in detecting EBRT recurrence [6,11,12].

In patients who present small-sized local recurrence after primary RT, hemi salvage HIFU (HSH) therapy has been shown to be an effective treatment with reduced complications and side-effects [6].

The objective of the present two-centre study was to evaluate the oncological and functional outcomes of HSH in patients with unilateral radiorecurrent prostate cancer.

Patients and Methods

Between 2009 and 2012, 48 consecutive patients (mean [SD, range] age of 68.8 [6.0, 58–82] years) with radiorecurrent prostate cancer were enrolled for participation at Edouard Herriot Hospital, Lyon, France (27 patients) and Oslo University Hospital, Aker, Norway (21). This study received approval by the local ethics committees in France and in Norway. All patients signed a letter of informed consent before enrolment. No patient was missing during the follow-up.

Inclusion criteria were BCR (defined as Phoenix criteria: nadir ≥ 2 ng/mL, in 46/48, or three consecutive rises in PSA level in two of 46), unilateral prostate cancer at MRI verified with prostate biopsy and absence of metastases verified at bone scan, pelvic CT or MRI. Previous therapy for prostate cancer

Table 1 Characteristics of the 48 patients with localised radiorecurrent prostate cancer treated with HSH before and after RT.

Variable	Value
Before RT	
N (%):	
D'Amico risk group	
low	10 (21)
intermediate	12 (25)
high	20 (42)
unknown	6 (12)
Gleason score	
≤ 6	18 (38)
7	17 (35)
≥ 8	9 (19)
unknown	4 (8)
Mean (SD, range)	
Gleason score	6.7 (1.3,3–9)
PSA level, ng/mL	14.2 (12.1,2.9–70)
After RT	
Mean (SD, range)	
Nadir PSA, ng/mL	0.71 (0.64,0–3.3)
Years to nadir PSA	1.8 (1.2,0–5.5)
Years to nadir +2	4.8 (2.6,1.8–12.8)

Table 2 Characteristics of the 48 patients with localised radiorecurrent prostate cancer before HSH.

Variable	Value
Gleason score, n (%)	
≤ 6	4 (8)
7	24 (50)
≥ 8	18 (38)
Unknown	2 (4)
Mean (SD, range):	
Total biopsy samples	14.9 (5.1,6–32)
Positive biopsies	3.4 (1.8,1–8)
Prostate volume, mL	21.2 (9.7,7–60)

included EBRT in 46 (mean [SD, range] 72.5 [3.3, 64–78] Gy) and BT in two, and 11 (23%) also received neoadjuvant hormone therapy.

The Gleason score, D'Amico risk group, and PSA levels before and after RT, are given in Table 1 and the patients' characteristics before HSH are given in Table 2. The mean (SD, range) time from the end of RT to HSH was 5.9 (2.6, 2.7–14.6) years.

MRI

The Lyon group used a 3T MR 750[®] MRI (General Electric, Waukesha, WI, USA) and a 32-channel pelvic phased-array coil. Sequences were axial T2-weighted (T2w), diffusion-weighted images (DWI) using b0 and b2000 to generate apparent diffusion coefficient (ADC) maps, and dynamic contrast-enhanced (DCE) MRI (temporal resolution, 7 s) after i.v. injection of 0.2 mL/kg gadoterate meglumine (Dotarem[®], Guerbet, Roissy, France) at 3 mL/s.

The Norwegian group used a 1.5 T Tesla Avanto® MRI (Siemens, Erlangen, Germany) and a six-channel Body MATRIX® coil. Sequences were axial T2w, DWI using b50 and b1000 to generate ADC maps, and an additional b2000. Axial and coronal T1w images were used to identify skeletal and lymph node metastases. Nordic ICE® (NordicNeuroLab, Bergen, Norway) software was used for post-processing images as previously described by Rud et al. [13].

Local recurrence of prostate cancer was defined as a focal area with high signal intensity on b1000 or b2000 native images compared with muscle signal, an ADC of $<120 \times 10^{-5} \text{ mm}^2/\text{s}$ in the peripheral zone, and an ADC of $<100 \times 10^{-5} \text{ mm}^2/\text{s}$ in the transitional zone.

Oncological Outcome Parameters

BCR was defined using Phoenix criteria (a rise by $\geq 2 \text{ ng/mL}$ above the nadir PSA level. D'Amico risk categories were low/intermediate and high [14].

Functional Outcome Parameters

The following schemes and criteria for functional outcomes were used: IPSS, Ingelman-Sundberg score [15] using the ICS questionnaire (A and B) [16], International Index of Erectile Function-5 (IIEF-5 points) [17], and the European Organisation for the Research and Treatment of Cancer (EORTC) quality of life questionnaires (QLQ-C-30) [18].

TRUS-Guided Prostate Biopsy

TRUS-guided prostate biopsy consisted of 12 randomised cores that included the proximal area of the seminal vesicle, and 1–3 biopsies from each MRI target using MRI/TRUS image fusion technology (Koelis®, La Tronche, France) [13].

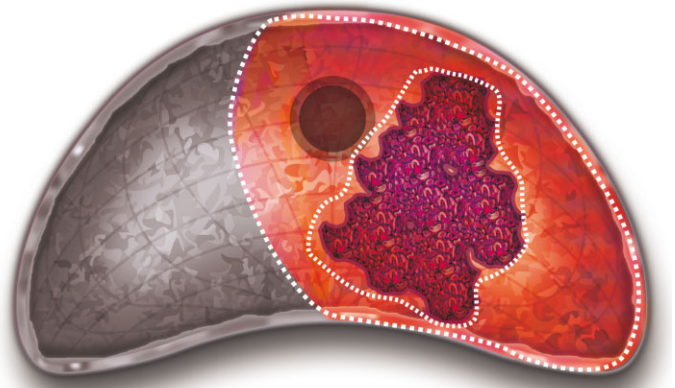
HSH

HSH was performed under spinal or general anaesthesia using the Ablatherm® Integrated Imaging device (EDAP TMS, Vaulx-en-Velin, France). During the fire phase, the software automatically controlled the rectal position, and a cooling system maintained rectal mucosa temperature at 14 °C. Between each fire phase, the focal point position inside the prostate gland was controlled by the operator, in real time [19].

In patients with negative apical biopsy, a 4-mm security distance was held to the sphincter, while in positive apical biopsy, the HIFU shots were performed closer to the sphincter. In patients with tumour invasion in the prostate base, the HIFU shots included the proximal region of the seminal vesicles.

Patients with obstructive voiding symptoms at the time of treatment underwent an endoscopic bladder neck resection or

Fig. 1 Graphical presentation of HIFU treated left prostate lobe in axial plane. Pink area represents the tumour that affects the midline and left periurethral zone. HIFU treated area (orange) is extended over midline and includes the urethra.



incision during the same procedure to prevent postoperative obstruction. In these patients, treatment area was extended medially with at least two HIFU shots that included urethra into the treatment zone as shown in Fig. 1.

Specific radiorecurrence parameters for salvage HIFU treatment were introduced in 2002 and incorporate the unique characteristics of irradiated tissue, e.g. compromised vascularisation and radiation-induced fibrosis [19].

Follow-up

In the Lyon group, patients were discharged after 72 h after Foley catheter removal and post-voiding residual measurement by ultrasound.

In the Oslo group, patients were discharged either on the operative day or after 24 h depending on home distance and comorbidity. Foley catheter removal and post-voiding residual measurement by ultrasound were performed in an out-patient clinic 5 days after HSH.

Follow-up during the first year occurred every 3 months and included oncological and functional outcome parameters as described before HSH.

Patients with rising PSA levels underwent control MRI prostate and subsequent prostate biopsy. Patients with biopsy confirmed local recurrence were encouraged to undergo a second HSH treatment, particularly when malignancy was found in the untreated contralateral lobe. ADT was suggested to patients who refused a second HSH treatment after BCR or histological recurrence, or metastases.

In cases of BCR without local recurrence on MRI the Lyon group underwent a metastatic evaluation, consisting of an ^{11}C -choline positron emission tomography (PET) scan, and the

Oslo group, bone scan and pelvic MRI. Control prostate biopsy was not taken in patients with confirmed metastases.

Statistical Analyses

Statistical analyses were performed with IBM SPSS Statistics software v.21 (IBM Corp., New-York, NY, USA). Depending on distribution, paired sample *t*-test or Wilcoxon signed-ranks test were used to compare oncological and functional outcomes before and after HSH.

Survival curves were based on Kaplan–Meier models, and the log-rank test was used for univariate comparisons. Actuarial survival rates were based on life table methods. Progression-free survival (PFS) rates were calculated using the combined criteria of BCR (Phoenix criteria) and/or the need for ADT, whichever occurred first. Patients were censored on the date of their last PSA evaluation. A $P < 0.05$ was considered to indicate statistical significance.

Results Oncological Outcomes

The mean (SD) PSA nadir after HSH was 0.69 (0.83) ng/mL, and the time to attain PSA nadir was 21 (20.7) weeks. The median (interquartile range) follow-up was 16.3 (10.5–24.5) months. At the end of the follow-up period 32/48 (67%) were free of BCR. Disease progression was identified in 16/48 (33%), in which six (13%) were confirmed metastases.

Local recurrence was identified at MRI and control prostate biopsy in eight of the 48 patients (17%). Prostate biopsy revealed cancer foci in both lobes in four patients, and in the untreated lobe in another four. BCR without proven local recurrence or metastases occurred in two patients. Local recurrences in four of 16 (25%) patients were treated with a second HSH session and 12/16 (75%) received ADT.

The overall PFS rates at 12, 18, and 24 months, with respect to D'Amico risk group, Gleason score before HSH and PSA level before and after HSH are presented in Table 3. The D'Amico risk group before EBRT did not influence the 18-month PFS rate. In contrast, the 18-month PFS rate was significantly associated with Gleason score during post-EBRT recurrence (≤ 7 , 82%; ≥ 8 , 34%; $P = 0.047$), and by the PSA level before HSH (≤ 4 ng/mL, 80%; > 4 ng/mL, 49%, $P = 0.002$).

The 18-month PFS rate did not differ significantly between patients with a PSA nadir after HSH of ≤ 0.5 ng/mL and those with a PSA nadir of > 0.5 ng/mL after HSH (72% vs 56%, $P = 0.3$).

Functional Outcomes

Spontaneous voiding re-established after a mean (SD) catheterisation time of 3.9 (1.2) days. The pad-free, leak-free urinary continence status after HSH was 36/48 (75%) patients, one pad a day in eight (17%), and severe incontinence in four

Table 3 PFS rates in the 48 patients with localised radiorecurrent prostate cancer treated with HSH*.

PFS rate	% (n at risk)	P
Overall PFS rate at:		
12 months	83 (37)	
18 months	64 (23)	
24 months	52 (11)	
PFS rate according to:		
Initial D'Amico risk group:		0.599
Low / intermediate at:		
12 months	88 (17)	
18 months	66 (8)	
24 months	33 (2)	
High at:		
12 months	74 (17)	
18 months	54 (12)	
24 months	45 (6)	
Gleason score before HSH		0.047
3–7 at:		
12 months	88 (23)	
18 months	82 (15)	
24 months	63 (9)	
8–10	72 (13)	
12 months	34 (8)	
18 months	34 (2)	
24 months		
PSA level before HSH:		0.002
≤ 4 ng/mL at:		
12 months	94 (18)	
18 months	80 (14)	
24 months	70 (8)	
> 4 ng/mL at:		
12 months	73 (19)	
18 months	49 (9)	
24 months	32 (3)	
PSA nadir after HSH		0.273
≤ 0.5 ng/mL at:		
12 months	87 (19)	
18 months	72 (12)	
24 months	72 (5)	
> 0.5 ng/mL at:		
12 months	77 (18)	
18 months	56 (11)	
24 months	37 (6)	

(8.3%). All four of these patients had a local recurrence involving the apex, and the HSH therefore was not performed using a sphincter safety margin after patient consent. However, three of these four patients were disease free at last follow-up. The functional outcomes of the ICS (A and B), IPSS, IIEF-5 and EORTC QLC-30 are given in Table 4.

Complications

Two patients had delayed pubic bone osteitis and one of these developed pubovesical fistula appearing 23 months after HSH. No rectal fistula occurred.

Discussion

The present study is the first prospective two-centre study on salvage focal treatment with total cohort follow-up. However, there are several limitations of the present trial.

Table 4 Functional outcome scores of the completed questionnaires in the 48 patients after HSH for localised radio recurrent prostate cancer.

Questionnaire	Mean (sd) score		P
	before HIFU	after HIFU	
ICS (A)	0.7 (2.0)	2.3 (4.5)	0.045
ICS (B)	0.6 (1.4)	1.6 (3.0)	0.114
IPSS	7.1 (5.6)	8.6 (5.1)	0.129
IIEF-5	11.2 (8.0)	7.0 (5.8)	<0.001
EORTC QLC-30	35.7 (8.7)	36.8 (8.6)	0.220

Firstly, MRI protocols used in detection of prostate cancer were not standardised across institutions. The Lyon group performed MRI combining T2w, DW MRI and DCE MRI while the Oslo group performed MRI using T2w and DW MRI. To our knowledge, only one study [20] ($n = 16$) has compared T2w, DW MRI and DCE MRI after BT. They reported a 77% sensitivity when combining all three sequences, contrary to 68%, when using only T2w and DW MRI ($P > 0.05$) [13]. Diagnosis of radio recurrent prostate cancer using T2w and DW MRI sequences is documented by several studies reporting sensitivity ranging from 62% to 93% [21,22]. In addition, a recent study did not show a significant difference in cancer detection comparing 1.5 T and 3 T devices [23].

Secondly, we did not take a control prostate biopsy in patients with BCR and distant metastases occurring during the follow-up, as the biopsy result would not influence the treatment and the biopsy procedure might lead to unnecessary complications.

Thirdly, ^{11}C -choline PET scan, which seems to be the most effective method for metastatic evaluation, was not used in all patients with BCR. However, the diagnosis of metastatic diseases was not an endpoint in the present study.

Fourthly, the present study was limited by the relatively brief follow-up period and limited patient cohort, which hinders any conclusion about oncological effectiveness. A follow-up of 5 years is probably necessary for more accurate biochemical evaluation, cancer-specific and metastases-free survival outcomes after HSH.

Finally, the validity of using Phoenix criteria for failure could be criticised. Nevertheless, to date no common agreement exists on the definition of BCR after ablative therapies. Furthermore, in the largest published reports on HIFU and cryotherapy, oncological outcomes are based on Phoenix criteria as applied to post-RT recurrence [6,24,25].

Accurate patient selection is an essential pre-condition for achieving optimal cancer control with a focal salvage-therapy approach. In theory, the selection process should first exclude patients with subclinical metastases, and then further evaluate only those with small unilateral local recurrences. Detection of

occult lymph node and bone metastases is hampered by limitations in current imaging technology, and by characteristics of the malignancy that make visualisation difficult. Metastases were detected during follow-up in two of 39 patients (5%) in the Ahmed et al. [6] study, and in six of 48 patients (12.5%) in the present study. The high-rate of metastases in the present study may be explained by the elevated percentage of patients with high-risk disease, who probably could have had micrometastases before HSH.

Broad awareness exists of the shortcomings of standard pretreatment metastases evaluation, typically involving bone scintigraphy and abdominal pelvic CT/MRI [26]. Improvement in detecting metastases has recently been reported using whole-body MRI and ^{11}C -choline PET/CT [27,28], and may offer better pretreatment evaluation in the future.

The best biopsy strategy for patient selection for focal therapy is still controversial. A transperineal template-guided mapping biopsy of the prostate (TTMB) appears to provide more detailed information about cancer grade and localisation compared with a standard 12-core biopsy schema [29]. The principal drawback of TTMB remains in its invasive approach, high cost, and complexity, which is directly divergence to the mini-invasive concept of focal therapy. In addition, due to prostate movement, organ swelling and biopsy needle deflection during the procedure, biopsy needle placement does not necessary correspond to the localisation suggested by a grid.

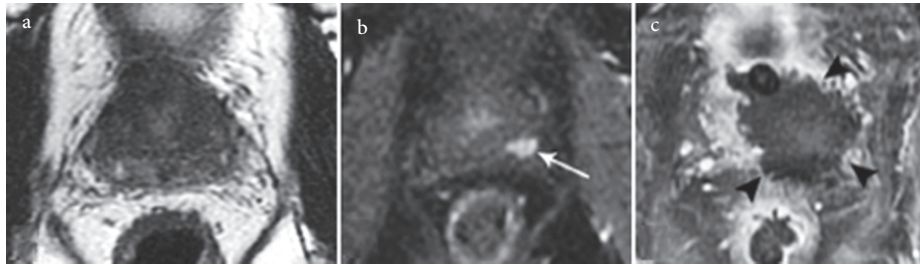
In recent years, numerous studies have shown an increasing agreement between MRI and RP specimen results for determining anatomical location and extent of disease, especially if the tumour volume is >0.5 mL or Gleason grade ≥ 4 . However, MRI still has limitations in the detection of small and multiple cancer foci [30,31].

Recent advances in the three-dimensional (3D) registration of the biopsy based on organ tracking using MRI/TRUS real-time elastic-fusion techniques may provide more objective tumour mapping than the traditional biopsy technique [32]. We think that the future progress in imaging and computerised biopsy procedures may further improve patient selection for focal therapy and compensating for the disadvantages of TTBM.

Moreover, prostate MRI has yielded encouraging results in detecting and localising recurrence after EBRT and is systematically used in both patient selection and treatment guidance at our institutions (Fig. 2) [11,12].

Evaluation of 50 salvage prostatectomies by Leibovici et al. [33], found that 66% of patients had a solitary cancer focus, and that 74% had tumour extension beyond the urethra. Therefore, it appears important to perform an 'extended' hemi-ablation involving the contralateral lobe without the intention of urethral preservation. Furthermore, early

Fig. 2 MRI obtained in a 79-year-old man with a history of RT (78 Gy) for prostate cancer (Gleason score 6) 9 years earlier. The PSA nadir was 0.3 ng/mL, and the last PSA value was 3.05 ng/mL. **(a)** Axial T2w sequence shows a diffuse hypointense prostate with loss of zonal anatomy. **(b)** Axial DCE sequence shows an early enhancing nodule in the left basis. Targeted biopsy and histology presented a Gleason 8 radiorecurrent cancer, while random biopsies all were negative. The patient underwent HSH. **(c)** Axial gadolinium-enhanced fat saturated T1 sequence 3 days after HSH shows devascularization of the left prostate lobe (arrowheads).



detection of radiorecurrent cancer, while the cancer is still amenable to focal therapy, is mandatory.

In the present study, nadir PSA values achieved after HSH were somewhat higher than those reported with whole-gland HIFU treatment. The largest series published to date on salvage HIFU therapy is by Crouzet *et al.* [8] with 290 patients and a mean 48-month follow-up. They reported a 0.14 ng/mL median nadir PSA after whole-gland treatment, and actuarial cancer-specific and metastases-free survivals of 80% and 79%, respectively. These rates correspond with those reported by Chade *et al.* [7] in a study of 404 patients treated with salvage RP. Their actuarial rates of cancer-specific and metastases-free survival were 83% and 77%.

After focal salvage HIFU, Ahmed *et al.* [6] reported an actuarial PFS rate of 49% at 2 years (Phoenix criteria), with 16 patients (41%) undergoing palliative hormone therapy by final follow-up. The biochemical survival outcomes reported in the Ahmed *et al.* study were comparable to the PFS rates in the present study, achieved with hemi-ablation, of 52% at 2-year follow-up.

The morbidity prevalence in the present study was lower than those reported for standard salvage treatments. Nguyen *et al.* [34] evaluated the outcome of salvage RP in 531 patients and found an incontinence rate of 41%, an anastomotic stenosis rate of 24% and a 4.7% rate of urethrorectal fistula. In a more recent series of salvage RP, a 20% rate of severe incontinence and a 1% rate of urethrorectal fistula were reported [35]. Salvage cryotherapy was evaluated in 510 patients by Nguyen *et al.* [34], who found severe incontinence in 36%, bladder neck stricture in 17%, and urethrorectal fistula in 2.6%. In a series of 84 patients treated with salvage HIFU, Ahmed *et al.* [36] reported incontinence in 38%, strictures requiring endoscopic intervention in 20%, and urethrorectal fistula in 2.4%. In a series published by Crouzet *et al.* [37], HIFU morbidity for radiorecurrent cancer was significantly reduced using dedicated acoustic parameters, with severe incontinence in 19.5% and urethrorectal fistula in 0.4%. Similarly, Berge

et al. [38] used the same acoustic parameters for whole-gland salvage therapy, and reported severe urinary incontinence in 17.2%.

The preservation of both urinary function and health-related quality of life at pre-treatment levels (Table 4) in the present study is in contrast to the results of whole-gland salvage HIFU reported in a study by Berge *et al.* [39] conducted with a comparable patient cohort, clinical characteristics and follow-up.

Periprostatic irradiation may result in tissue alteration that intensifies with time and increases the risk of late morbidity [40]. In the present study, one patient had delayed pubic osteitis, possibly attributable in an endoscopic procedure performed 6 months after HSH. The bone infection healed after prolonged bladder drainage and antibiotics. Another patient with diabetes, had >2 months untreated urinary infection and urinary obstruction resulting in suprapubic pain. MRI revealed a pubovesical fistula occurring 23 months after HSH. The patient initially had been treated with transurethral bladder drainage and antibiotics. At 3 months MRI showed fistula healing. However, the subsequent MRI control after 6 months verified pubovesical fistula recurrence and the patient underwent cysto-prostatectomy and urinary deviation. Histopathological findings on whole-mount sectioned prostate gland were negative for cancer both in the HIFU-treated and untreated prostate lobe. Recently published results of pubovesical fistula in patients previously treated by RT show the low success rate after conservative treatment [41].

Only a few published studies have reported on focal salvage therapy outcomes. In a series of 39 patients treated with focal salvage HIFU with a median 17-month follow-up, Ahmed *et al.* [6] reported morbidity outcomes that were similar to the present study, with perfect continence in 64%, but a significant reduction in the IIEF-5 score. A small series of 19 patients treated with focal salvage cryoablation reported complications that included incontinence, urethral strictures or ulcer [24].

Table 5 Functional outcomes and side-effects after whole-gland and focal salvage treatments by HIFU and cryoablation as reported in the literature.

Reference	Salvage treatment	Patients, n	Study type	Centres	Follow-up, months median (range) or mean (SD)	Follow-up rate, %	Incontinence requiring pad at last follow-up, %	Incontinence grade III, %	IPSS score		IIEF score		HRQL score		Rectal fistula %	Pubic bone osteitis, n (%)
									Before	After	Before	After	Before	After		
Pisters et al. (2008) [42]	Wg cryo	279	R	multi	21.69 (24.9)	-	4.4	-	-	-	-	-	-	-	-	-
Murat et al. (2009) [10]	Wg HIFU	167	R	1	18.1 (3-121)	-	49.5	9.5	-	-	-	-	-	-	3	-
Williams et al. (2011) [43]	Wg cryo	176	R	1	90 (12-168)	94	40	3	-	-	-	-	-	-	2	-
Crouzet et al. (2012) [8]	Wg HIFU	290	P	1	48 (-)	-	50	9	-	-	-	-	-	-	2	8/290 (2.7)
Ahmed et al. (2012) [36]	Wg HIFU	84	R	2	19.8 (3-35.1)	-	38	-	8.3	11.6	6.2 [§]	100.2 [*]	100.4 [*]	2.4	1/84 (1.2)	-
Eisenberg and Shiroaha (2008) [24]	Focal cryo	19	R	1	18 (6-33)	79	5	0	-	-	-	-	-	0	-	-
Wenske et al. (2013) [44]	Focal cryo	44	R	1	37 (2-173)	-	0	0	-	-	-	-	-	-	5.5	-
Ahmed et al. (2012) [6]	Focal HIFU	39	R	1	17 (10-29)**	-	12.8	-	10	13	18 [§]	13 [‡]	-	-	2.5	-
de Castro Abreu et al. (2013) [25]	Focal cryo	25	R	1	31 (4-90)	100	0	0	-	-	-	-	-	0	-	-
Present study	HSH	48	P	2	16.3 (10.5-23.5)**	100	25	8.3	7.1	8.6	11.2 [§]	7.0 [§]	35.7	36.8 [§]	0	2/48 (4)

HRQL, health-related quality of life; Wg, whole gland; cryo, cryoablation; R, retrospective study; P, prospective study; -, not reported on; **, interquartile range; [§]IIEF-5; [‡]IIEF-15; *Rand short form 36-36-Item Short Form Health Survey Questionnaire; [†]EQRTC QLC-30.

Encouraging functional outcomes after focal salvage cryotherapy have recently been described in a retrospective study conducted by Abreu *at al* [25], where there was no observed urinary incontinence after treatment. However, contrary to the present patient cohort, the authors did not clarify if patients with extreme apex cancer localisation have been included in the study or if the peri-sphincteric part of the prostate was treated with radical intent.

The trend towards better outcomes after focal treatment, as reported in largest published studies on salvage HIFU and cryotherapy, is shown in Table 5 [6,8,10,24,25,36,42-44]. The major limitations of all published studies are their retrospective character and limited control about follow-up rate.

It is known that the rate of post-treatment continence conservation depends on quantity of ablative energy applied to the apex region during treatment. Patients with apical tumour recurrence should be informed carefully of the risk of urinary leakage if radical salvage treatment is planned. Precise biopsy mapping of the apex using a 3D real-time navigation system and 3D-TRUS biopsy registration allow accurate apex staging. In patients with negative apex biopsy, apex-sparing salvage HIFU preserves urinary continence (Abstract # 55 presented by Baco et al. at the 4th International Symposium on Focal Therapy and Imaging in Prostate and Kidney Cancer, 2011, Noordwijk, Amsterdam, The Netherlands). Hopefully, promising results of MRI in detection and localisation of prostate cancer will be confirmed in upcoming studies and that safety margins can be tailored to the tumour position [45]. It is expected that the technological advance in therapeutic ultrasound, especially precise identification of the apex, adaptable height of HIFU lesions and perioperative temperature monitoring in treated and surrounding tissue will optimise the oncological and functional outcomes.

In conclusion, HSH in patients with unilateral radio recurrent prostate cancer results in fewer and less severe morbidity than whole-gland salvage therapies, and may preserve pre-treatment health-related quality of life. Accurate imaging and biopsy are essential to identify malignancy suitable for focal therapy and to exclude metastatic disease. Based on the present results, prospective multicentre clinical trials with long-term follow-up are warranted.

Conflict of Interest

Albert Gelet is investigator and consultant for Edap-TMS.

References

- 1 Bannuru RR, Dvorak T, Obadan N et al. Comparative evaluation of radiation treatments for clinically localized prostate cancer: an updated systematic review. *Ann Intern Med* 2011; 155: 171-8
- 2 Cooperberg MR, Vickers AJ, Broering JM, Carroll P. R, for the Cancer of the Prostate Strategic Urologic Research Endeavor (CaPSURE)

- Investigators. Comparative risk-adjusted mortality outcomes after primary surgery, radiotherapy, or androgen-deprivation therapy for localized prostate cancer. *Cancer* 2010; 116: 5226–34
- 3 Boorjian SA, Karnes RJ, Viterbo R et al. Long-term survival after radical prostatectomy versus external-beam radiotherapy for patients with high-risk prostate cancer. *Cancer* 2011; 117: 2883–91
 - 4 Beckendorf V, Guerif S, Le Prise E et al. 70 Gy versus 80 Gy in localized prostate cancer: 5-year results of GETUG 06 randomized trial. *Int J Radiat Oncol Biol Phys* 2010; 80: 1056–63
 - 5 Sylvester JE, Grimm PD, Wong J, Galbreath RW, Merrick G, Blasko JC. Fifteen-year biochemical relapse-free survival, cause-specific survival, and overall survival following I(125) prostate brachytherapy in clinically localized prostate cancer: Seattle experience. *Int J Radiat Oncol Biol Phys* 2011; 81: 376–81
 - 6 Ahmed HU, Cathcart P, McCartan N et al. Focal salvage therapy for localized prostate cancer recurrence after external beam radiotherapy. *Cancer* 2012; 118: 4148–55
 - 7 Chade DC, Eastham J, Graefen M et al. Cancer control and functional outcomes of salvage radical prostatectomy for radiation-recurrent prostate cancer: a systematic review of the literature. *Eur Urol* 2012; 61: 961–71
 - 8 Crouzet SB, Murat FJ, Pommier P et al. Locally recurrent prostate cancer after initial radiation therapy: early salvage high-intensity focused ultrasound improves oncologic outcomes. *Radiother Oncol* 2012; 105: 198–202
 - 9 Mouraviev V, Spiess PE, Jones JS. Salvage cryoablation for locally recurrent prostate cancer following primary radiotherapy. *Eur Urol* 2012; 61: 1204–11
 - 10 Murat FJ, Poissonnier L, Rabilloud M et al. Mid-term results demonstrate salvage high-intensity focused ultrasound (HIFU) as an effective and acceptably morbid salvage treatment option for locally radiorecurrent prostate cancer. *Eur Urol* 2009; 55: 640–7
 - 11 Rouviere O, Vitry T, Lyonnet D. Imaging of prostate cancer local recurrences: why and how? *Eur Radiol* 2010; 20: 1254–66
 - 12 Gelet A, Chapelon JY, Poissonnier L et al. Local recurrence of prostate cancer after external beam radiotherapy: early experience of salvage therapy using high-intensity focused ultrasonography. *Urology* 2004; 63: 625–9
 - 13 Rud E, Baco E, Eggesbø HB. MRI and ultrasound-guided prostate biopsy using soft image fusion. *Anticancer Res* 2012; 32: 3383–9
 - 14 D'Amico AV, Desjardin A, Chung A et al. Assessment of outcome prediction models for patients with localized prostate carcinoma managed with radical prostatectomy or external beam radiation therapy. *Cancer* 1998; 82: 1887–96
 - 15 Ingelman-Sundberg A, Ulmsten U. Surgical treatment of female urinary stress incontinence. *Contrib Gynecol Obstet* 1983; 10: 51–69
 - 16 Abrams P, Cardozo L, Fall M et al. The standardisation of terminology of lower urinary tract function: report from the standardisation sub-committee of the international continence society. *Am J Obstet Gynecol* 2002; 187: 116–26
 - 17 Rosen RC, Riley A, Wagner G, Osterloh IH, Kirkpatrick J, Mishra A. The international index of erectile function (IIEF): a multidimensional scale for assessment of erectile dysfunction. *Urology* 1997; 49: 822–30
 - 18 Aaronson NK, Ahmedzai S, Bergman B et al. The European Organization for Research and Treatment of Cancer QLQ-C30: a quality-of-life instrument for use in international clinical trials in oncology. *J Natl Cancer Inst* 1993; 85: 365–76
 - 19 Rouviere O, Lyonnet D, Raudrant A et al. MRI appearance of prostate following transrectal HIFU ablation of localized cancer. *Eur Urol* 2001; 40: 265–74
 - 20 Tamada T, Sone T, Jo Y et al. Locally recurrent prostate cancer after high-dose-rate brachytherapy: the value of diffusion-weighted imaging, dynamic contrast-enhanced MRI, and T2-weighted imaging in localizing tumors. *AJR Am J Roentgenol* 2011; 197: 408–14
 - 21 Kim CK, Park BK, Lee HM. Prediction of locally recurrent prostate cancer after radiation therapy: incremental value of 3T diffusion-weighted MRI. *J Magn Reson Imaging* 2009; 29: 391–7
 - 22 Morgan VA, Riches SF, Giles S, Dearnaley D, deSouza NM. Diffusion-weighted MRI for locally recurrent prostate cancer after external beam radiotherapy. *AJR Am J Roentgenol* 2012; 198: 596–602
 - 23 Bratan F, Niaf E, Melodelima C et al. Influence of imaging and histological factors on prostate cancer detection and localisation on multiparametric MRI: a prospective study. *Eur Radiol* 2013; 23: 2019–29
 - 24 Eisenberg ML, Shinohara K. Partial salvage cryoablation of the prostate for recurrent prostate cancer after radiotherapy failure. *Urology* 2008; 72: 1315–8
 - 25 de Castro Abreu AL, Bahn D, Leslie S et al. Salvage focal and salvage total cryoablation for locally recurrent prostate cancer after primary radiation therapy. *BJU Int* 2013; 112: 298–307
 - 26 Choueiri TK, Dreicer R, Paciorek A, Carroll PR, Konety B. A model that predicts the probability of positive imaging in prostate cancer cases with biochemical failure after initial definitive local therapy. *J Urol* 2008; 179: 906–10
 - 27 Kwee TC, Takahara T, Ochiai R, Nieuwstein RA, Luijten PR. Diffusion-weighted whole-body imaging with background body signal suppression (DWIBS): features and potential applications in oncology. *Eur Radiol* 2008; 18: 1937–52
 - 28 Mitchell CR, Lowe VJ, Rangel LJ, Hung JC, Kwon ED, Karnes RJ. Operational characteristics of (11)c-choline positron emission tomography/computerized tomography for prostate cancer with biochemical recurrence after initial treatment. *J Urol* 2013; 189: 1308–13
 - 29 Bittner N, Merrick GS, Bennett A et al. Diagnostic Performance of Initial Transperineal Template-guided Mapping Biopsy of the Prostate Gland. *Am J Clin Oncol* 2013; in press. doi: 10.1097/COC.0b013e31829a2954 [Epub ahead of print]
 - 30 Villers A, Puech P, Mouton D, Leroy X, Ballereau C, Lemaitre L. Dynamic contrast enhanced, pelvic phased array magnetic resonance imaging of localized prostate cancer for predicting tumor volume: correlation with radical prostatectomy findings. *J Urol* 2006; 176: 2432–7
 - 31 Haffner J, Lemaitre L, Puech P et al. Role of magnetic resonance imaging before initial biopsy: comparison of magnetic resonance imaging-targeted and systematic biopsy for significant prostate cancer detection. *BJU Int* 2011; 108: E171–8
 - 32 Ukimura O, Gill IS. Targeted prostate biopsies for a histogram of the index lesion. *Curr Opin Urol* 2013; 23: 118–22
 - 33 Leibovici D, Chiong E, Pisters LL et al. Pathological characteristics of prostate cancer recurrence after radiation therapy: implications for focal salvage therapy. *J Urol* 2012; 188: 98–102
 - 34 Nguyen PL, D'Amico AV, Lee AK, Suh WW. Patient selection, cancer control, and complications after salvage local therapy for post-radiation prostate-specific antigen failure: a systematic review of the literature. *Cancer* 2007; 110: 1417–28
 - 35 Heidenreich A, Richter S, Thuer D, Pfister D. Prognostic parameters, complications, and oncologic and functional outcome of salvage radical prostatectomy for locally recurrent prostate cancer after 21st-century radiotherapy. *Eur Urol* 2010; 57: 437–43
 - 36 Uddin Ahmed H, Cathcart P, Chalasani V et al. Whole-gland salvage high-intensity focused ultrasound therapy for localized prostate cancer recurrence after external beam radiation therapy. *Cancer* 2011; 118: 3071–8
 - 37 Crouzet S, Poissonnier L, Murat FJ et al. Outcomes of HIFU for localised prostate cancer using the Ablatherm Integrate Imaging(R) device. *Prog Urol* 2011; 21: 191–7

- 38 Berge V, Baco E, Karlsen SJ. A prospective study of salvage high-intensity focused ultrasound for locally radiorecurrent prostate cancer: early results. *Scand J Urol Nephrol* 2010; 44: 223–7
- 39 Berge V, Baco E, Dahl AA, Karlsen SJ. Health-related quality of life after salvage high-intensity focused ultrasound (HIFU) treatment for locally radiorecurrent prostate cancer. *Int J Urol* 2011; 18: 646–51
- 40 Marks LB, Carroll PR, Dugan TC, Anscher MS. The response of the urinary bladder, urethra, and ureter to radiation and chemotherapy. *Int J Radiat Oncol Biol Phys* 1995; 31: 1257–80
- 41 Matsushita K, Ginsburg L, Mian BM et al. Pubovesical fistula: a rare complication after treatment of prostate cancer. *Urology* 2012; 80: 446–51
- 42 Pisters LL, Rewcastle JC, Donnelly BJ, Lugnani FM, Katz AE, Jones JS. Salvage Prostate Cryoablation: initial Results From the Cryo On-Line Data Registry. *J Urol* 2008; 180: 559–64
- 43 Williams AK, Martínez CH, Lu C, Ng CK, Pautler SE, Chin JL. Disease-free survival following salvage cryotherapy for biopsy-proven radio-recurrent prostate cancer. *Eur Urol* 2011; 60: 405–10
- 44 Wenske S, Quarrier S, Katz AE. Salvage cryosurgery of the prostate for failure after primary radiotherapy or cryosurgery: long-term clinical, functional, and oncologic outcomes in a large cohort at a tertiary referral centre. *Eur Urol* 2013; 64: 1–7
- 45 Boutier R, Girouin N, Cheikh AB et al. Location of residual cancer after transrectal high-intensity focused ultrasound ablation for clinically localized prostate cancer. *BJU Int* 2011; 108: 1776–81

Correspondence: Eduard Baco, Department of Urology, Oslo University Hospital, Aker Trondheimsveien 254, Oslo 0514, Norway.

e-mail: eduard.baco@medisin.uio.no

Abbreviations: ADC, apparent diffusion coefficient; ADT, androgen-deprivation therapy; BCR, biochemical recurrence; BT, brachytherapy; DCE, dynamic contrast-enhanced; DWI, diffusion-weighted images; EORTC, European Organisation for the Research and Treatment of Cancer; HIFU, high-intensity focused ultrasound; IIEF-5, International Index of Erectile Function-5; PET, positron emission tomography; PFS, progression-free survival; RP, radical prostatectomy; (EB)RT, (external beam) radiotherapy; 3D, three-dimensional; T2w, T2-weighted; TTMB, template-guided mapping biopsy of the prostate.

available at www.sciencedirect.com
journal homepage: www.europeanurology.com



European Association of Urology



Platinum Priority – Prostate Cancer

Editorial by XXX on pp. x–y of this issue

Whole-gland Ablation of Localized Prostate Cancer with High-intensity Focused Ultrasound: Oncologic Outcomes and Morbidity in 1002 Patients

Sebastien Crouzet^{a,b,*}, Jean Yves Chapelon^b, Olivier Rouvière^c, Florence Mege-Lechevallier^d, Marc Colombel^a, H el ene Tonoli-Catez^a, Xavier Martin^a, Albert Gelet^{a,b}

^a Hospices Civils de Lyon, Department of Urology and Transplantation Surgery, Edouard Herriot Hospital, Lyon, France; ^b Inserm, U1032, LabTau, Universit e de Lyon, Lyon, France; ^c Hospices Civils de Lyon, Radiology Department, Edouard Herriot Hospital, Lyon, France; ^d Hospices Civils de Lyon, Pathology Department, Edouard Herriot Hospital, Lyon, France

Article info

Article history:

Accepted April 20, 2013
Published online ahead of print on April 30, 2013

Keywords:

High-intensity focused ultrasound ablation
Localized prostate cancer
Survival rate
Disease-free survival

Abstract

Background: High-intensity focused ultrasound (HIFU) is a nonsurgical therapy for selected patients with localized prostate cancer (PCa).

Objective: The long-term oncologic and morbidity outcomes of primary HIFU therapy for localized PCa were evaluated in a prospective, single-arm, single-institution cohort study.

Design, setting, and participants: Participants were patients treated with HIFU for localized PCa from 1997 to 2009. Excluded were patients with local recurrence following radiotherapy. A second HIFU session was systematically performed in patients with biopsy-proven local recurrence.

Intervention: Whole-gland prostate ablation with transrectal HIFU.

Outcome measurements and statistical analysis: Incontinence was assessed using the Ingelman-Sundberg score, and potency was assessed using the five-item version of the International Index of Erectile Function (IIEF-5) scores. Primary outcomes were survival rates (biochemical-free, cancer-specific, metastasis-free, and overall survival). Secondary outcomes were morbidity rates. Median follow-up was 6.4 yr (range: 0.2–13.9). The Kaplan-Meier method was used to determine survival estimates, and multivariate analysis was used to determine predictive factors of biochemical progression.

Results and limitations: A total of 1002 patients were included. The median nadir prostate-specific antigen (PSA) was 0.14 ng/ml, with 63% of patients reaching a nadir PSA \leq 0.3 ng/ml. Sixty percent of patients received one HIFU session, 38% received two sessions, and 2% received three sessions. The 8-yr biochemical-free survival rates (Phoenix definition) were 76%, 63%, and 57% for low-, intermediate-, and high-risk patients, respectively ($p < 0.001$). At 10 yr, the PCa-specific survival rate and metastasis-free survival rate (MFSR) were 97% and 94%, respectively. Salvage therapies included external-beam radiation therapy (EBRT) (13.8%), EBRT plus androgen-deprivation therapy (ADT) (9.7%), and ADT alone (12.1%). Severe incontinence and bladder outlet obstruction decreased with refinement in the technology, from 6.4% and 34.9% to 3.1% and 5.9%, respectively. Limitations included the fact that the study was a single-arm study without a comparison group, technological improvements, changes in surgical protocol during the study, and the use of ADT to downsize the prostate in 39% of patients.

Conclusions: HIFU is a potentially effective treatment of localized PCa, with a low PCa-specific mortality rate and a high MFSR at 10 yr as well as acceptable morbidity.

  2013 Published by Elsevier B.V. on behalf of European Association of Urology.

* Corresponding author. Urology and Transplantation Department, Edouard Herriot Hospital, 5 place d'Arsonval, 69437 Lyon Cedex 03, France. Tel. +33 472 119 191; Fax: +33 472 110 559. E-mail address: sebastien.crouzet@chu-lyon.fr (S. Crouzet).

1. Introduction

The objective of prostate cancer (PCa) treatment is the achievement of optimal cancer-specific survival rates with the lowest possible morbidity. High-intensity focused ultrasound (HIFU) is a nonsurgical treatment that uses nonionizing energy to induce irreversible damage to the malignant lesion through coagulation necrosis. Transrectal delivery of ultrasound under real-time monitoring forms the basis of HIFU. The thermal and cavitation effects can be repeated with subsequent treatment administration, and salvage external-beam radiation therapy (EBRT) is a therapeutic option in cases of local relapse following HIFU [1]. Since 1993, HIFU has been evaluated in our department as a minimally invasive option for the treatment of localized PCa in nonsurgical candidates [2]. Long-term oncologic results for HIFU are sparse in the literature, and HIFU is still considered investigational in the European Association of Urology guidelines [3,4]. The goals of the current study were to report the cancer control and morbidity outcomes for all patients treated with HIFU as primary therapy between January 1997 and December 2009 as well as to analyze factors that potentially influence treatment outcome.

2. Materials and methods

Following institutional review board approval, data from all treated patients were prospectively obtained and entered into a secure database (IRB: EB/MR92027/C, 200–032B, 2003–001B). Inclusion criteria were localized PCa, prostate-specific antigen (PSA) <30 ng/ml, clinical stage T1M0–T2M0, and no previous radical therapy for PCa. None of the patients were candidates for surgery because of age, comorbidity, or patient refusal. All patients were offered the treatment options of HIFU in a research protocol, EBRT, or active surveillance. Baseline and post-HIFU PSA measures were obtained for all patients.

2.1. Treatment protocol

All patients were treated with Ablatherm HIFU devices (EDAP-TMS, Vaulx-en-Verlain, France), including prototype devices (1997–1999), Ablatherm Maxis (1999–2000), and Ablatherm Integrated Imaging (since 2005). Starting in 2000, transurethral resection of the prostate (TURP) was performed immediately prior to the HIFU session, under the same anesthesia, in patients with prostate volume <30 ml. In patients with prostate volume >30 ml, two strategies were used: androgen-deprivation therapy (ADT) before 2005 and TURP performed 6 wk prior to HIFU beginning in 2006. Pre-HIFU TURP avoids the adverse effects induced by hormonal therapy and dramatically reduces catheter time and rate of urinary tract infection [5]. The most recent treatment parameters for initial HIFU therapy involved a 3-MHz nominal frequency, 6-s treatment pulse, and 4-s shot interval. Five operators performed the procedures.

2.2. Follow-up

Before June 2007, all patients underwent post-HIFU biopsy at 6 mo regardless of PSA level. After June 2007, post-HIFU biopsy was performed only in patients with a nadir PSA >0.3 ng/ml, according to the Ganzer et al. publication [6]. Based on the small post-HIFU prostate volume, a minimum of six biopsy cores were obtained. Additional follow-up biopsies were performed in cases of biochemical failure (American Society for Therapeutic Radiology and Oncology/Phoenix definition).

In cases of positive biopsy without evidence of metastasis, a second HIFU treatment was offered. Before 2005, some patients continuing to show positive biopsy who had little morbidity after the second session received a third HIFU session. Analysis of the initial repeat HIFU outcomes, including the elevated risk of rectourethral fistula, led to the introduction of specific parameters for HIFU retreatment in 2007.

2.3. Salvage treatment

Salvage therapy was performed after the last HIFU session in the event of biopsy-proven local recurrence and/or biochemical failure. ADT was used in patients without biopsy-proven local recurrence or with poor general health status, and salvage radiation therapy (SRT) alone or in combination with ADT was performed in patients with demonstrated local recurrence and long life expectancy.

2.4. Survival and morbidity evaluation

For disease-free rates, *biochemical failure* was defined using the Phoenix definition (nadir +2 ng/ml). All PCa-specific deaths were verified, and hormone-refractory metastatic PCa was documented by rising PSA level despite the use of second-line ADT and chemotherapy. Additional treatment-free survival was calculated by the initiation of salvage treatment as the date of failure. Palliative treatment-free survival was calculated by the initiation of definitive ADT. Incontinence was assessed using the Ingelman-Sundberg score [7], and potency was assessed using the five-item version of the International Index of Erectile Function (IIEF-5) scores between 12 and 24 mo after HIFU. All adverse effects, such as bladder outlet obstruction (BOO) (obstruction of the outflow of urine from necrotic debris or urethral stricture), were prospectively recorded. Only patients with complete data have been included in the final analysis (multivariate analysis, survival curves).

A statistical analysis was performed with SPSS v.20 (IBM Corp., Armonk, NY, USA). Survival curves were based on the Kaplan-Meier method, and the log-rank test was used for univariate comparisons. Actuarial survival rates were based on life table methods. For multivariable analysis, the Cox proportional hazards regression model was used.

3. Results

A total of 1002 patients met inclusion criteria. Patient demographics and baseline characteristics are summarized in Table 1. Median follow-up was 6.4 yr (0.2–13.9). HIFU was delivered by prototype model in 63 patients, Ablatherm Maxis in 652 patients, and Ablatherm Integrated Imaging in 287 patients. A total of 392 patients received pre-HIFU ADT for a median duration of 4.3 mo (range: 1–56) ($n = 278$ [71.0%] for ≤ 6 mo; $n = 114$ [29.0%] for > 6 mo). ADT was stopped after HIFU in all recipients. As only 63 patients (6.3%) did not receive pre-HIFU TURP, the effect of TURP on the oncologic results was not evaluable. The median number of HIFU sessions was one (range: one to three), with 596 patients (60%) receiving one session, 383 patients (38%) receiving two sessions, and 23 patients (2%) receiving three sessions. On average, 488 ± 122 shots were delivered, corresponding to a median treated volume of 30 ml (range: 3–60), which was 130% of the actual prostate volume size because of overlap in treatment zones.

Post-HIFU biopsies after the final HIFU treatment were available for 774 patients (77%). Results were negative in 485 patients (63%) and positive in 289 patients (37%).

Table 1 – Baseline characteristics of 1002 patients according to the three different high-intensity focused ultrasound devices

	Overall, n = 1002	Before 2000, n = 63	2000–2004, n = 652	2005–2009, n = 287	p value
Age, yr, median (range)	71 (48–87)	73 (56–87)	71 (48–85)	72 (52–84)	<0.001
PSA, ng/ml, median (range)	7.7 (0.0–30.0)	8.0 (0.0–26.3)	8.2 (0.0–30.0)	6.4 (0.0–30.0)	<0.001
Prostate volume, ml, median (range)	23.0 (5–78)	23.0 (8–62)	22.0 (5–78)	24.5 (6–48)	<0.001
Previous ADT, no. (%)					
No	610 (60.9)	55 (87.3)	362 (55.5)	193 (67.2)	
Yes	392 (39.1)	8 (12.7)	290 (44.5)	94 (32.8)	<0.001
Total, no.	1002	63	652	287	
Pre-HIFU Gleason score, no. (%)					
≤6	555 (55.4)	35 (55.6)	356 (54.6)	164 (57.1)	
7	348 (34.7)	10 (15.9)	235 (36.0)	103 (35.9)	
≥8	84 (8.4)	16 (25.4)	55 (8.4)	13 (4.5)	<0.001
Undefined	15 (1.5)	2 (3.2)	6 (0.9)	7 (2.4)	
Total, no.	1002	63	652	287	
Pre-HIFU PSA, no. (%)					
≤4	148 (14.8)	13 (20.6)	73 (11.2)	62 (21.6)	
4–10	569 (56.8)	24 (38.1)	373 (57.2)	172 (59.9)	
≥10	285 (28.4)	26 (41.3)	206 (31.6)	53 (18.5)	<0.001
Total, no.	1002	63	652	287	
Stage, no. (%)					
T1	518 (51.7)	31 (49.2)	328 (50.3)	159 (55.4)	
T2	449 (44.8)	29 (46.0)	303 (46.5)	117 (40.8)	
T3	28 (2.8)	3 (4.8)	20 (3.1)	5 (1.7)	0.014
Undefined	7 (0.7)	0 (0.0)	1 (0.2)	2 (2.1)	
Total, no.	1002	63	652	287	
D'Amico risk group, no. (%)					
Low	357 (35.6)	15 (23.8)	215 (33.0)	127 (44.3)	
Intermediate	452 (45.1)	23 (36.5)	308 (47.2)	121 (42.2)	
High	174 (17.4)	25 (39.7)	121 (18.6)	28 (9.8)	<0.001
Undefined	19 (1.9)	0 (0.0)	8 (1.2)	11 (3.8)	
Total, no.	1002	63	652	287	

PSA = prostate-specific antigen; ADT = androgen-deprivation therapy; HIFU = high-intensity focused ultrasound.

3.1. Biochemical survival

Nadir PSA was reached ≤6 mo after HIFU in all patients, at a median of 7.9 wk (range: 1–52) with a median nadir PSA of 0.14 ng/ml (range: 0–12.7). In all, 631 patients (63%) attained a nadir PSA ≤0.3 ng/ml, and 567 patients (56.6%) attained a nadir PSA ≤0.2 ng/ml. Table 2 compares the number of HIFU sessions and the nadir PSA values achieved with the different HIFU devices. Biochemical recurrence (Phoenix definition) was observed in 205 patients (21.2%). The 5- and 8-yr biochemical-free survival rates (BFSRs) for low-, intermediate-, and high-risk patients were 86–76%, 78–63%, and 68–57%, respectively ($p < 0.001$) (Fig. 1). The overall 10 yr BFSR was 60%. The 8-yr BFSRs in patients with and without previous ADT were 70% and 66%, respectively ($p = 0.992$). The 5-yr BFSR progressively increased over time: 66% in patients treated before 2000, 80% in patients treated from 2000 to 2004, and 83% in patients treated from 2005 onward ($p = 0.010$).

3.2. Survival rates

Eighty-nine patients (8.9%) died during follow-up from unrelated causes, 13 patients (1.3%) died from PCa, and metastatic PCa was detected in 40 patients (4.0%). The 10-yr overall survival rate and PCa-specific survival rate (PCSSR) was 80% and 97%, respectively (Fig. 2). PCSSR was 99% for low-risk

patients, 98% for intermediate-risk patients, and 92% for high-risk patients (Fig. 3). The 10-yr PCa metastasis-free survival rate (MFSR) was 94% (Fig. 2) and was 99%, 95%, and 86% for low-, intermediate-, and high-risk patients, respectively.

3.3. Predictive factors

In multivariable analysis (Table 3), clinical stage, PSA, pre-HIFU Gleason score, and number of HIFU sessions were

Table 2 – Number of high-intensity focused ultrasound (HIFU) sessions and prostate-specific antigen nadir after HIFU, according to the three different HIFU devices

	Before 2000, n = 63	2000–2004, n = 652	2005–2009, n = 287	p value
No. of HIFU sessions, no. (%)				
1	25 (39.7)	350 (53.7)	221 (77.0)	
2	28 (44.4)	289 (44.3)	66 (23.0)	<0.001
≥3	10 (15.9)	13 (2.0)	0 (0)	
Total, no.	63	652	287	
PSA nadir, ng/ml, no. (%)				
≤0.3	31 (49.2)	416 (63.8)	184 (64.1)	
0.3–1	14 (22.2)	120 (18.4)	56 (19.5)	0.232
>1	18 (28.6)	111 (17.0)	45 (15.7)	
Not determined	0 (0.0)	5 (0.8)	2 (0.7)	
Total, no.	63	652	287	

HIFU = high-intensity focused ultrasound; PSA = prostate-specific antigen.

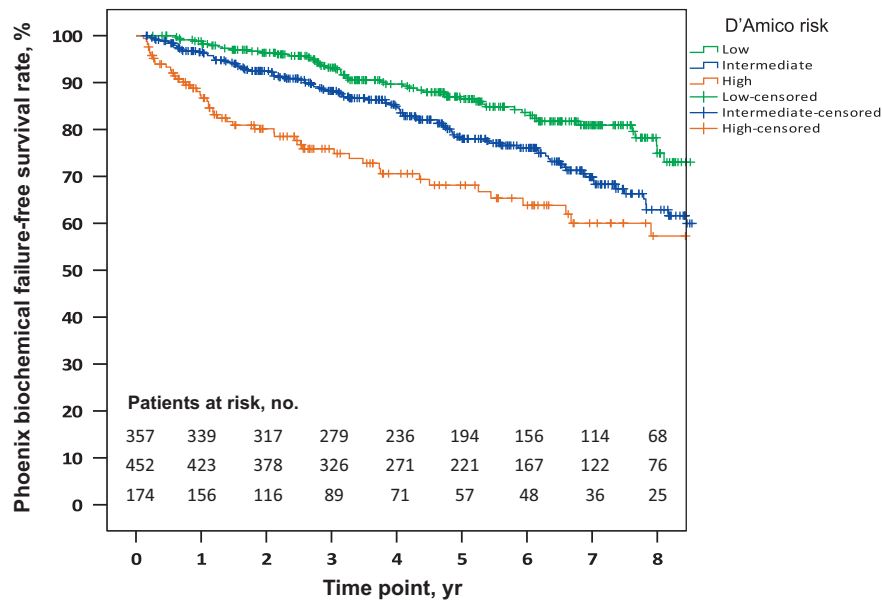


Fig. 1 – Influence of pre-high-intensity focused ultrasound (HIFU) risk group on biochemical-free survival rates (Phoenix criteria) following HIFU therapy.

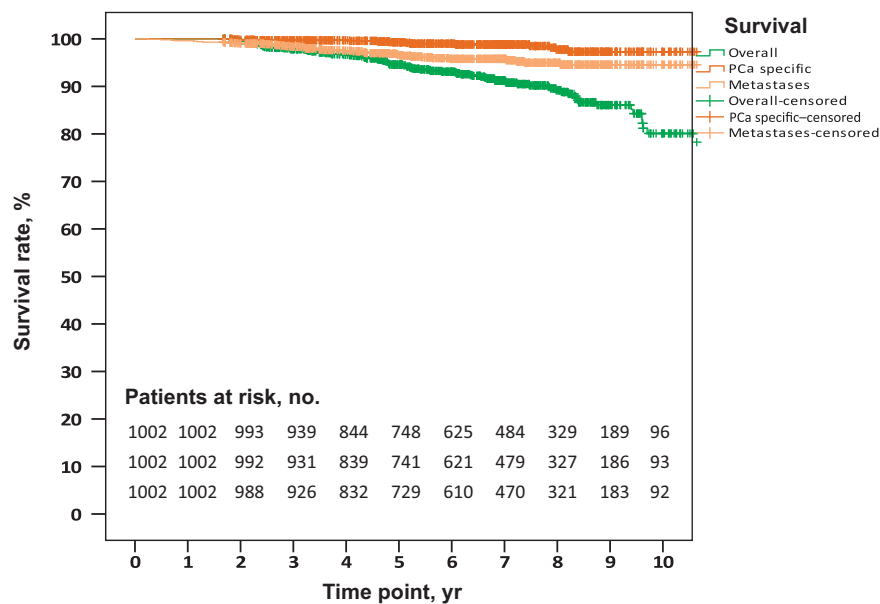


Fig. 2 – Overall, prostate cancer (PCa)-specific, and metastasis-free survival rates following high-intensity focused ultrasound (HIFU) treatment.

significantly associated with biochemical failure. The operator volume was not tested as a covariate in the multivariate analysis, because it has never been significant in previous studies. Nadir PSA was a significant predictive factor for biochemical failure. The 5- and 10-yr BFSRs were 88% and 75% with a nadir PSA ≤ 0.3 ng/ml, 72% and 32% with a nadir PSA 0.31–1.0 ng/ml, and 50% and 23% with a nadir PSA > 1.0 ng/ml, respectively ($p < 0.001$). Predictive factors for HIFU retreatment included PSA > 4 ng/ml, prostate volume > 25 ml, more than three of six positive biopsies, and the year of treatment (corresponding to device generation).

3.4. Salvage treatment

A total of 371 patients (37.1%) presenting with a rising PSA (Phoenix definition), with or without biopsy-proven recurrence, received salvage therapy, which included SRT alone (13.9%), SRT plus ADT and/or chemotherapy (10.7%), ADT alone (12.1%), and ADT plus chemotherapy (0.4%). The median time between the last HIFU session and SRT was 17 mo (range: 2–103), with a median dose of 72 Gy (range: 65–78). The 5- and 8-yr additional treatment-free survival rates for low-, intermediate-, and high-risk patients were 81% and 68%, 66% and 53%, and 47% and 38%, respectively

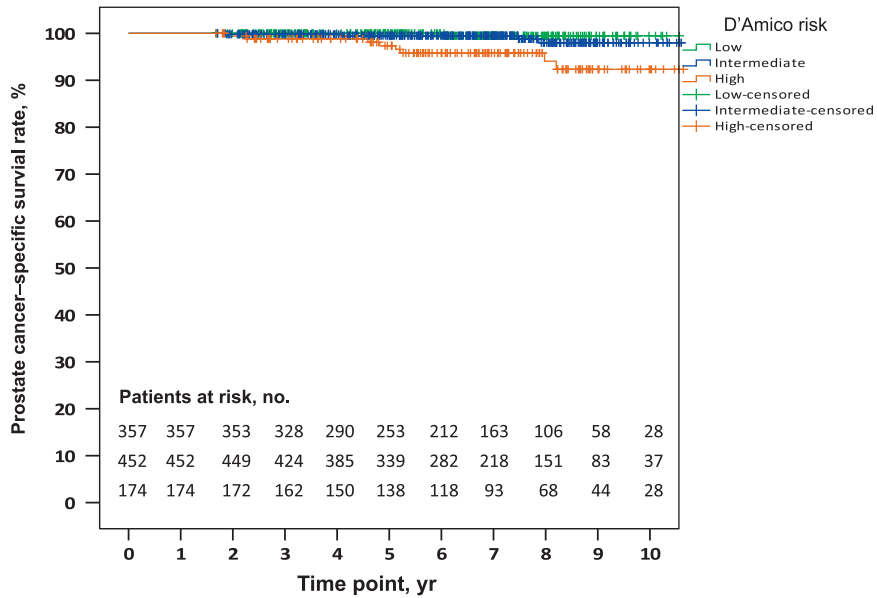


Fig. 3 – Influence of pre-high-intensity focused ultrasound (HIFU) risk group on prostate cancer-specific survival in patients treated following HIFU.

Table 3 – Prognostic factors of biochemical failure (Phoenix definition) in patients treated with high-intensity focused ultrasound: result of univariate and Cox analysis

Prognostic factors	Univariate p value	Univariate risk ratio	Univariate 95% CI	Multivariate p value	Multivariate risk ratio	Multivariate 95% CI
Age	0.018	1.03	1.01–1.06	0.641	1.01	0.98–1.03
Previous ADT	0.992	1.000	0.75–1.33	0.504	0.91	0.68–1.21
Stage						
T1	–	–	–	–	–	–
T2	0.022	1.39	1.05–1.84	0.057	1.32	0.99–1.77
T3	0.052	2.15	0.99–4.64	0.403	1.41	0.63–3.12
Gleason score						
≤6	–	–	–	–	–	–
7	0.014	1.46	1.08–1.97	0.050	1.36	1.00–1.84
≥8	<0.001	2.30	1.49–3.54	0.024	1.71	1.08–2.72
PSA, ng/ml						
≤4	–	–	–	–	–	–
4–10	0.008	2.13	1.21–3.73	0.007	2.17	1.24–3.82
>10	<0.001	4.94	2.81–8.68	<0.001	4.81	2.70–8.57
Prostate volume, ml						
≤25	–	–	–	–	–	–
>25	0.216	1.19	0.90–1.57	0.577	1.09	0.81–1.45
Positive biopsies						
≤2 of 6	–	–	–	–	–	–
3–4 of 6	0.285	1.21	0.85–1.72	0.438	1.16	0.80–1.67
≥5 of 6	0.778	0.96	0.96–1.32	0.703	1.07	0.75–1.55
No. of HIFU sessions						
1	–	–	–	–	–	–
≥2	0.005	0.66	0.50–0.88	0.001	0.60	0.45–0.81
HIFU technology						
Before 2005	–	–	–	–	–	–
After 2005	0.781	0.95	0.66–0.95	0.771	1.07	0.70–1.62

CI = confidence interval; PSA = prostate-specific antigen; HIFU = high-intensity focused ultrasound; ADT = androgen-deprivation therapy.

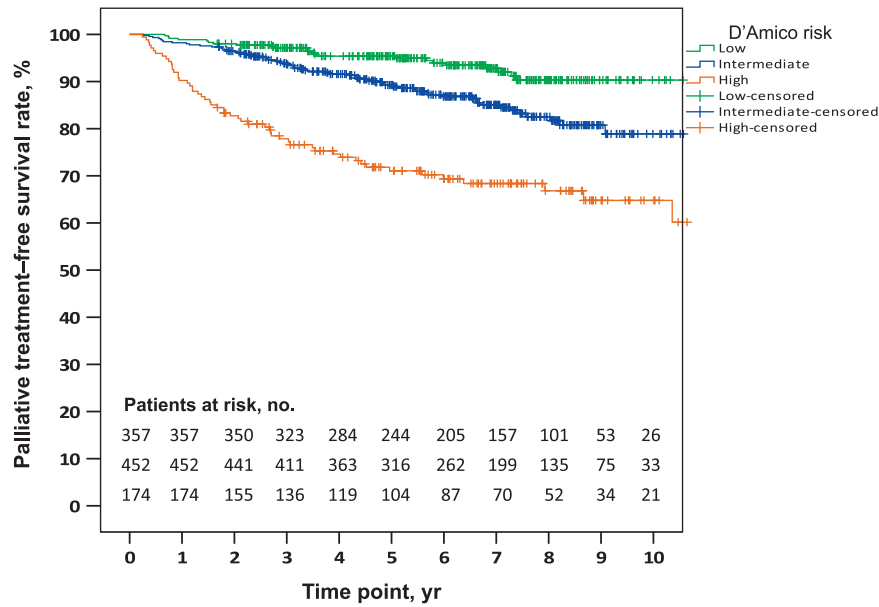


Fig. 4 – Influence of pre-high-intensity focused ultrasound (HIFU) risk group on palliative treatment-free survival following HIFU.

($p < 0.001$). No additional treatment was needed in 631 patients (63%). The median nadir PSA value after SRT was 0.09 ng/ml. Estimated with the Bolla et al. criteria [8], the 6-yr BFSR was 83% for the population receiving SRT and was 97%, 89%, and 63% for low-, intermediate-, and high-risk patients, respectively ($p = 0.003$). At 8 yr, the rates of patients requiring palliative ADT were 10%, 18%, and 34% of patients in the low-, intermediate-, and high-risk groups, respectively ($p < 0.001$) (Fig. 4).

3.5. Morbidity

Morbidity rates are summarized in Table 4. Baseline incontinence rates included grade 1 in 0.7% of patients and grades 2/3 in 0% of patients. Technological improvements in the HIFU device resulted in decreasing rates of grade

2/3 incontinence (from 6.4% to 3.1%, $p = 0.088$) and BOO (from 34.9% to 5.9%, $p = 0.032$). Incontinence was managed conservatively with physiotherapy (94.5%), artificial urinary sphincters (3.4%), and suburethral slings (2.1%). Bladder neck/urethral strictures were resolved with cold knife incision or TURP. Three patients required a definitive urethral stent for severe recurrent strictures, two of which occurred following SRT. Potency was evaluated in 187 patients treated after 2005 with the latest generation of device. The median IIEF-5 score decreased from 17 (range: 5–25) to 5 (range: 1–22) ($p < 0.001$). Potency was preserved (IIEF ≥ 17) in the 42.3% of patients with a baseline IIEF score ≥ 17 (<70 yr: 55.6%; ≥ 70 yr: 25.6%; $p < 0.001$) without pharmacologic aid.

Rectourethral fistula occurred in four patients (0.4%) following repeat HIFU treatment. Of those patients, three had severe comorbidity (one patient each with renal failure

Table 4 – Overall morbidity and morbidity with technological improvements

	Overall, $n = 1002$		Ablatherm technology			
			Before 2000, $n = 63$	2000–2004, $n = 652$	2005–2009, $n = 287$	p value
Early complications, no. (%)						
Urinary incontinence						
Stress 1	187 (18.7)	15 (23.8)	130 (19.9)	42 (14.6)	0.088	
Stress 2 or 3	50 (5.0)	4 (6.4)	37 (5.7)	9 (3.1)	0.226	
Urinary tract infection	39 (3.9)	11 (17.5)	19 (2.9)	9 (3.1)	<0.001	
Acute urinary retention	76 (7.6)	7 (11.1)	52 (8.0)	17 (5.9)	0.303	
Bladder outlet obstruction	166 (16.6)	29 (46.0)	103 (15.8)	34 (11.8)	<0.001	
Hematuria/sloughing	55 (5.5)	0 (0.0)	37 (5.7)	18 (6.3)	0.133	
Late complications, no. (%)						
Stenosis	90 (9.0)	22 (34.9)	51 (7.8)	17 (5.9)	<0.001	
Fistula	4 (0.4)	0 (0.0)	2 (0.3)	2 (0.7)	0.597	

and hemodialysis, acquired immunodeficiency syndrome (AIDS), and previous radiation therapy for bladder transitional urothelial carcinoma). Different treatments were applied: one York-Mason procedure, two colostomies alone (one anuric patient under hemodialysis and one patient with bladder cancer), and one gracilis muscle interposition. No de novo fecal incontinence was observed.

4. Discussion

The cancer control effectiveness of any treatment approach for PCa is influenced by three factors: efficacy as primary therapy, early detection of relapse, and feasibility and efficacy of curative salvage options.

The BFSR with HIFU seems promising in our study and is comparable to the published rates from other HIFU series [9,10]. In the GETUG 06 randomized trial, the 5-yr BFSR was 68% in the 70-Gy arm and 76.5% in the 80-Gy arm ($p = 0.09$) [11], although direct comparison between HIFU and EBRT is possible only with prospective studies or matched-pair analyses. Similar to EBRT, the BFSR with HIFU was significantly influenced by D'Amico risk category [12]. Nadir PSA was also a significant predictive factor of HIFU outcome [6]. The prostate volume was a significant predictor for HIFU retreatment. Blana et al. found a 79% BFSR at 7 yr with total-prostate HIFU (prostate height ≤ 24 mm and treated volume $>120\%$ of prostate volume) [10]. No difference in BFSR was observed in relation to previous ADT exposure, and in this study (unlike EBRT), no synergistic effect between ADT and HIFU was observed. Potentially, stage migration over time might have contributed to the increase in BFSR.

Local relapse was identified in 27% of the current cohort. Positive biopsy rates following conformal EBRT have ranged from 21% to 32% [13,14], and the local recurrence rate 10 yr after radical surgery was 89% (positive margin) and 95% (negative margin) [15].

The early biochemical response following HIFU allows a more rapid identification of local relapse through magnetic resonance imaging and ultrasound imaging using a contrast agent generally located in the apex and anterior regions of the prostate [16,17]. With the application of specific retreatment parameters, repeat HIFU is usually offered to patients with biopsy-proven local recurrence who have not experienced significant morbidity from previous HIFU sessions. HIFU therapy leaves an option for salvage EBRT that is effective and well tolerated, even at the mean dose of >70 Gy used in our study [1].

Recent reports of radical prostatectomy (RP) found a 12-yr PCa-specific mortality (PCSM) rate of 12.5% and a 10-yr PCSM rate of 0.9%, 4%, and 8% in low-, intermediate-, and high-risk patients, respectively [18,19]. The metastatic survival rate 12 yr after RP was found to be 80.7% by Bill-Axelsson et al. [18], while Zelefsky et al. found an 8-yr rate of 97% in a comparative nonrandomized study [20]. The 8-yr metastatic survival rate after EBRT (>81 Gy) was found to be 93% [7]. A high radiation dose level significantly reduces the 10-yr risk of metastases, with survival rates of 81% found using ≤ 80 Gy compared with 87% for doses >81 Gy ($p < 0.001$) [21]. The PCSM rate 15 yr after iodine 125 brachytherapy was found to

be 16% [22]. The 10-yr PCSM rate was 2.8% with RP, compared with 5.8% with observation in a matched cohort study of 22 244 patients [23].

The rate of rectal injury in the current study was low (0.4%), and in contrast to EBRT and brachytherapy, HIFU does not result in late-onset gastrointestinal (GI) toxicity. The GI bleeding rates were 9.3 of 1000 patients with three-dimensional EBRT, 8.9 of 1000 patients with intensity-modulated radiation therapy, 5.3 of 1000 patients with brachytherapy, and 20.1 of 1000 patients with proton therapy [24].

We found decreasing rates of incontinence with technological improvements. Following radical robot-assisted laparoscopic prostatectomy (RALP), the objective continence rate was 80% at 24 mo, based on the University of California, Los Angeles, Prostate Cancer Index questionnaire in 380 patients [25].

The rate of BOO has decreased since the introduction of real-time monitoring. Rates of BOO found with other therapies include 1.4% with open RP and 2.6% with RALP [26]. The stricture incidence rates were 1.8%, 1.7%, and 5.2% in patients treated with brachytherapy, EBRT, and combined EBRT and brachytherapy, respectively [27].

Potency was preserved in 52.6% of younger potent patients. Following RALP, the objective potency rate at 12 mo was reported as 62% [25]. In 139 potent patients receiving EBRT (78 Gy), the incidence of new-onset erectile dysfunction at 2 yr was 38% [28]. After brachytherapy, an adequate erectile function at 5 yr was found in 61.5% of previously potent patients [29], while only 24% of patients retained full potency 24 mo after cryosurgery [30].

This prospective study of HIFU is the largest published to date with 10-yr Kaplan-Meier estimated survival rates.

We acknowledge the following limitations. The study was a single-arm study without a comparison group. In addition, technological improvements and changes in surgical protocol (TURP) may have confounded some of the outcome analyses. The study used ADT to downsize the prostate with a potential bias in survival analyses, although it was not a significant predictor of survival in the Cox analyses. The study also used the Ingelman-Sundberg score originally developed for use in women with stress urinary incontinence rather than men. Incontinence evaluation was performed between 12 and 24 mo. Morbidity data were not categorized with a standardized reporting system. Finally, differences in selection criteria, study design, use of adjuvant/salvage treatments, and definition of functional outcomes among the published results of other PCa therapy modalities make direct comparisons difficult.

5. Conclusions

HIFU is a minimally invasive therapeutic option with encouraging cancer-specific survival rates in patients with localized PCa. The 10-yr PCSMs and MFSRs were low, and the morbidity was acceptable. Salvage EBRT for post-HIFU relapse was feasible, and the rate of patients requiring palliative ADT was low.

Author contributions: Sebastien Crouzet had full access to all the data in the study and takes responsibility for the integrity of the data and the accuracy of the data analysis.

Study concept and design: Gelet, Crouzet.

Acquisition of data: Gelet, Crouzet, Mege-Lechevallier, Tonoli-Catez.

Analysis and interpretation of data: Crouzet, Gelet, Rouviere.

Drafting of the manuscript: Crouzet, Gelet.

Critical revision of the manuscript for important intellectual content: Chapelon, Rouviere, Colombel.

Statistical analysis: Crouzet, Gelet, Chapelon.

Obtaining funding: None.

Administrative, technical, or material support: Mege-Lechevallier, Martin.

Supervision: Martin, Gelet.

Other (specify): None.

Financial disclosures: Sebastien Crouzet certifies that all conflicts of interest, including specific financial interests and relationships and affiliations relevant to the subject matter or materials discussed in the manuscript (eg, employment/ affiliation, grants or funding, consultancies, honoraria, stock ownership or options, expert testimony, royalties, or patents filed, received, or pending), are the following: Albert Gelet is a consultant for EDAP-TMS, Vaulx-en-Velin, France. Marc Colombel has consulted on educational programs on bladder cancer for Sanofi Pasteur.

Funding/Support and role of the sponsor: None.

References

- [1] Riviere J, Bernhard JC, Robert G, et al. Salvage radiotherapy after high-intensity focussed ultrasound for recurrent localised prostate cancer. *Eur Urol* 2010;58:567–73.
- [2] Poissonnier L, Chapelon JY, Rouviere O, et al. Control of prostate cancer by transrectal HIFU in 227 patients. *Eur Urol* 2007;51:381–7.
- [3] Heidenreich A, Bellmunt J, Bolla M, et al. EAU guidelines on prostate cancer, I: screening, diagnosis, and treatment of clinically localised disease. *Eur Urol* 2011;59:61–71.
- [4] Warmuth M, Johansson T, Mad P. Systematic review of the efficacy and safety of high-intensity focussed ultrasound for the primary and salvage treatment of prostate cancer. *Eur Urol* 2010;58:803–15.
- [5] Chaussy C, Thuroff S. The status of high-intensity focused ultrasound in the treatment of localized prostate cancer and the impact of a combined resection. *Curr Urol Rep* 2003;4:248–52.
- [6] Ganzer R, Rogenhofer S, Walter B, et al. PSA nadir is a significant predictor of treatment failure after high-intensity focussed ultrasound (HIFU) treatment of localised prostate cancer. *Eur Urol* 2008;53:547–53.
- [7] Ingelman-Sundberg A, Ulmsten U. Surgical treatment of female urinary stress incontinence. *Contrib Gynecol Obstet* 1983;10:51–69.
- [8] Bolla M, Collette L, Blank L, et al. Long-term results with immediate androgen suppression and external irradiation in patients with locally advanced prostate cancer (an EORTC study): a phase III randomised trial. *Lancet* 2002;360:103–6.
- [9] Uchida T, Shoji S, Nakano M, et al. Transrectal high-intensity focused ultrasound for the treatment of localized prostate cancer: eight-year experience. *Int J Urol* 2009;16:881–6.
- [10] Blana A, Robertson CN, Brown SC, et al. Complete high-intensity focused ultrasound in prostate cancer: outcome from the @-Registry. *Prostate Cancer Prostatic Dis* 2012;15:256–9.
- [11] Beckendorf V, Guerif S, Le Prise E, et al. 70 Gy versus 80 Gy in localized prostate cancer: 5-year results of GETUG 06 randomized trial. *Int J Radiat Oncol Biol Phys* 2011;80:1056–63.
- [12] Crouzet S, Rebillard X, Chevallier D, et al. Multicentric oncologic outcomes of high-intensity focused ultrasound for localized prostate cancer in 803 patients. *Eur Urol* 2010;58:559–66.
- [13] Zelefsky MJ, Reuter VE, Fuks Z, Scardino P, Shippy A. Influence of local tumor control on distant metastases and cancer related mortality after external beam radiotherapy for prostate cancer. *J Urol* 2008;179:1368–73, discussion 1373.
- [14] Zapatero A, Mínguez R, Nieto S, Martín de Vidales C, García-Vicente F. Post-treatment prostate biopsies in the era of three-dimensional conformal radiotherapy: what can they teach us? *Eur Urol* 2009;55:902–10.
- [15] Boorjian SA, Karnes RJ, Crispen PL, et al. The impact of positive surgical margins on mortality following radical prostatectomy during the prostate specific antigen era. *J Urol* 2010;183:1003–9.
- [16] Rouviere O, Girouin N, Glas L, et al. Prostate cancer transrectal HIFU ablation: detection of local recurrences using T2-weighted and dynamic contrast-enhanced MRI. *Eur Radiol* 2010;20:48–55.
- [17] Rouviere O, Glas L, Girouin N, et al. Transrectal HIFU ablation of prostate cancer: assessment of tissue destruction with contrast-enhanced ultrasound. *Radiology* 2011;259:583–91.
- [18] Bill-Axelsson A, Holmberg L, Ruutu M, et al. Radical prostatectomy versus watchful waiting in early prostate cancer. *N Engl J Med* 2011;364:1708–17.
- [19] Stephenson AJ, Kattan MW, Eastham JA, et al. Prostate cancer-specific mortality after radical prostatectomy for patients treated in the prostate-specific antigen era. *J Clin Oncol* 2009;27:4300–5.
- [20] Zelefsky MJ, Eastham JA, Cronin AM, et al. Metastasis after radical prostatectomy or external beam radiotherapy for patients with clinically localized prostate cancer: a comparison of clinical cohorts adjusted for case mix. *J Clin Oncol* 2010;28:1508–13.
- [21] Zelefsky MJ, Pei X, Chou JF, et al. Dose escalation for prostate cancer radiotherapy: predictors of long-term biochemical tumor control and distant metastases-free survival outcomes. *Eur Urol* 2011;60:1133–9.
- [22] Sylvester JE, Grimm PD, Wong J, et al. Fifteen-year biochemical relapse-free survival, cause-specific survival, and overall survival following I(125) prostate brachytherapy in clinically localized prostate cancer: Seattle experience. *Int J Radiat Oncol Biol Phys* 2011;81:376–81.
- [23] Abdollah F, Sun M, Schmitges J, et al. Cancer-specific and other-cause mortality after radical prostatectomy versus observation in patients with prostate cancer: competing-risks analysis of a large North American population-based cohort. *Eur Urol* 2011;60:920–30.
- [24] Kim S, Shen S, Moore DF, et al. Late gastrointestinal toxicities following radiation therapy for prostate cancer. *Eur Urol* 2011;60:908–16.
- [25] Shikanov SA, Zorn KC, Zagaja GP, Shalhav AL. Trifecta outcomes after robotic-assisted laparoscopic prostatectomy. *Urology* 2009;74:619–23.
- [26] Breyer BN, Davis CB, Cowan JE, Kane CJ, Carroll PR. Incidence of bladder neck contracture after robot-assisted laparoscopic and open radical prostatectomy. *BJU Int* 2010;106:1734–8.
- [27] Elliott SP, Meng MV, Elkin EP, et al. Incidence of urethral stricture after primary treatment for prostate cancer: data from CaPSURE. *J Urol* 2007;178:529–34, discussion 534.
- [28] van der Wielen GJ, van Putten WL, Incrocci L. Sexual function after three-dimensional conformal radiotherapy for prostate cancer: results from a dose-escalation trial. *Int J Radiat Oncol Biol Phys* 2007;68:479–84.
- [29] Stone NN, Stock RG. Long-term urinary, sexual, and rectal morbidity in patients treated with iodine-125 prostate brachytherapy followed up for a minimum of 5 years. *Urology* 2007;69:338–42.
- [30] Asterling S, Greene DR. Prospective evaluation of sexual function in patients receiving cryosurgery as a primary radical treatment for localized prostate cancer. *BJU Int* 2009;103:788–92.

Evolution and Outcomes of 3 MHz High Intensity Focused Ultrasound Therapy for Localized Prostate Cancer During 15 Years

Stefan Thüroff*,† and Christian Chaussy†

From Harlachinger Krebshilfe e.V. (ST, CC) and Department of Urology, Klinikum Harlaching (ST), Munich, and Department of Urology, University of Regensburg, Regensburg (CC), Germany

Abbreviations and Acronyms

ADT = androgen deprivation therapy
BDFS = biochemical disease-free survival
HIFU = high intensity focused ultrasound
PCa = prostate cancer
PSA = prostate specific antigen
RP = radical prostatectomy
TRUS = transrectal ultrasonography
TUR = transurethral resection
TURP = transurethral prostate resection

Accepted for publication February 6, 2013.

* Correspondence and requests for reprints: Department of Urology, Klinikum Harlaching, Sanatoriumsplatz 2, 81545 München, Germany (telephone: 49-89-6210-0; e-mail: sthueroff@mnet-mail.de).

† Financial interest and/or other relationship with EDAP TMS.

Editor's Note: This article is the fifth of 5 published in this issue for which category 1 CME credits can be earned. Instructions for obtaining credits are given with the questions on pages 818 and 819.

Purpose: We describe the long-term cancer control and morbidity of high intensity focused ultrasound with neoadjuvant transurethral resection of the prostate, the risk of metastatic induction by transurethral prostate resection, and the evolution of high intensity focused ultrasound application and technology with time.

Materials and Methods: A prospective Harlaching high intensity focused ultrasound database was searched for patients with primary localized prostate cancer (T1–2, N0, M0, PSA at first diagnosis less than 50 ng/ml) and followup longer than 15 months. Those patients with previous long-term androgen deprivation therapy, locally advanced prostate cancer or any therapy influencing prostate specific antigen were excluded from study. All patients were treated completely with an Ablatherm® high intensity focused ultrasound device. Evaluation was performed in aggregate, and by stratification according to cohort group, risk group (D'Amico criteria), prostate specific antigen nadir and Gleason score. The Phoenix definition was used for biochemical failure. Statistical analysis was performed using the Kaplan-Meier method, and univariate and multivariate analysis was performed using a Cox model.

Results: Of 704 study patients 78.5% had intermediate or high risk disease. Mean followup was 5.3 years (range 1.3 to 14). Cancer specific survival was 99%, metastasis-free survival was 95%, and 10-year salvage treatment-free rates were 98% in low risk, 72% in intermediate risk and 68% in high risk patients. Prostate specific antigen nadir and Gleason score predicted biochemical failure, and side effects were moderate. The high intensity focused ultrasound re-treatment rate has been 15% since 2005.

Conclusions: Long-term followup with high intensity focused ultrasound therapy demonstrated a high overall rate of cancer specific survival and an exceptionally high rate of freedom from salvage therapy requirements in low risk patients. Advances in high intensity focused ultrasound technology and clinical practice as well as the use of neoadjuvant transurethral prostate resection allow the complete treatment of any size prostate without inducing metastasis.

Key Words: prostatic neoplasms; ultrasound, high-intensity focused, transrectal; robotics; ultrasonic therapy; ablation techniques

High intensity focused ultrasound has been used experimentally in urology since the 1930s^{1–6} and clinical investigations began in 1996 as a transrec-

tal ablative therapy for localized prostate cancer.^{7–9} Since the early 2000s HIFU has been combined with neoadjuvant transurethral resection of the

Table 1. Reasons for exclusion from study

	No. (%)
Overall	736 (51)
Followup less than 15 mos	490 (34)
Treatment vol less than 80%	115 (8.0)
Neoadjuvant ADT greater than 12 mos	61 (4.2)
Previous radiation	30 (2.0)
PSA at first diagnosis greater than 50 ng/ml	25 (1.7)
Previous orchiectomy	6 (0.4)
Previous other HIFU	5 (0.3)
Previous chemotherapy	4 (0.2)

prostate.^{10,11} The status of HIFU has remained investigational because the body of published evidence has not yet reached sufficient maturity to provide definitive data on long-term cancer control. This is especially true given the followup length of studies evaluating external beam radiotherapy and radical prostatectomy.^{12,13}

The current study was designed in 1995, before the first use of HIFU at 3 MHz with the Ablatherm device. Given the typical slowly progressing natural history of PCa and the need to document long-term cancer control and morbidity, patient accrual and followup were planned from the outset in 1996 to run 25 years. The primary objective of the current study was to evaluate the long-term cancer control efficacy and morbidity of HIFU with neoadjuvant TURP. The secondary objective was to evaluate metastasis induction by TUR in prostate cancer. The third objective was to document and evaluate advances in technology and refinement in clinical application during the study period.

PATIENTS AND METHODS

Data from all patients treated with HIFU in Munich-Harlaching were prospectively entered into a database. All patients were treated completely with Ablatherm HIFU devices. At the time of analysis the database consisted of 2,079 cases including 1,440 treated for localized disease (T1–2, N0, M0). The remaining cases received HIFU as primary therapy for advanced stage PCa or as salvage therapy for recurrence after nonHIFU primary therapy. Of the 1,440 patients treated for localized disease 736 were excluded from analysis as they did not meet the inclusion criteria (see Appendix, table 1). This yielded a study population of 704 patients treated from 1996 to the end of 2009. These patients were stratified into 3 cohort groups based on year of therapy and treatment device. During the study period 3 generations of HIFU devices were used because patients were treated with the then most recent HIFU device available. These included the prototype device from 1996 to 1999 (cohort 1), the first commercially available device, the Ablatherm Maxis®, from 2000 to 2005 (cohort 2), and the second device, Ablatherm Integrated Imaging, beginning in 2005 (cohort 3). Data collection and evaluation were performed by a third party (Harlachinger Krebs-

shilfe e.V.), and did not involve individuals with a commercial interest in the study outcomes.

Localized PCa was diagnosed by transrectal ultrasound guided biopsy of the prostate and seminal vesicles. The combined results of digital rectal examination, transrectal ultrasound, radiological staging, TRUS guided rectal biopsies, TUR chips and PSA were used in clinical tumor staging. Specific transitional zone biopsies were not performed as the ventral area of the prostate was resected and histopathologically analyzed. The integration, characteristics and histopathological outcome of neoadjuvant TURP before HIFU are displayed in table 2. The operational procedure of the Ablatherm HIFU device has been previously described in detail.^{14–16}

Before 2000 most patients received HIFU therapy without TURP. In the absence of pre-HIFU TURP, prostates larger than 30 cc could only be partially ablated due to limited rectal movement space for the transrectal applicator, and limited HIFU penetration into the ventral areas and middle lobes. During the 15-year study period the majority of HIFU/TURP treatments at our institution (more than 75%) were performed by 2 surgeons, while the remaining treatments were supervised by these surgeons.

Neoadjuvant TURP has undergone substantial refinement since its introduction. Several characteristics now distinguish neoadjuvant TURP from conventional TURP performed for adenoma resection. HIFU induces substantial shrinkage of the residual prostatic capsule and bladder neck. TURP compensates for this effect with resection of a large bladder neck and the entire middle lobe.

The penetration depth of HIFU is limited to approximately 30 mm. Therefore, ventral prostatic tissue in larger prostate glands cannot be completely coagulated and requires TURP. Because HIFU induces the formation of fibrotic scar tissue, apical tissue should not be left in place but should instead be resected in a radical manner as when TURP is used for adenoma resection.

Monopolar resection of the prostate was performed from 2000 to 2005 and bipolar resection has been performed since 2005. Few patients underwent previous open

Table 2. Transurethral resection data

	All	Prototype	Maxis	Integrated Imaging
Yrs study period	1996–2009	1996–1999	2000–2004	2005–2009
No. pts	704	170	358	176
No. TUR before HIFU (%)	528 (75)	6 (3.5)	346 (96.6)	176 (100)
TUR (%) of prostate vol:				
Median	43	36	39	52
Mean	44	38	39	51
Max	93	55	93	86
Min	2	25	4	2
No. no TUR histology (%)	55 (10.4)	0	36 (10.1)	19 (10.8)
No. no PCa (%):	220 (41.7)	3 (50)	150 (43.4)	67 (38.1)
Less than 10%	143 (27.1)	2 (33.3)	91 (28.9)	50 (28.4)
10%–30%	83 (15.7)	0	49 (14.2)	34 (19.3)
Greater than 30%	27 (5.1)	1 (16.7)	20 (5.8)	6 (3.3)
No. TUR combined (%)*	422 (79.9)	1 (16.7)	311 (89.9)	110 (62.5)
No. TUR split (%)†	106 (20.1)	5 (83.3)	35 (10.1)	66 (37.5)

* TUR and HIFU in 1 session.

† TUR 1 month before HIFU.

Table 3. Prognostic factors for biochemical progression (Phoenix) and need for salvage treatment using univariate analysis and Cox model

	Univariate p Value	Univariate Risk Ratio	Univariate 95% CI	Multivariate p Value	Multivariate Risk Ratio	Multivariate 95% CI
<i>Biochemical progression (Phoenix)</i>						
Age	0.653	1.01	0.97–1.04	0.706	1.00	0.98–1.04
PSA (ng/ml):						
4 or Less	—	1	—	—	1	—
4–10	0.695	0.87	0.42–1.79	0.613	0.83	0.40–1.72
10 or Greater	0.016	2.40	1.18–4.88	0.044	2.11	1.01–4.35
Gleason:						
6 or Less	—	1	—	—	1	—
7	0.215	1.32	0.85–2.04	0.896	1.03	0.65–1.65
8 or Greater	0.077	2.29	0.91–5.74	0.221	1.80	0.70–4.61
Stage:						
T1	—	1	—	—	1	—
T2	0.607	1.19	0.62–2.29	0.601	0.83	0.42–1.66
Biopsies:						
2 or Less	—	1	—	—	1	—
3–4	0.124	1.40	0.91–2.15	0.120	1.43	0.91–2.25
5 or Greater	0.350	1.40	0.69–2.85	0.281	1.51	0.72–3.17
Prostate vol (cc):						
25 or Less	—	1	—	—	1	—
Greater than 25	0.224	0.75	0.47–1.20	0.188	0.73	0.45–1.17
TURP:						
No	—	1	—	—	1	—
Yes	0.050	0.65	0.43–1.00	0.713	0.80	0.24–2.63
Neoadjuvant ADT:						
No	—	1	—	—	1	—
Yes	0.022	1.61	1.07–2.41	0.177	1.34	0.88–2.05
<i>Need for salvage treatment</i>						
Age	0.049	0.97	0.95–1.00	0.075	0.98	0.95–1.00
PSA (ng/ml):						
4 or Less	—	1	—	—	1	—
4–10	0.554	0.82	0.42–1.60	0.364	0.73	0.37–1.44
10 or Greater	0.055	1.90	0.99–3.66	0.473	1.28	0.65–2.53
Gleason:						
6 or Less	—	1	—	—	1	—
7	0.001	1.98	1.30–3.00	0.196	1.35	0.96–2.12
8 or Greater	0.001	3.20	1.57–6.54	0.021	2.49	1.15–5.39
Stage:						
T1	—	1	—	—	1	—
T2	0.006	7.05	1.74–28.58	0.041	4.39	1.06–18.2
Biopsies:						
2 or Less	—	1	—	—	1	—
3–4	0.001	2.10	1.37–3.22	0.003	1.99	1.27–3.12
5 or Greater	0.002	2.55	1.39–4.68	0.210	1.56	0.78–3.15
Prostate vol (cc):						
25 or Less	—	1	—	—	1	—
Greater than 25	0.229	0.75	0.47–1.20	0.360	0.80	0.49–1.29
TURP:						
No	—	1	—	—	1	—
Yes	0.001	0.41	0.27–0.61	0.961	0.97	0.26–3.64
Neoadjuvant ADT:						
No	—	1	—	—	1	—
Yes	0.002	1.87	1.26–2.77	0.485	1.17	0.75–1.82

adenectomy or green light laser ablation of the prostate. Those who did were endoscopically re-resected to achieve a standardized anatomy before HIFU. During the consent process, patients were informed of a 20% probability that they would be offered a second HIFU treatment during followup and a 20% probability of secondary endoscopic necrosis/scar tissue removal within postoperative year 1. HIFU re-treatment was suggested to patients with PSA relapse and biopsy proven locally residual or recurrent

PCa at followup. Followup data were obtained by patient survey, medical records, mail and telephone contact. For perioperative complications the Clavien classification was used.¹⁷

In addition to device/year cohort groupings, patients were also stratified by risk group for tumor recurrence including low risk (T1–T2a and PSA 10 ng/ml or less and Gleason 6 or less), intermediate risk (T2b or PSA 11 to 20 ng/ml or Gleason 7) and high risk (stage T2c or PSA 21 to

50 ng/ml or Gleason 8 or greater), and by Gleason score and by PSA nadir.¹⁸

To determine BDFS rates, biochemical failure was defined using the Phoenix definition (PSA nadir + 2 ng/ml). The Kaplan-Meier method was used to construct survival curves which were compared using the log rank test. A Cox regression model was used in univariate and multivariate analysis of variables with possible prognostic relevance (table 3). Patients undergoing second HIFU were not censored from evaluation. A $p < 0.05$ was chosen as the level of statistical significance.

RESULTS

A total of 704 patients were included in this analysis. Staging biopsy per patient (range 6 to 24) was correlated to 8 target areas of the prostate (right, left, apex, mid, base) and seminal vesicles, and an average of 2.23 (range 1 to 6) prostatic areas were positive for malignancy. Unilateral PCa was found in 66%, 68% and 69% of patients in cohorts 1, 2 and 3, respectively. HIFU was performed with the patient under spinal anesthesia and sedation (89.6%). Full anesthesia (10.4%) was used per to patient preference or when spinal anesthesia was not feasible. The average HIFU treatment session lasted 119 minutes with 626 lesions. This did not change significantly during the study period because the delivery approach of alternating shots and delays (5 seconds/5 seconds) and prostate size at HIFU remained constant (table 4). The overall re-treatment rate was 22.3% and decreased with time (56%/25%/15%).

Table 4. Included patients

	All	Prototype	Maxis	Integrated Imaging
No. pts	704	170	358	176
Cohort yrs	1996–2009	1996–1999	2000–2004	2005–2009
Mean pt age	68.4	67	68.6	69.2
Mean ng/ml PSA at first diagnosis	9.9	9.9	11.5	9.6
% (No.) Gleason score:				
Less than 7	67 (472)	53	73	68
7	27.9 (196)	44	20	28
Greater than 7	5.1 (36)	3	7	4
% (No.) Risk (D'Amico):				
Low	21.6 (153)	14.7	23.5	24.4
Intermediate	38.4 (270)	42.9	36.6	37.5
High	40.0 (281)	42.4	39.9	38.1
% (No.) neoadjuvant ADT less than 6 mos	25.3 (178)	31.8	23.7	22.2
% (No.) neoadjuvant ADT 6–12 mos:				
T1	11.5 (81)	11	12	10.2
T2	88.5 (623)	89	88	89.8
Mean cc prostate vol at diagnosis	36	23.00	37.70	45.4
Mean cc prostate vol at HIFU	21.5	21.6	21.6	21.2

Table 5. Biochemical efficacy

	Mean PSA Nadir	Median PSA Nadir	Median Mos to PSA Nadir	Median ng/ml/yr PSA Velocity
All	1.7	0.1	2.1	0.02
Prototype	1.5	0.2	2.3	0.02
Maxis	2.5	0.1	1.9	0.03
Integrated Imaging	0.1	0.1	2.3	<0.01

Efficacy

PSA nadir occurred at a mean of 2.1 months (range 0.2 to 12.0) at a median of 0.10 ng/ml (range 0.0 to 21.0). Median PSA nadir values differed among cohorts 1, 2 and 3 less than the mean values (table 5). After PSA nadir, the median PSA velocity of the sample was 0.02 ng/ml per year (mean 0.44).

The overall survival of the patient population was identical to current local Bavarian population survival statistics (fig. 1, A). Through 10 years of followup a correlation between overall survival and patient risk group was not found (fig. 1, B). The 10-year cancer specific survival rate was 99%, which remained constant through to 14 years of followup (fig. 1, C) The 10-year metastasis-free survival rate was 95% in patients who received neoadjuvant TURP (fig. 2, A). BDFS rates varied by risk group, with 5-year rates of 92% to 84% and 10-year rates of 68% to 60% (fig. 2, B).

A correlation was found between PSA nadir group and biochemical failure (fig. 2, C), as was a correlation between risk group and salvage treatment-free survival (fig. 3, A). After TURP and HIFU, few low risk patients required salvage therapy at 12-year followup. The salvage therapy-free rates for intermediate and high risk patients at 5 years were 87% and 82%, and at 10 years were 72% and 68%, respectively. D'Amico risk groups were correlated with salvage treatment-free survival. At 10-year followup salvage therapy was initiated in less than 2% of low risk patients and in 27% to 36% of intermediate/high risk patients.

Morbidity

Perioperative complications (Clavien classification) occurred in 16% of the entire sample, and a decrease with time was found among cohorts 1, 2 and 3 (29%/10%/14%).¹⁷ No perioperative complications were severe, all were of short duration and no Clavien IV or V complications were observed.

The rates of short to intermediate-term morbidity included incontinence (4%), obstruction (4.6%), infection (2.1%), rectourethral fistula formation (0.23%), perineal pain (0.7%) and other morbidity (4.4%). There were no cases of fistula since the introduction of robotic HIFU in 2005 (table 6). The morbidity profile but not the overall rate changed significantly in subsequent cohorts. The overall rate of urinary incontinence for

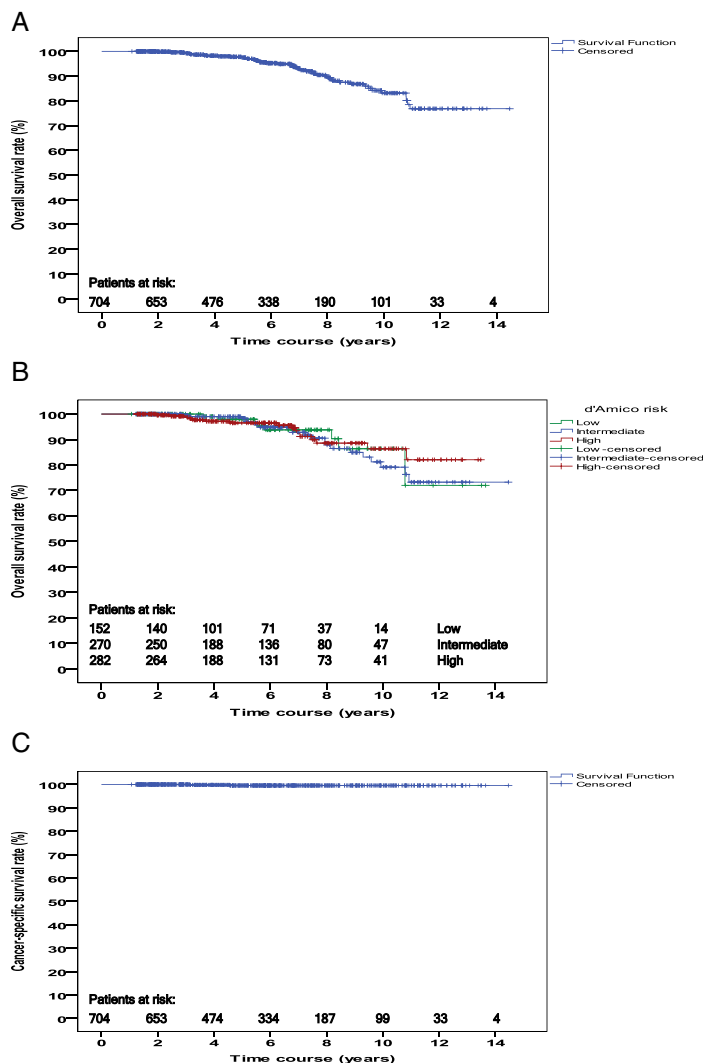


Figure 1. Overall (A), D'Amico risk (B) and cancer specific (C) survival rates

more than 3 months was 3.26%, with rates of 5.1%, 3.1% and 1.5% in cohorts 1, 2 and 3, respectively. The overall rate of secondary obstruction (from necrotic or scar tissue that resulted in bladder neck or intraprostatic stenosis) was 24%, 19% and 24% in cohorts 1, 2 and 3, respectively. Urinary tract infection recurred in 2.56%, 1.87% and 3.08% of the sample. Although comprehensive data on erectile function with validated questionnaires were not available, the post-HIFU clinical potency rate in previously potent patients was about 55%. Of these patients approximately two-thirds were taking phosphodiesterase type 5 inhibitors.

It should be mentioned that there were no cases of late onset impotence and no cases of any other late onset (greater than 1 year) morbidity. Morbidity with the longest delay in onset was a 5Fr bladder neck stenosis from circular scar tissue occurring 6 to 12 months after HIFU. As a result, a significant rate

of secondary endourological interventions of 24% was registered.

DISCUSSION

Biopsy and radiological imaging in preoperative PCa tumor staging are limited because of restricted digital resolution and visual analysis. In this study we established tumor stage clinically with the combined use of digital rectal examination, transrectal ultrasound, radiological staging, TRUS guided rectal biopsies, TUR chips and PSA.

The extent of PSA decrease within 3 months after localized therapy produces the PSA nadir value, which we found was a significant predictive factor in biochemical failure. After the PSA nadir is reached, PSA velocity can be used to trigger the need for the timing of salvage therapy. Several studies have shown that a PSA nadir less than 0.3 ng/ml is asso-

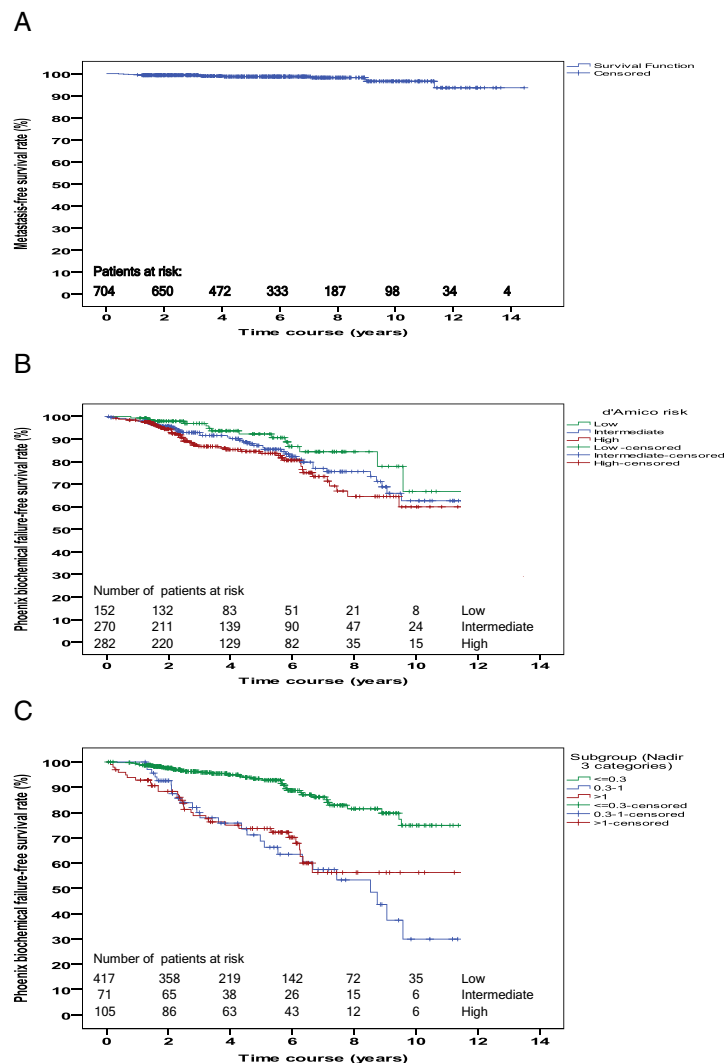


Figure 2. Metastasis-free (A), BDFS (B), and PSA nadir and biochemical failure (C) survival rates.

ciated with a salvage treatment-free survival rate at 10 years of more than 80%.¹⁹ Biochemical disease-free survival rates of 94% at 5 years and 74% at 10 years, after a PSA nadir of less than 0.3 ng/ml, and greater than 80% (according to D'Amico risk groups) at 5 years and greater than 60% at 10 years, are promising.

The overall survival of the study population was equal to the general Bavarian survival rate and did not differ between risk groups. The 10-year cancer specific survival was 99%, a finding typical of most long-term PCa studies, and reflects the slowly progressing nature of the malignancy. The 10-year metastasis-free survival rate of 95% in patients who underwent TURP addresses the concern of metastatic induction by TURP in patients with prostate cancer, and shows no relationship between TURP and metastatic spread. The BDFS rate was correlated with risk group. The 5-year BDFS rates of 92% to 84% and the 10-year BDFS rates of 68% to 60%

showed a parallel decrease in all risk groups with time (fig. 2, B). PSA nadir reflects the completeness of tumor ablation with HIFU and a difference in BDFS was shown among the 3 nadir subgroups (table 5, fig. 2, C). Among patients with a PSA nadir less than 0.3 ng/ml, the BDFS rate was 94% at 5 years and 74% at 10 years. In patients with a PSA nadir of 0.3 ng/ml or greater the BDFS rate was 73% to 70% at 5 years and 56% to 30% at 10 years (depending on risk group, fig. 2, C).

Although efficacy associated with the different generations of HIFU technology did not change significantly during the study period, neoadjuvant TURP contributed to efficacy by decreasing the average PSA nadir values as the result of reducing prostate size to less than 25 cc to make the prostate gland more amenable to complete HIFU ablation.

The point at which salvage therapy is required (excluding a second HIFU session) represents an important variable in the setting of clinical practice

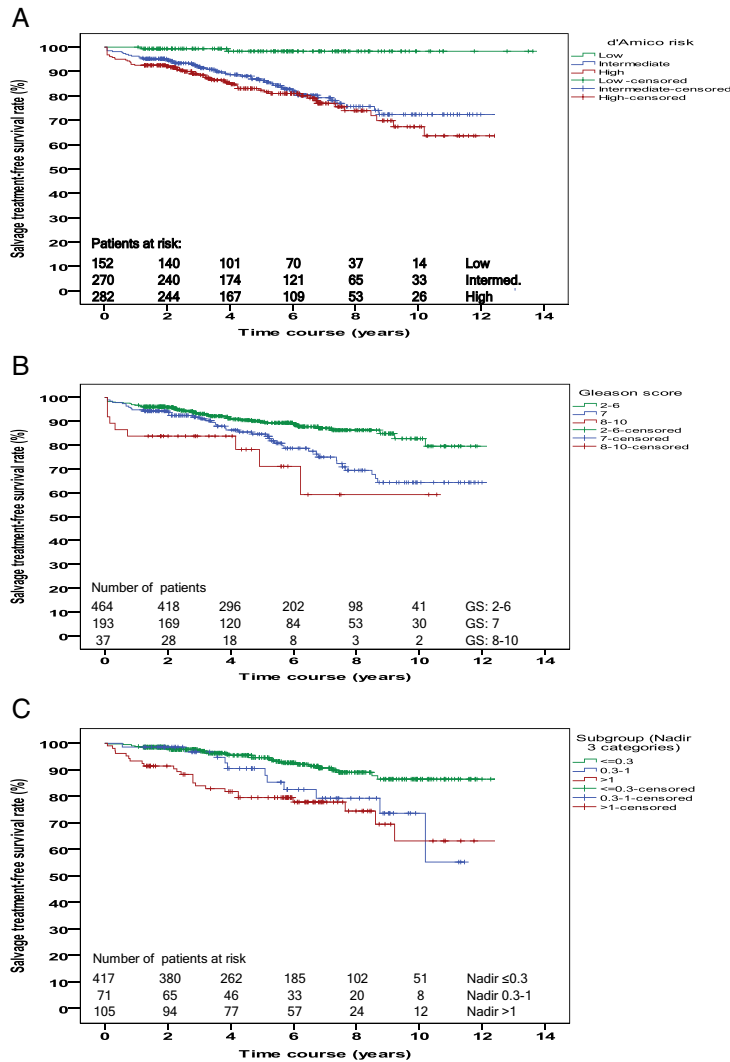


Figure 3. D’Amico risk (A), Gleason score (B) and PSA nadir (C) salvage treatment-free survival.

and efficacy research. Several factors influence the decision to undergo salvage therapy, including post-treatment PSA, treatment guidelines, comorbidity, psychological factors and concern over potential morbidity associated with the salvage therapy.

The correlation of D’Amico risk group with salvage treatment-free survival involves 2 interesting

issues. 1) With 99% of patients with low risk disease not requiring salvage therapy during a 10-year followup, the extent of cancer control is obvious. This finding might encourage the use of focal therapy in these patients, especially given the finding during staging that nearly 67% of these patients had unilateral cancer. 2) The intermediate and high risk groups still exhibited reasonable BDFS rates of 87% to 82% at 5 years and 72% to 68% at 10 years.

Recently Wilt et al published their data regarding the effectiveness of surgery vs observation for men with localized prostate cancer.²⁰ The authors showed that among men with localized prostate cancer detected during the early era of PSA testing, radical prostatectomy did not significantly reduce all cause or prostate cancer mortality compared with observation through at least 12 years of followup. Although their data should be taken with caution considering the relatively small study population

Table 6. Side effects

	Prototype (%)	Maxis (%)	Integrated Imaging (%)
Incontinence (less than 3 mos)*	4.2	4.2	3.1
Incontinence (more than 3 mos)*	5.1	3.1	1.5
Rectourethral fistula	0.59	0.28	0.0
Recurrent urinary tract infections	2.56	1.87	3.08
Perineal discomfort	1.26	0.23	0.51
Others periop	11.7	1.17	2.56
Secondary obstruction	24	19	24

* Defined as more than 1 pad per day.

and the short followup, their study clearly shows that minimally invasive therapies for prostate cancer will become even more important in the future.

There are several important limitations to our study. The presented data are based on a single arm study without comparison groups. Furthermore, changes in technology and surgical protocol during the course of the study may have confounded some of the outcome analyses.

CONCLUSIONS

The results in 704 patients show that HIFU offers men with localized PCa a standardized reliable therapy with a low rate of perioperative comorbidity, an absence of serious morbidity and sufficient cancer control such that salvage therapy was not required at 10-year followup by 99%, 72% and 68% of low, intermediate and high risk patients, respectively, which is particularly important from a patient centered perspective. PSA nadir was demonstrated to be the greatest predictor of biochemical failure and the median PSA nadir has been 0.1 ng/ml or less since 2000. PSA velocity was less than 0.1 ng/ml but not zero, resulting in a slow increase to a PSA of 0.29 ng/ml at 5 years. The 95% metastasis-free survival rate at 10 years excludes TURP as a factor in met-

astatic spread in patients with localized prostate cancer and represents the first published data to our knowledge that empirically refute this long held assumption. Combined with TUR, HIFU can provide low invasive complete local tumor ablation, substituting surgery/cryotherapy or postponing radiation therapy or/and long-term ADT in elderly patients. The presented data of 10-year outcomes may warrant the possible closing of the investigational phase of HIFU.

ACKNOWLEDGMENTS

Regina Nanieva and Dr. Derya Tilki contributed to this work.

APPENDIX

Inclusion criteria

- Biopsy proven, T1–T2c prostate cancer
- No visible lymph node infiltration or metastasis (N0, M0)
- PSA at first diagnosis less than 50 ng/ml
- Any Gleason stage
- Neoadjuvant androgen deprivation less than 12 months
- HIFU as primary definitive PCa therapy
- Complete HIFU therapy (with/without TURP)
- Informed consent
- Followup greater than 15 months

REFERENCES

1. Burov AK: High-intensity ultrasonic vibrations for action on animal and human malignant tumours. *Dokl Akad Nauk SSSR* 1956; **106**: 239.
2. Fry FJ and Johnson LK: Tumor irradiation with intense ultrasound. *Ultrasound Med Biol* 1978; **4**: 337.
3. Fry WJ, Barnard JW, Fry EJ et al: Ultrasonic lesions in the mammalian central nervous system. *Science* 1955; **122**: 517.
4. Fry WJ, Mosberg WH Jr, Barnard JW et al: Production of focal destructive lesions in the central nervous system with ultrasound. *J Neurosurg* 1954; **11**: 471.
5. Goss SA and Fry WJ: The effects of high-intensity ultrasonic irradiation on tumour growth. *IEEE Trans Sonics Ultrasonics* 1984; **SU-31**: 491.
6. Lizzi FL, Coleman DJ, Driller J et al: A therapeutic ultrasound system incorporating real time ultrasonics scanning. In: *Proceedings of the 1986 Ultrasonics Symposium, Institute of Electrical and Electronic Engineers*. Edited by BR MacAvoy. New York: IEEE 1987; pp 981–984.
7. Gelet A, Chapelon JY, Bouvier R et al: Treatment of prostate cancer with transrectal focused ultrasound: early clinical experience. *Eur Urol* 1996; **29**: 174.
8. Uchida T, Sanghvi NT, Gardner TA et al: Transrectal high-intensity focused ultrasound for treatment of patients with stage T1b–2n0m0 localized prostate cancer: a preliminary report. *Urology* 2002; **59**: 394.
9. Vallancien G, Chartier-Kastler E, Chopin D et al: Focussed extracorporeal pyrotherapy: experimental results. *Eur Urol* 1991; **20**: 211.
10. Chaussy C and Thüroff S: The status of high-intensity focused ultrasound in the treatment of localized prostate cancer and the impact of a combined resection. *Curr Urol Rep* 2003; **4**: 248.
11. Vallancien G, Prapotnich D, Cathelineau X et al: Transrectal focused ultrasound combined with transurethral resection of the prostate for the treatment of localized prostate cancer: feasibility study. *J Urol* 2004; **171**: 2265.
12. Bill-Axelsson A, Holmberg L, Filen F et al: Radical prostatectomy versus watchful waiting in localized prostate cancer: the Scandinavian Prostate Cancer Group-4 randomized trial. *J Natl Cancer Inst* 2008; **100**: 1144.
13. Zelefsky MJ, Reuter VE, Fuks Z et al: Influence of local tumor control on distant metastases and cancer related mortality after external beam radiotherapy for prostate cancer. *J Urol* 2008; **179**: 1368.
14. Chaussy CG and Thüroff S: High intensity focused ultrasound for the treatment of prostate cancer. In: *Minimally Invasive Uro-oncology Surgery*. Edited by RG Moore and JT Bishoff. Oxford: Taylor and Francis 2005; pp 327–35.
15. Chaussy C, Thuroff S, Rebillard X et al: Technology insight: high-intensity focused ultrasound for urologic cancers. *Nat Clin Pract Urol* 2005; **2**: 191.
16. Thuroff S and Chaussy C: Status of high intensity focused ultrasound (HIFU) in urology in 2005. In: *Therapeutic Energy Application in Urology: Standards and Recent Developments*. Edited by C Chaussy, G Haupt, D Jocham et al. Stuttgart: Thieme Vlg 2005; pp 92–102.
17. Dindo D, Demartines N and Clavien PA: Classification of surgical complications: a new proposal with evaluation in a cohort of 6336 patients and results of a survey. *Ann Surg* 2004; **240**: 205.
18. D'Amico AV, Whittington R, Malkowicz SB et al: Biochemical outcome after radical prostatectomy, external beam radiation therapy, or interstitial radiation therapy for clinically localized prostate cancer. *JAMA* 1998; **280**: 969.
19. Crouzet S, Rebillard X, Chevallier D et al: Multi-centric oncologic outcomes of high-intensity focused ultrasound for localized prostate cancer in 803 patients. *Eur Urol* 2010; **58**: 559.
20. Wilt TJ, Brawer MK, Jones KM et al: Radical prostatectomy versus observation for localized prostate cancer. *N Engl J Med* 2012; **367**: 203.

EDITORIAL COMMENTS

This is the world's largest experience on the HIFU procedure with meaningful 10-year survival figures providing new information beyond the existing literature. Several methodological concerns, eg retrospective analysis on a single arm study, compromise the quality of the evidence. Understandably, however, identifying a comparison group would be a challenge. The population is unavoidably inhomogeneous and the study spans a long period. In addition, there were different treatment philosophies as well as different equipment and surgical protocols (eg extensive vs limited vs no TURP, bipolar vs unipolar etc).

A laudable secondary objective stated by the authors, "to evaluate metastasis induction by TUR,"

The clinical application of HIFU was initiated at Indiana University in 1953 (references 3 and 4 in article) and has been used since 1993 to treat prostate disorders.¹ Thüroff and Chaussy have demonstrated the ability of the Ablatherm device to effectively treat localized prostate cancer. Uchida et al (reference 8 in article) and our group² have demonstrated similar findings in localized and locally recurrent prostate cancer with the Sonablate® device. This study demonstrates that whole gland ablation

unfortunately was not adequately addressed. In the absence of any form of data analysis, multivariate or otherwise, the observation by the authors that neoadjuvant TURP did not promote metastatic disease is speculative. It should also be noted that neoadjuvant TURP is a feature specific to Ablatherm and not all HIFU devices.

These limitations aside, the authors have meticulously chronicled the development of this technology, demonstrating long-term safety and satisfactory prostate cancer control.

Joseph L. Chin

*University of Western Ontario
London, Ontario, Canada*

with or without TURP can be effective, but can be associated with a 10% to 20% risk of bladder neck contracture. The authors add long-term Gleason score dependent cancer control rates to the growing body of literature on HIFU prostatectomy.

Thomas A. Gardner

*Department of Urology
VA Medical Center
Indiana University Health
Indianapolis, Indiana*

REFERENCES

1. Gardner TA and Koch MO: Prostate cancer therapy with high-intensity focused ultrasound. *Clin Genitourin Cancer* 2005; **4**: 187.
2. Koch MO, Gardner T, Cheng L et al: Phase I/II trial of high intensity focused ultrasound for the treatment of previously untreated localized prostate cancer. *J Urol* 2007; **178**: 2366.

Fourteen-year oncological and functional outcomes of high-intensity focused ultrasound in localized prostate cancer

Roman Ganzer, Hans-Martin Fritsche, Andreas Brandtner, Johannes Bründl, Daniel Koch*, Wolf F. Wieland and Andreas Blana*

Caritas St. Josef Medical Center, University of Regensburg, Regensburg, and *Department of Urology, Fuerth Hospital, Fuerth, Germany

What's known on the subject? and What does the study add?

- High-intensity focused ultrasound (HIFU) is an alternative treatment option for localized prostate cancer (PCa), which is applied for over 15 years. There are conflicting recommendations for HIFU among urological societies, which can be explained by the lack of prospective controlled studies, reports on preselected patient populations and limited follow-up providing little information on overall and cancer-specific survival.
- We report on a large, unselected consecutive patient series of patients who have undergone primary HIFU for clinically localized PCa with the longest follow-up in current literature. Our results improve the understanding of the oncological efficacy, morbidity and side effects of primary HIFU.

Objective

- To assess the safety, functional and oncological long-term outcomes of high-intensity focused ultrasound (HIFU) as a primary treatment option for localized prostate cancer (PCa).

Patients and Methods

- We conducted a retrospective single-centre study on 538 consecutive patients who underwent primary HIFU for clinically localized PCa between November 1997 and September 2009.
- Factors assessed were: biochemical disease-free survival (BDFS) according to Phoenix criteria (prostate-specific antigen nadir + 2 ng/mL); metastatic-free, overall and PCa-specific survival; salvage treatment; side effects; potency; and continence status.

Results

- The mean (SD; range) follow-up was 8.1 (2.9; 2.1–14.0) years.
- The actuarial BDFS rates at 5 and 10 years were 81 and 61%, respectively. The 5-year BDFS rates for low-, intermediate- and high-risk patients were 88, 83 and

48%, while the 10-year BDFS rates were 71, 63 and 32%, respectively.

- Metastatic disease was reported in 0.4, 5.7 and 15.4% of low-, intermediate- and high-risk patients, respectively.
- The salvage treatment rate was 18%.
- Seventy-five (13.9%) patients died. PCa-specific death was registered in 18 (3.3%) patients (0, 3.8 and 11% in the low-, intermediate- and high-risk groups, respectively).
- Side effects included bladder outlet obstruction (28.3%), Grade I, II and III stress urinary incontinence (13.8, 2.4 and 0.7%, respectively) and recto-urethral fistula (0.7%). Preserved potency was 25.4% (in previously potent patients).

Conclusions

- The study demonstrates the efficacy and safety of HIFU for localized PCa.
- HIFU is a therapeutic option for patients of advanced age, in the low- or intermediate-risk groups, and with a life expectancy of ~10 years.

Keywords

HIFU, localized, long-term, outcome, prostate cancer

Introduction

High-intensity focused ultrasound (HIFU) is an alternative treatment option for localized prostate cancer (PCa). There are two HIFU systems currently marketed, the Ablatherm™ (EDAP-TMS, Vaulx-en-Velin, France) and the Sonablate™ (Focus Surgery Inc., Indianapolis, IN, USA). Over the last 15 years, >25 000 HIFU PCa treatments have been performed worldwide. Although there is a growing number of publications reporting on good cancer control and moderate side effects with primary HIFU [1–4], recommendations for HIFU are the subject of controversy among European urological societies [5]. This can be explained by the lack of prospective controlled studies as well as limited follow-up, providing little information on overall and cancer-specific survival [2]. In addition, most publications on HIFU are limited by the fact that they report on a preselected patient population, which inevitably leads to a bias in the reported results. In the USA, Federal Food and Drug Administration approval will be judged on the results of a prospective trial which is under way.

The aim of the present study was to provide oncological and functional follow-up on an unselected series of patients, who underwent HIFU treatment for localized PCa over a 14-year period. This is the longest follow-up of any HIFU series in the current literature.

Patients and Methods

Patient Selection

HIFU treatment was offered to patients with clinically localized PCa who were either assessed to be unsuitable for surgery (e.g. because of advanced age or comorbidity) or if they declined to undergo radical treatment after informed consent. HIFU was also offered as an option to patients with incidental PCa after TURP. Staging for distant metastasis was performed by means of abdominal/pelvic CT and bone scan in intermediate- and high-risk patients. Patients with a minimum gap of 2 years since their first HIFU treatment were considered for this analysis without any further pre-selection. Patients who had undergone short-term pre-treatment androgen deprivation therapy (ADT) were not excluded. Pre-treatment ADT was not part of a neoadjuvant HIFU therapy concept but was sometimes initiated by the referring urologists in order to offer the patient safety when the treatment decision was deferred. Patients were identified as low-, intermediate- and high-risk according to D'Amico's 2003 risk group categories [6].

Treatment and Follow-Up

Ablatherm® devices were used to perform HIFU. Where prostate volume was ≤ 30 mL, TURP was performed immediately before HIFU to reduce prostate size, remove

calcification and reduce postoperative catheterization time. With larger prostate glands (>30 mL), TURP was performed 4–6 weeks before HIFU. This protocol was initiated in 2001. All patients were assessed at 3-month intervals using TRUS, DRE and PSA measurement. For this analysis, biochemical disease-free survival (BDFS) was defined according to the Phoenix criteria (PSA nadir + 2 ng/mL) [7]. A random control biopsy was recommended at 3–6 months after treatment or in cases of rising PSA level.

Erectile function was assessed according to the ability to perform intercourse with or without medical assistance. Continence was assessed as follows: grade 1 stress urinary incontinence (SUI): loss of urine under heavy exercise requiring 0 to 1 pad per day; grade 2 SUI: urine loss at light exercise requiring >1 pad per day and grade 3 SUI: urine loss at rest.

Patients who attended follow-up visits other than at our institution were periodically contacted so that they could complete a self-administered questionnaire. This included sections on PSA, post-treatment biopsy, additional lower urinary tract interventions, salvage PCa treatment, side effects, and results of imaging.

Of the patients who failed HIFU treatment, information regarding type and sequence of salvage treatment, last PSA and metastatic status was recorded. The registration offices, family doctors and referring urologists of those patients who had died provided information on cause-specific mortality, last PSA and metastatic status.

Statistical Analysis

Statistical analysis was performed using SPSS software version 19 (SPSS Inc., Chicago, IL, USA). The t-test was used for parametric quantitative variables, and the Mann–Whitney U-test for non-parametric variables. Categorical variables (e.g. success rates at the last evaluation) were compared using the chi-squared test. Actuarial estimates for survival were calculated using Life Table methods. The log rank test was used to compare the curves based on Kaplan–Meier models. A multivariate Cox proportional hazards regression analysis was used to estimate the prognostic relevance of different clinical variables on biochemical failure as defined by the Phoenix criteria. A *P* value <0.05 was considered to indicate statistical significance.

Results

Patients

Between November 1997 and September 2009, 538 patients were treated for localized PCa at one institution (University of Regensburg). Patient characteristics are shown in Table 1.

The majority of patients had T1c and T2 disease with a Gleason score ≤ 6 . The majority of patients could be classified as low- or intermediate-risk. Pre-treatment ADT was administered to 196 (36.4%) patients; in 160 (29.7%) for < 6 months and 36 (6.7%) for ≥ 6 months, and was not continued after treatment. The mean (SD) follow-up was 8.1 (2.9) years and the median (range) follow-up was 8.3 (2.1–14) years. Only 53 (9.9%) patients were lost to follow-up.

Treatment

Patients were treated between 1997 and 2000 with the 2nd Ablatherm[®] prototype device, between 2000 and 2005 with the Ablatherm-Maxis[®], and thereafter with the Ablatherm Integrated Imaging[®] device. Treatment data are shown in Table 2. Most patients underwent HIFU with the Ablatherm[®] Maxis device and received one HIFU session. The percentage of patients receiving two or more HIFU

Table 1 Patient characteristics.

Characteristic	
No. of patients	538
Mean (SD) age, years	67.7 (7)
Mean (SD) PSA, ng/mL	11.2 (19.7)
Mean (SD) prostate volume, mL	20.9 (9.2)
Clinical stage, <i>n</i> (%)	
pT1a	37 (6.9)
pT1b	33 (6.1)
T1c	151 (28.1)
T2	296 (55.0)
T3	21 (3.9)
Gleason score, <i>n</i> (%)	
≤ 6	402 (74.7)
7	88 (16.4)
8–10	41 (7.6)
Undefined	7 (1.3)
D'Amico risk group, <i>n</i> (%)	
Low	229 (42.6)
Intermediate	211 (39.2)
High	91 (16.9)
Unknown	7 (1.3)

Table 2 Treatment data.

Variable	Value
Treatment device, <i>n</i> (%)	
Ablatherm [®] 2 nd prototype	43 (8)
Ablatherm Maxis [®]	355 (66)
Ablatherm Integrated Imaging [®]	140 (26)
Median (range) treatment time, min	154 (40–375)
Mean (SD) no. of lesions per treatment	599.6 (177.6)
Mean (SD) treated volume, mL	34.6 (14.0)
Mean (SD) treated volume ratio: treated volume/prostate volume	1.9 (0.9)
HIFU sessions per patient, <i>n</i> (%)	
1	423 (78.6)
2	111 (20.6)
3	4 (0.8)

sessions differed between risk groups with 13.1, 26.1 and 31.9% of patients within the low-, intermediate- and high-risk groups, respectively ($P < 0.001$). In 203 (37.7%) patients HIFU and TURP were performed on the same day and in 213 (39.6%) patients, the procedures were conducted sequentially with an interval of 4–6 weeks.

Oncological Outcome

The mean (SD) PSA nadir was 0.4 (1.6) ng/mL (median 0.07 ng/mL), which was achieved at a mean (SD) of 19.9 (11.4) weeks after HIFU. A PSA nadir ≤ 0.2 ng/mL, 0.21–1.0 ng/mL and > 1 ng/mL was reached by 70.8, 18.4 and 10.8% of patients, respectively. A total of 297 (55.2%) patients underwent at least one follow-up biopsy. Of these patients, 76 (25.6%) had histological evidence of cancer; incidence in the low-risk group was 20/125 (16%), in the intermediate-risk group it was 35/122 (28.7%) and in the high-risk group it was 20/50 (40%). Progression to metastatic disease based on bone scan and CT data occurred in 1/229 (0.4%) patients in the low-risk group and in 12/211 (5.7%) and 14/91 (15.4%) patients in the intermediate- and high-risk groups, respectively ($P < 0.001$).

The actuarial BDFS rates at 5 and 10 years for the whole population were 81% and 61%. The 5-year BDFS rates for patients in the low-, intermediate- and high-risk groups were 88, 83 and 48%, respectively, and the 10-year BDFS rates were 71, 63 and 32%, respectively (Fig. 1). The 5-year BDFS rates for patients with a PSA nadir ≤ 0.2 ng/mL, 0.21–1 ng/mL and > 1 ng/mL were 91, 67 and 27%, respectively ($P < 0.001$).

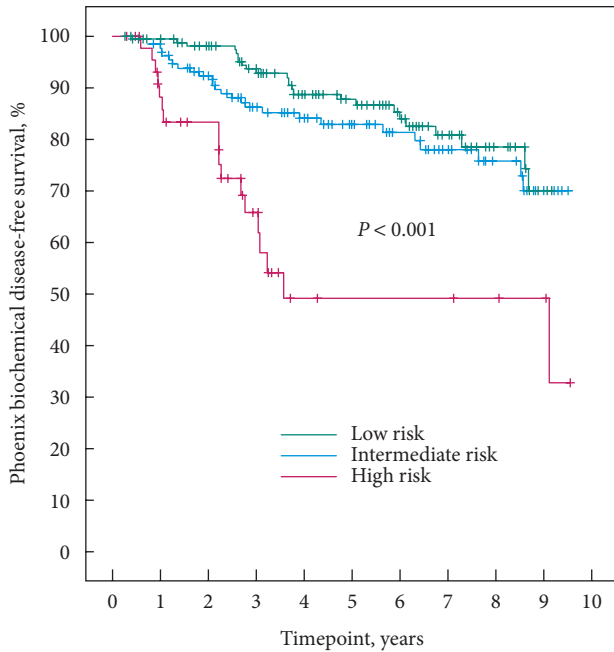
The 5-year BDFS rates were not significantly different for patients without and with pre-treatment ADT (83 vs 78%, respectively, $P = 0.236$). When patients with and without pre-treatment ADT were differentiated, the rates were 88, 45 and 19% vs 93, 77 and 30%, respectively.

In the univariate analysis, PSA nadir was found to be a significant predictor for BDFS. In the multivariate Cox regression analysis, age and a pre-treatment PSA value > 20 ng/mL were significant variables for biochemical failure (Table 3).

Salvage Treatment

A total of 97 (18%) patients received salvage treatment during follow-up. Detailed description of the types of salvage treatment is given in Table 4. A significantly greater proportion of patients in the high-risk group received salvage treatment. In addition, the mean time between last HIFU and salvage treatment was significantly shorter in the high-risk group ($P = 0.003$).

Fig. 1 Kaplan–Meier estimates for 5- and 10-year BDFS for low-, intermediate- and high-risk patients.



Number at risk	0	1	2	3	4	5	6	7	8	9	10
Low risk	229	160	153	140	122	99	81	63	41	26	14
Int. risk	211	134	129	112	89	74	61	51	39	28	16
High risk	91	47	36	31	18	9	6	6	6	5	4

Thirteen (30.2%), 77 (21.7%) and seven (5.0%) patients who were treated with the Ablatherm® prototype, -Maxis and Integrated Imaging devices, respectively, received salvage treatment ($P < 0.001$).

The median (range) PSA at initiation of salvage treatment was 2.4 (0–277) ng/mL. At last follow-up, 20 (20.6%) patients who had received salvage treatment were diagnosed with metastatic disease compared with seven (1.6%) patients in the non-salvage treatment group.

Cause-Specific Mortality

During follow-up 75 (13.9%) patients died. PCa-specific death occurred in 18 (3.3%) patients which included none, eight (3.8%) and 10 (11%) patients within the low-, intermediate- and high-risk group, respectively ($P < 0.001$).

Safety

There was no case of peri-operative mortality. Recto-urethral fistula occurred in four (0.7%) patients, all of whom were undergoing repeat HIFU. UTIs were reported in 55 (10.2%) patients. The most frequent side effect was BOO, which was seen in 152 (28.3%) patients. The mean (SD) time between HIFU and first BOO was 1.4 (1.8) years. There was a statistically higher rate of BOO in patients after repeat HIFU compared with those

undergoing one HIFU session (36.5 vs 26%; $P = 0.035$). The incidence of BOO did not decrease when TURP was conducted in conjunction with HIFU. By contrast, there was a significant difference according to HIFU device: 39.5, 30.1 and 20.0% in patients treated with the Ablatherm® prototype, -Maxis and Integrated Imaging devices, respectively ($P < 0.03$).

Six months after treatment, 93 (17.3%) patients had grade 1 SUI and 15 (2.8%) patients had grade 2 SUI. At last evaluation, 83.1% of patients were pad-free. Grades 1 and 2 SUI were reported by 74 (13.8%) and 13 (2.4%) of patients, respectively. Four (0.7%) patients had grade 3 SUI that required intervention. Of 202 patients with unimpaired pre-treatment potency outcome data were provided by 169 (83.7%) patients. Twelve months after HIFU, 43 (25.4%) were potent (intercourse without medical assistance), 67 (39.6%) were able to perform intercourse with medical assistance and 59 (35%) patients were impotent. For both continence and potency outcomes, there was no significant difference between patients treated with different HIFU devices.

Discussion

The recommendations for HIFU as an alternative treatment option for localized PCa differ among European urological societies. Although the recommendations are based on the same data, HIFU is recommended for a selected group of patients by the associations of Italy, France [8] and the UK, but it is not routinely recommended by the German and European Association of Urology guidelines [9]. Recently, Warmuth et al. [5] performed a systemic literature review to assess the efficacy and safety of HIFU in the primary and salvage setting. They considered only prospective studies with >50 patients and assessed their quality using the Recommendations Assessment, Development, and Evaluation (GRADE) approach. After identification of 20 uncontrolled studies they concluded that the available evidence on efficacy and safety of HIFU is of very low quality based on uncontrolled case series and limited follow-up. The ideal setting would be prospective randomized controlled trials with long follow-up comparing HIFU with other standard treatment options. But it is unlikely that such data will be available in the near future, therefore, it is important to get the best information possible from large patient series with long follow-up of good quality.

Most published HIFU series are limited by the fact that their follow-up is too short to provide sufficient information on oncological efficacy and cancer-specific survival. In addition, many authors perform patient selection in their retrospective publications and report only on a subgroup of their treated patients. Currently, a report

Table 3 Multivariate analysis of factors affecting biochemical failure.

Prognostic factor	Hazard ratio	95% CI	P
Age	1.03	0.99–1.08	0.103
Pre-HIFU PSA			
≤10 ng/mL	1	Reference	Reference
10–20 ng/mL	1.21	0.64–2.29	0.554
>20 ng/mL	3.63	1.63–8.08	0.002
Pre-HIFU Gleason score			
≤6	1	Reference	Reference
7	1.73	0.84–3.56	0.137
≥8	1.63	0.57–4.65	0.363
Stage			
T1	1	Reference	Reference
T2	1.25	0.65–2.41	0.510
T3	3.19	0.56–18.27	0.194
Pre-treatment ADT			
No	1	Reference	Reference
Short (≤6 months)	0.83	0.45–1.54	0.556
Long (>6 months)	1.67	0.61–4.53	0.319
Prostate volume	1.02	0.99–1.06	0.214
TURP			
No	1	Reference	Reference
Combined	0.64	0.33–1.26	0.200
Split	0.77	0.36–1.64	0.497
HIFU sessions			
1	1	Reference	Reference
≥2	0.74	0.37–1.47	0.392
HIFU device			
Ablatherm® 2 nd prototype	1	Reference	Reference
Ablatherm®-Maxis	0.90	0.38–2.17	0.819
Ablatherm® Integrated imaging	2.95	1.01–8.59	0.048

Table 4 Salvage treatment conducted according to overall patient group and risk group sub-categories.

Variable	Total, N = 538–	Risk group		
		Low-risk, N = 229	Intermediate-risk, N = 211	High-risk, N = 91
Patients with salvage treatment, n (%) [*]	97 (18)	25 (10.9)	41 (19.4)	31 (34.0)
Mean (SD) time between HIFU and initiation of salvage treatment, years [†]	3.2 (2.4)	4.0 (2.7)	3.6 (2.5)	2.0 (1.5)
Type of salvage therapy, n (%)				
Hormone therapy	41 (7.6)	8 (3.5)	17 (8.1)	16 (17.6)
Radiation	44 (8.2)	14 (6.1)	19 (9.0)	11 (12.1)
Chemotherapy	5 (0.9)	0	1 (0.5)	4 (4.4)
Radical prostatectomy	7 (1.3)	3 (1.3)	4 (1.9)	0

^{*}P = 0.012 low-risk vs intermediate-risk group; P < 0.001 low-risk vs high-risk group; P = 0.011 intermediate-risk vs. high-risk group.

[†]P = 0.03 low- or intermediate-risk vs high-risk group.

by Blana et al. [1] on 140 patients treated at two centres had a mean follow-up of 6.4 years; however, those patients with a PSA >15 ng/mL and a Gleason score >7 were excluded from that study.

Our publication has several special aspects: with a mean follow-up of 8.1 and a range of up to 14 years, the current study has the longest follow-up of any HIFU series to date. We would have been able to create a mean follow-up of 10 years by extending the minimum distance to HIFU treatment; however, we did not choose to do so, as this

would have reduced our patient numbers and excluded the valid information on morbidity and early cancer control of those patients treated with the latest generation Ablatherm device.

Furthermore, the study includes all consecutive patients treated for primary PCa over a period of 14 years without pre-selection. In addition to providing follow-up data from 90.1% of all patients, we made an effort to obtain all valid information on life status, metastatic status and cause-specific mortality on those patients who failed HIFU

treatment. These aspects give us more insight into the oncological efficacy and the morbidity profile of primary HIFU.

The estimation of biochemical failure after HIFU remains controversial. In the first years of HIFU treatment the initiation of salvage treatment was done individually based on positive biopsy results and PSA kinetics. Nowadays, most authors use the Phoenix criteria to define biochemical failure [1,2,10]. With the 'Stuttgart criteria' (PSA nadir + 1.2 ng/mL) an attempt was made to propose a HIFU-specific definition of biochemical failure [11], but this definition is not yet broadly accepted owing to a lack of validation [12], and the authors consider the Phoenix to be a better definition, especially if one is to compare outcomes with other published series. Using the Phoenix definition in the current study, the BDFS rates were satisfactory at 88 and 83% at 5 years and 71 and 63% at 10 years for the low- and intermediate-risk groups, respectively. Our results are consistent with those of Crouzet et al. [2] who reported 5- and 7-year BDFS rates of 83 and 75% for low-risk, 72 and 63% for intermediate-risk and 68 and 62% for high-risk patients, respectively. Although we see HIFU mainly indicated in well-informed patients of higher age and low-to-intermediate risk, 91 (16.9%) patients in our series at high risk were selected for treatment based on patient preference or comorbidity. The BDFS rates in this group were acceptable at 48% at 5 years but were lower at 32% at 10 years. These numbers suggest that HIFU should not be recommended as a first-line option to high-risk patients with a life expectancy of 10 years. The fact that patients with high PSA values are not safely treated with HIFU is supported by our multivariate analysis. Among eight tested parameters, a PSA >20 ng/mL was an independent variable affecting biochemical recurrence. Neoadjuvant ADT did not affect biochemical recurrence, a finding recently confirmed by Fujisue et al. [13]. The fact that the Integrated Imaging device had an adverse effect on biochemical outcome in the multivariate analysis (Table 3) can be explained by the fact that the follow-up in this group was shorter; therefore, the rate of censored data is much higher in the Integrated Imaging group, leading to worse results.

Although follow-up biopsies were recommended to all patients in the early part of the study, later it was mostly performed for cause in patients with suspicious local or recurrent disease. In the current study, 55.2% of patients underwent follow-up biopsy with a resultant positive rate of 25.6%. This compares with a negative biopsy rate of between 51 and 96% based on a review by Rebillard et al. [8].

Without prospective comparative trials it cannot be known to what degree HIFU treatment affects metastasis-free and cancer-specific survival compared with watchful waiting or

standard treatment methods. This is a limitation of most PCa treatment options as only radical prostatectomy has been prospectively investigated in this setting [14]; however, the present results underline the oncological efficacy for low- and intermediate-risk patients with a life expectancy of 10 years as cause-specific survival rates were 100 and 96.2% and metastasis-free survival rates were 99.6 and 94.3% for the low- and intermediate-risk groups, respectively. These results are very similar to a series of 1062 patients who underwent external beam radiotherapy reported by Zelefsky et al. [15] where metastasis-free survival at 8 years was 93% and PCa-specific death rates for low- and intermediate-risk patients were 0 and 4.5%, respectively. The lack of comparative studies does not allow a comparison of the outcomes of HIFU and cryotherapy of the prostate. Bahn et al. [16] presented a cryotherapy series of 590 patients with a mean follow-up of 5.4 years. According to ASTRO criteria, the actuarial 7-year BDFS rates were 92, 89 and 89% for low-, intermediate- and high-risk patients, respectively.

The salvage treatment rate of 18% in the present study was relatively low when indirectly compared with the Cancer of the Prostate Strategic Urological Research Endeavor (CaPSURE) database, which reported recurrent disease in 587/935 (63%) patients after external beam radiotherapy at a mean time of 38 months [17]; the patient population is not directly comparable with that of the current study, as 45% of patients were classified as high risk in the CaPSURE database. In terms of the side effects of HIFU, a complete continence rate of 86.2% at last evaluation supports favourable continence results. By contrast, an impotence rate of 35% 12 months after HIFU with only 25.4% being fully potent does not support the assumption that full-gland HIFU will preserve potency to a high degree. It may be that preservation of erectile function in patients of advanced age is not of paramount importance, as illustrated by the fact that only 202 (37.5%) of our treated patients claimed to be potent prior to treatment. Higher potency rates have been reported when a nerve-sparing approach has been used. Shoji et al. [18] described potency rates of 52, 63 and 78% at 6, 12 and 24 months, but it is our opinion that attempts to spare the neurovascular bundle with HIFU may undertreat the peripheral zone and that such approaches should only be offered within well-conducted trials of focal therapy.

The most common complication after HIFU is the development of BOO [19,20]. There was a trend towards a lower BOO rate reported if TURP and HIFU were separated by an interval >3 months. Although this is contradicted by Netsch et al. [20] who reported rates of 34 and 18% when the interval was 0 or 2 days and >1 month, respectively. Notably, the BOO that occurs can be treated safely by transurethral incision.

The present study has several limitations. They include the fact that this is a single-arm study without comparison with another standard treatment option and that validated questionnaires for continence and potency were not included until 2007 (data not reported). A major limitation is the low number of 55.2% of patients that underwent a post-HIFU biopsy as well as the fact that we could not make a distinction between patients who underwent routine biopsy and those who were biopsied for a rising PSA level. In addition, three different generations of the Ablatherm® device were used, which might influence the results. Comorbidity was not assessed systematically with a scoring system such as the Charlson comorbidity index.

In conclusion, we report on a large consecutive patient series after primary HIFU for clinically localized PCa with the longest follow-up in current literature. Our results improve the understanding of the oncological efficacy, morbidity and side effects of primary HIFU. The study underlines that HIFU is a therapeutic option for patients of advanced age, at low-to-intermediate risk and with a life expectancy of ~10 years. The rate of serious side effects such as recto-urethral fistulae is low. Before treatment, patients need to be informed about the high rate of BOO. Although continence results are favourable, whole-gland HIFU does not seem to be associated with potency results superior to standard treatment options. The current follow-up is too short to provide evidence that primary HIFU is an oncologically safe treatment option for young patients.

Conflict of Interest

Andreas Blana is a paid consultant for EDAP-TMS.

References

- Blana A, Murat FJ, Walter B et al. First analysis of the long-term results with transrectal HIFU in patients with localised prostate cancer. *Eur Urol* 2008; 53: 1194–201
- Crouzet S, Rebillard X, Chevallier D et al. Multicentric oncologic outcomes of high-intensity focused ultrasound for localized prostate cancer in 803 patients. *Eur Urol* 2010; 58: 559–66
- Poissonnier L, Chapelon JY, Rouviere O et al. Control of prostate cancer by transrectal HIFU in 227 patients. *Eur Urol* 2007; 51: 381–7
- Uchida T, Ohkusa H, Yamashita H et al. Five years experience of transrectal high-intensity focused ultrasound using the Sonablate device in the treatment of localized prostate cancer. *Int J Urol* 2006; 13: 228–33
- Warmuth M, Johansson T, Mad P. Systematic review of the efficacy and safety of high-intensity focussed ultrasound for the primary and salvage treatment of prostate cancer. *Eur Urol* 2010; 58: 803–15
- D'Amico AV, Moul J, Carroll PR, Sun L, Lubeck D, Chen MH. Cancer-specific mortality after surgery or radiation for patients with clinically localized prostate cancer managed during the prostate-specific antigen era. *J Clin Oncol* 2003; 21: 2163–72
- Roach M III, Hanks G, Thames H Jr et al. Defining biochemical failure following radiotherapy with or without hormonal therapy in men with clinically localized prostate cancer: recommendations of the RTOG-ASTRO Phoenix Consensus Conference. *Int J Radiat Oncol Biol Phys* 2006; 65: 965–74
- Rebillard X, Soulie M, Chartier-Kastler E et al. High-intensity focused ultrasound in prostate cancer; a systematic literature review of the French Association of Urology. *BJU Int* 2008; 101: 1205–13
- Heidenreich A, Aus G, Bolla M et al. EAU guidelines on prostate cancer. *Actas Urol Esp* 2009; 33: 113–26
- Ganzer R, Rogenhofer S, Walter B et al. PSA nadir is a significant predictor of treatment failure after High-Intensity Focussed Ultrasound (HIFU) treatment of localised prostate cancer. *Eur Urol* 2008; 53: 547–53
- Blana A, Brown SC, Chaussy C et al. High-intensity focused ultrasound for prostate cancer: comparative definitions of biochemical failure. *BJU Int* 2009; 104: 1058–62
- Abdel-Wahab M, Pollack A. Prostate cancer: defining biochemical failure in patients treated with HIFU. *Nat Rev Urol* 2010; 7: 186–7
- Fujisue Y, Azuma H, Inamoto T et al. Neoadjuvant hormonal therapy does not impact the treatment success of high-intensity focused ultrasound for the treatment of localized prostate cancer. *World J Urol* 2011; 29: 689–94
- Bill-Axelsson A, Holmberg L, Ruutu M et al. Radical prostatectomy versus watchful waiting in early prostate cancer. *N Engl J Med* 2011; 364: 1708–17
- Zelevsky MJ, Eastham JA, Cronin AM et al. Metastasis after radical prostatectomy or external beam radiotherapy for patients with clinically localized prostate cancer: a comparison of clinical cohorts adjusted for case mix. *J Clin Oncol* 2010; 28: 1508–13
- Bahn DK, Lee F, Badalament R, Kumar A, Greski J, Chernick M. Targeted cryoablation of the prostate: 7-year outcomes in the primary treatment of prostate cancer. *Urology* 2002; 60: 3–11
- Agarwal PK, Sadetsky N, Konety BR, Resnick MI, Carroll PR. Treatment failure after primary and salvage therapy for prostate cancer: likelihood, patterns of care, and outcomes. *Cancer* 2008; 112: 307–14
- Shoji S, Nakano M, Nagata Y, Usui Y, Terachi T, Uchida T. Quality of life following high-intensity focused ultrasound for the treatment of localized

prostate cancer: a prospective study. *Int J Urol* 2010; 17: 715–9

- 19 Blana A, Hierl J, Rogenhofer S et al. Factors predicting for formation of bladder outlet obstruction after high-intensity focused ultrasound in treatment of localized prostate cancer. *Urology* 2008; 71: 863–7
- 20 Netsch C, Pfeiffer D, Gross AJ. Development of bladder outlet obstruction after a single treatment of prostate cancer with high-intensity focused ultrasound: experience with 226 patients. *J Endourol* 2010; 24: 1399–403

Correspondence: Roman Ganzer, Department of Urology, University of Regensburg, Caritas St. Josef Medical Centre, Landshuter Straße 65, D – 93053 Regensburg, Germany.

e-mail: rganzer@caritasstjosef.de

Abbreviations: HIFU, high-intensity focused ultrasonography; PCa, prostate cancer; BDFS, biochemical disease-free survival; ADT, androgen deprivation therapy; SUI, stress urinary incontinence; CaPSURE, Cancer of the Prostate Strategic Urological Research Endeavor.

available at www.sciencedirect.com
journal homepage: www.europeanurology.com



European Association of Urology



Platinum Priority – Prostate Cancer
Editorial on pp. x–y of this issue

Multicentric Oncologic Outcomes of High-Intensity Focused Ultrasound for Localized Prostate Cancer in 803 Patients

Sebastien Crouzet^{a,b,*}, Xavier Rebillard^c, Daniel Chevallier^d, Pascal Rischmann^e, Gilles Pasticier^f, Gregory Garcia^g, Olivier Rouviere^{b,h}, Jean-Yves Chapelon^b, Albert Gelet^{a,b}

^a Department of Urology, Edouard Herriot Hospital, Lyon, France

^b Therapeutic Ultrasound Research Laboratory, Université de Lyon, INSERM, U556, Lyon, F-69003, France

^c Department of Urology, Beau Soleil Clinic, Montpellier, France

^d Department of Urology, Pasteur Hospital, Nice, France

^e Department of Urology, Ranguel Hospital, Toulouse, France

^f Department of Urology, Pellegrin Hospital, Bordeaux, France

^g Department of Urology, North Hospital, Marseille, France

^h Department of Radiology, Edouard Herriot Hospital, Lyon, France

Article info

Article history:

Accepted June 22, 2010

Published online ahead of
print on July 3, 2010

Keywords:

Ultrasound surgery
High-intensity focused
ultrasound
Localized prostate cancer

Abstract

Background: High-intensity focused ultrasound (HIFU) is an emerging treatment for select patients with localized prostate cancer (PCa).

Objectives: To report the oncologic outcome of HIFU as a primary care option for localized prostate cancer from a multicenter database.

Design, setting, and participants: Patients with localized PCa treated with curative intent and presenting at least a 2-yr follow-up from February 1993 were considered in this study. Previously irradiated patients were excluded from this analysis. In case of any residual or recurrent PCa, patients were systematically offered a second session. Kaplan-Meier analysis was performed to determine disease-free survival rates (DFSr).

Measurements: Prostate-specific antigen (PSA), clinical stage, and pathologic results were measured pre- and post-HIFU.

Results and limitations: A total of 803 patients from six urologic departments met the inclusion criteria. Stratification according to d'Amico's risk group was low, intermediate, and high in 40.2%, 46.3%, and 13.5% of patients, respectively. Mean follow-up was 42 ± 33 mo. Mean PSA nadir was 1.0 ± 2.8 ng/ml with 54.3% reaching a nadir of ≤0.3 ng/ml. Control biopsies were negative in 85% of cases. The overall and cancer-specific survival rates at 8 yr were 89% and 99%, respectively. The metastasis-free survival rate at 8 yr was 97%. Initial PSA value and Gleason score value significantly influence the DFSr. The 5- and 7-yr biochemical-free survival rates (Phoenix criteria) were 83–75%, 72–63%, and 68–62% ($p = 0.03$) and the additional treatment-free survival rates were 84–79%, 68–61%, and 52–54% ($p < 0.001$) for low-, intermediate-, and high-risk patients, respectively. PSA nadir was a major predictive factor for HIFU success: negative biopsies, stable PSA, and no additional therapy.

Conclusions: Local control and DFSr achieved with HIFU were similar to those expected with conformal external-beam radiation therapy (EBRT). The excellent cancer-specific survival rate is also explained by the possibility to repeat HIFU and use salvage EBRT.

© 2010 European Association of Urology. Published by Elsevier B.V. All rights reserved.

* Corresponding author. Urology and Transplantation Department, Edouard Herriot Hospital, 5 place d'Arsonval, 69437 Lyon Cedex 03, France. Tel. +33 472 110 583; Fax: +33 472 110 559. E-mail address: sebastien.crouzet@chu-lyon.fr (S. Crouzet).

0302-2838/\$ – see back matter © 2010 European Association of Urology. Published by Elsevier B.V. All rights reserved. doi:10.1016/j.eururo.2010.06.037

Please cite this article in press as: Crouzet S, et al. Multicentric Oncologic Outcomes of High-Intensity Focused Ultrasound for Localized Prostate Cancer in 803 Patients. Eur Urol (2010), doi:10.1016/j.eururo.2010.06.037

1. Introduction

In absence of data from large randomized trials, men with clinically localized prostate cancer (PCa) meet a dilemma when selecting treatment. Many treatment options are available and the morbidity associated with radical treatments is significant. The three main strategies are radical surgery, radiation therapy, and active surveillance. Results of a Scandinavian randomized study of radical surgery versus surveillance concluded that radical prostatectomy results in a reduction in distant metastases and disease-specific death among patients with clinically localized PCa not detected by prostate-specific antigen (PSA) screening [1]. The subgroup analyses by age showed that the benefit of radical prostatectomy was limited to men <65 yr. Systematic control biopsies after three-dimensional conformal external-beam radiation therapy (EBRT) demonstrated that local control of the disease was achieved only in 68% of patients, although biochemical-free survival is $\leq 59\%$ [2]. A well-defined protocol for active surveillance is still lacking and reliable criteria for active treatment are still unknown. High-intensity focused ultrasound (HIFU) is a minimally invasive option for localized PCa [3,4]. The goal of this study was to report the outcome of 803 consecutive patients who underwent HIFU as primary care option for localized PCa in six institutions and to determine the factors influencing the outcome. The morbidity was not analyzed in this study as it has already been published [5].

2. Materials and methods

HIFU propagates ultrasound waves generated by a spherical transducer placed in the rectum. HIFU works by focusing high-power acoustic waves on a specific focal point to produce temperatures of 85 °C [6]. These temperatures are high enough to cause cellular disruption and coagulative necrosis at the focal point of the HIFU acoustic waves.

All patients were treated using the Ablatherm HIFU device (EDAP SA, Vaulx-en-Velin, France). From 1993 to 1999, the patients were treated with prototype devices. After 2000, patients were treated with the first commercially available device (Ablatherm Maxis), and since 2005 treatment has been performed using the second commercially available device (Ablatherm Integrated Imaging), which allows a real-time control of the therapy [7].

To reduce duration of catheterization, the HIFU procedure was standardized in 2000: A transurethral resection of the prostate (TURP) is performed immediately prior to the HIFU session, under the same anesthesia in smaller glands (≤ 35 ml), and as a separate treatment 4–6 wk after TURP in larger glands [8,9]. The whole prostate gland is treated with a 4–6-mm safety margin for the treatment of the apex. This standardized HIFU procedure dramatically simplifies the outcome by reducing catheter time and rate of urinary infections [8,9].

The data were collected prospectively in a multicenter database approved by the Commission Nationale de l'Informatique et des Libertés (CNIL; an independent French administrative authority whose mission is to ensure that data privacy laws are applied to the collection, storage, and use of personal data). Patients treated consecutively between 1993 and January 2007 in six urologic departments were included in this database.

For this study, the patient selection was based on the following criteria: clinical stage T1–T2, N0, M0, no previous radical treatment for PCa (radical

prostatectomy, EBRT, or brachytherapy), and at least 2 yr of follow-up. All patients were not suitable candidates for radical surgery according to the age and general status. Patients treated by neoadjuvant hormone therapy were excluded from the study.

All patients were regularly assessed based on the following criteria: baseline and post-HIFU PSA levels at 3, 6, and 12 mo, and then every 6 mo, and prostate sextant biopsies performed before inclusion and 6 mo after HIFU treatment, regardless of PSA level. Additional control biopsies were performed during follow-up in cases of rising PSA (three successive rises in PSA level). In case of positive prostate biopsy during follow-up without evidence of metastasis, HIFU retreatment was performed. The requirement for an additional treatment after repeated HIFU was defined depending on evidence of local relapse. EBRT or hormonal deprivation was administered according to the general status and the life expectancy of each patient.

For disease-free calculation, three different criteria were used to calculate Kaplan-Meier survival curves. We chose the Phoenix criteria for calculation of the biochemical disease-free survival rate (BFSR) to compare the HIFU results with the EBRT results [10]. We also calculated the additional treatment survival rate (the occurrence to define failure is the start of a salvage treatment). Finally, we present a survival curve using the combination of the two previous criteria because in this HIFU cohort, control biopsies were often performed before the PSA increase up to nadir plus 2 ng or at the time of a salvage treatment for local relapse evidenced by control biopsy.

Statistical analyses were carried out with SPSS statistical software v.16 (SPSS, Chicago, IL, USA). Depending on distributions, parametric and nonparametric tests were applied.

Survival curves were based on Kaplan-Meier models and the log-rank test was used for univariate comparisons. Actuarial survival rates were based on life table methods.

For multivariate analysis, the Cox proportional hazards regression model was used to estimate the prognostic relevance of age, prostate volume, PSA, clinical stage, positive biopsy rate, Gleason score, and nadir PSA on disease progression. All *p* values <0.05 reflected statistically significant differences.

3. Results

3.1. Patient characteristics

A total of 803 patients fulfilled the inclusion criteria and were considered for analysis (Montpellier: 99; Marseille: 20; Lyon: 579; Bordeaux: 19; Nice: 67; Toulouse: 19). Baseline characteristics are summarized in Table 1. The total number of cases analyzed was 1457 patients. Patients treated by neoadjuvant hormone therapy and were excluded from the study ($n = 438$). Another group of 216 patients was excluded from the study due to the following characteristics: T3 or higher, N+, M+, missing stage, PSA >50 ng/ml, missing Gleason, and follow-up <2 yr.

The mean follow-up period for the entire cohort was 42 \pm 33 mo. The treatments were achieved with the prototypes in 80 patients, with the Ablatherm Maxis in 446 and with the Ablatherm Integrated Imaging in 277. In the two last subgroups, the HIFU session was combined with a TURP. The mean number of HIFU sessions was 1.4 \pm 0.6 (one session: 521 (64.9%) patients; two sessions: 255 (31.7%) patients; three or more sessions: 27 (3.4%) patients). On average, 496 shots were delivered during the first HIFU session, corresponding to a treated volume of 26.8 ml (ie, an average of 109% of the prostate volume at the time of the treatment).

Table 1 – Baseline characteristics of 803 patients with localized cancer following treatment with high-intensity focused ultrasound

Mean age, yr (median)	70.8 ± 5.6 (71)
Mean PSA, ng/ml (median)	9.1 ± 5.9 (7.7)
Mean prostate volume, ml (median)	24.5 ± 10.0 (23.0)
Stage, n (%)	
T1	481 (59.9)
T2	322 (40.1)
Gleason score, n (%)	
≤6	510 (63.5)
7	242 (30.1)
≥8	48 (6.0)
Undefined	3 (0.4)
Pre-HIFU d'Amico's risk group (2003), n (%)	
Low	323 (40.2)
Intermediate	372 (46.3)
High	108 (13.5)

PSA = prostate-specific antigen; HIFU = high-intensity focused ultrasound.

Table 2 – Prostate-specific antigen nadir after high-intensity focused ultrasound

	Overall
Mean nadir PSA, ng/ml (median)	1.0 ± 2.8 (0.25)
Mean time to nadir, wk (median)	12.9 ± 11.0 (9.0)
Nadir PSA, ng/ml (%)	
≤0.3	436 (54.3)
0.3–1	172 (21.4)
>1	179 (22.3)
Not determined	16 (1.9)

PSA = prostate-specific antigen; HIFU = high-intensity focused ultrasound.

3.2. Pathologic and morphologic results

After the HIFU treatment, the prostate volume (assessed by transrectal ultrasound) decreased sharply from 24.5 ± 10 ml to 13.6 ± 13.1 ml. The pre-HIFU prostate volume measurement was performed just before the HIFU treatment and after the TURP. According to the small prostate volume after HIFU, a minimum of 6 to 12 random control core biopsies were usually used to evaluate the local control of the cancer. Post-HIFU biopsies after the last HIFU sessions were only available in 589

(73.3%) patients. Control biopsies were negative in 459 patients (77.9%) and positive in 130 patients (22.1%). The negative control biopsy rate for low-, intermediate-, and high-risk patients were, respectively, 84.9%, 73.5%, and 72.0% ($p = 0.003$).

3.3. Biochemical results

The PSA nadir was reached within 6 mo after HIFU in all patients (mean nadir time achievement: 12.9 ± 11.0 wk). The mean PSA nadir was 1.0 ± 2.8 ng/ml, with a median of 0.25 ng/ml. PSA nadir values are summarized in Table 2. For the overall population, 436 patients (54.3%) presented a nadir PSA ≤ 0.3 ng/ml. Table 3 reports comparative outcome according to the development of HIFU technology between 1993 and 2006.

3.4. Survival rates

The overall and cancer-specific survival rates (CSSR) at 8 yr were 89% and 99%, respectively (Figs. 1 and 2). The metastasis-free survival rate was 97% at 8 yr (Fig. 3).

3.4.1. Disease-free survival rates

The 5-yr and 7-yr BFSR (Phoenix criteria) for low-, intermediate-, and high-risk patients were, respectively, 83–75%, 72–63%, and 68–62% ($p = 0.03$). In the same groups of patients, the 5-yr and 7-yr additional treatment-free survival rates were, respectively, 84–79%, 68–61%, and 52–54% ($p < 0.001$). By combining those two criteria, the DFSR at 5 yr and 7 yr were 72–62%, 56–46%, and 47–39% ($p < 0.001$) for low-, intermediate-, and high-risk patients, respectively (Figs. 4–6).

3.5. Clinical outcome

All patients presenting with a significantly rising PSA (Phoenix criteria) level received an additional treatment, whatever the local control and biopsy results. A total of 182 patients with relapse underwent salvage therapy, either with EBRT (84 patients) or androgen deprivation (98 patients). Hormone deprivation was used in patients without biopsy-proven local relapse or with poor general status; radiation therapy was performed in patients with demonstrated local recurrence and long life expectancy.

Table 3 – Comparative outcome according to the evolution of technology in patients treated with high-intensity focused ultrasound technology

	Before 2000	2000–2004	2005–2007	p value
Nb HIFU sessions	n (%)	n (%)	n (%)	
One session	26 (32.5)	259 (58.1)	236 (85.2)	$p < 0.001$
Two sessions	36 (45.0)	178 (39.9)	41 (14.8)	
Three or more sessions	18 (22.5)	9 (2.0)	0 (0.0)	
Total	80	446	277	
Nadir PSA, ng/ml	n (%)	n (%)	n (%)	
≤0.3	37 (46.3)	241 (54.0)	158 (57.0)	$p < 0.001$
0.3–1	18 (22.5)	101 (22.7)	53 (19.1)	
>1	25 (31.2)	100 (22.4)	54 (19.5)	
Not determined	0 (0.0)	4 (0.9)	12 (4.3)	

PSA = prostate-specific antigen; HIFU = high-intensity focused ultrasound.

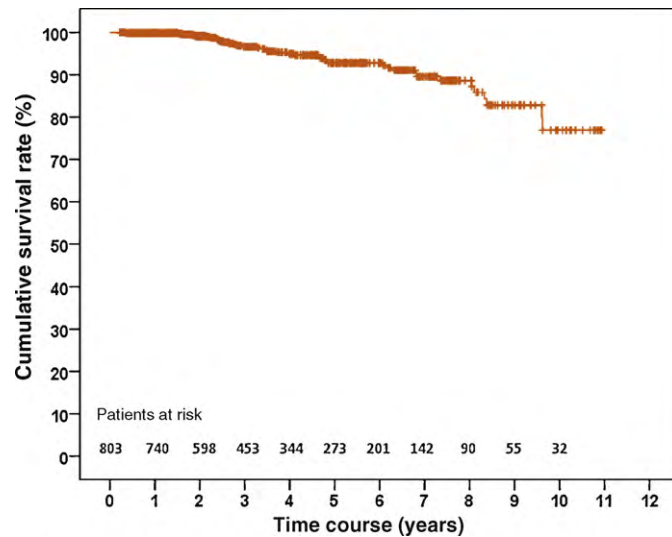


Fig. 1 – Overall survival rates in 803 patients with localized prostate cancer following treatment with high-intensity focused ultrasound.

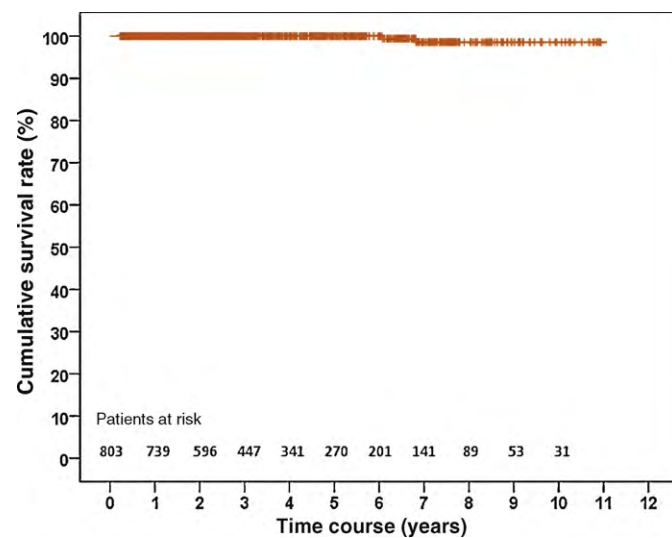


Fig. 2 – Cancer-specific survival rates in 803 patients with localized prostate cancer following treatment with high-intensity focused ultrasound.

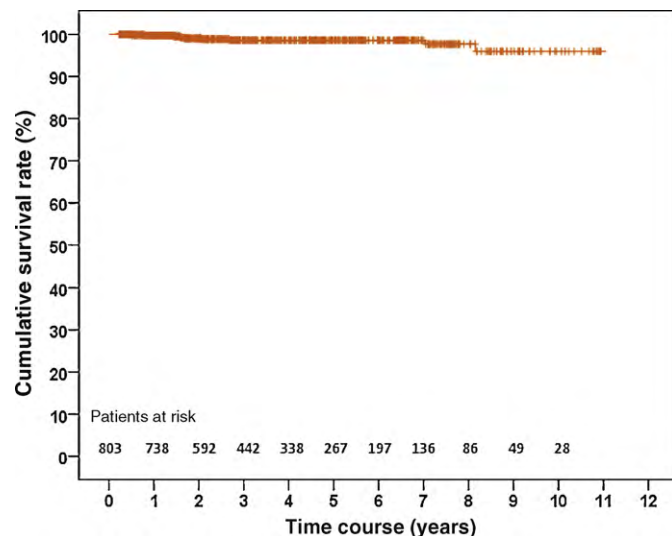


Fig. 3 – Metastasis-free survival rates in 803 patients with localized prostate cancer following treatment with high-intensity focused ultrasound.

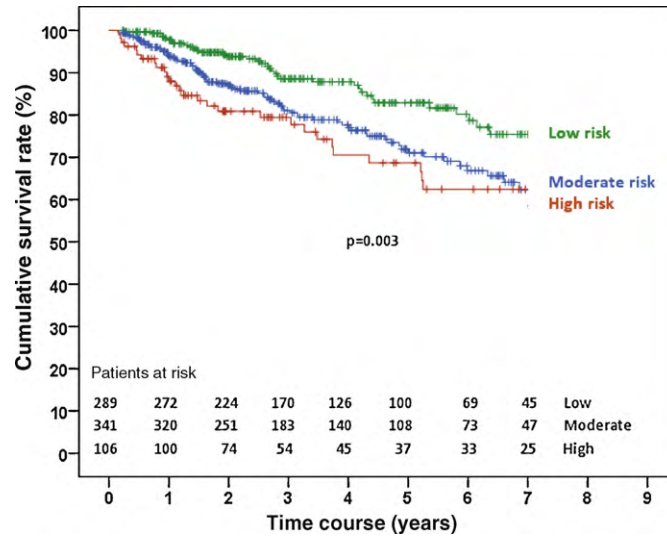


Fig. 4 – Biochemical-free survival rates in patients with localized prostate cancer following treatment with high-intensity focused ultrasound, according to D'Amico risk group.

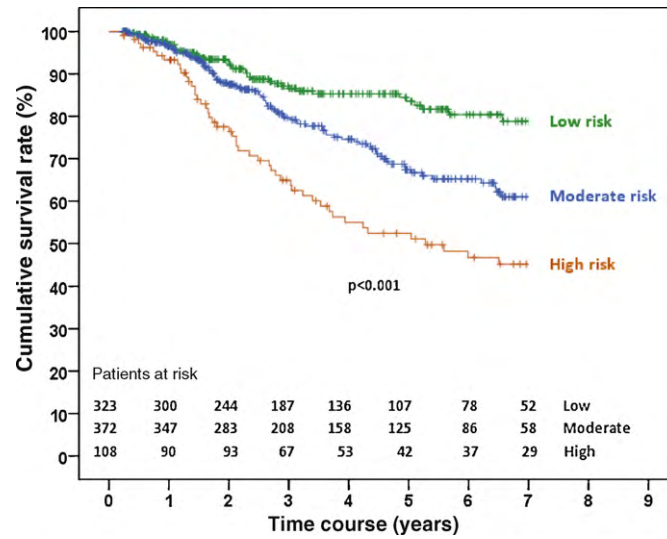


Fig. 5 – Adjuvant treatment-free survival rates in patients with localized prostate cancer following treatment with high-intensity focused ultrasound.

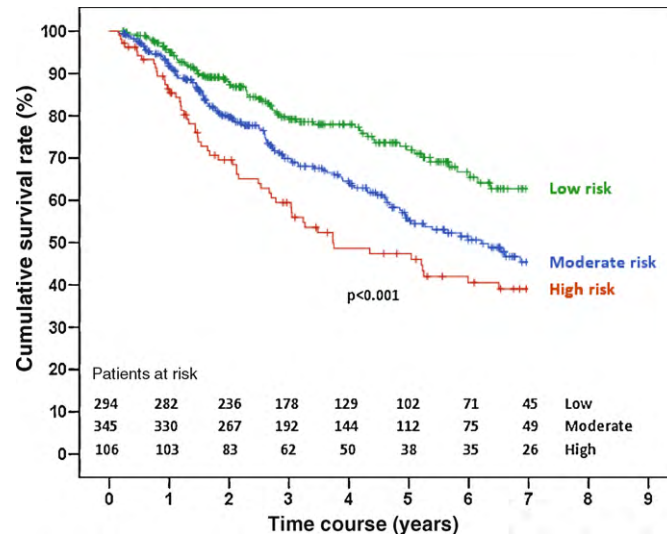


Fig. 6 – Disease-free survival rates using combined criteria in patients with localized prostate cancer following treatment with high-intensity focused ultrasound.

Table 4 – Prognostic factors of disease progression (biochemical and adjuvant treatment) in patients treated with high-intensity focused ultrasound technology: results of the univariate analysis and Cox model

Prognostic factors	Univariate risk ratio	Univariate 95% CI	Univariate p value	Multivariate risk ratio	Multivariate 95% CI	Multivariate p value
Age	1.02	1.00–1.04	0.083	0.99	0.96–1.02	0.524
Gleason score						
≤6	1	–	–	1	–	–
7	1.25	0.95–1.64	0.109	1.11	0.77–1.60	0.564
≥8	2.25	1.52–3.31	<0.001	1.90	1.20–3.03	0.007
PSA, ng/ml						
≤4	1	–	–	1	–	–
4–10	2.91	1.68–5.06	<0.001	2.49	1.24–4.97	0.010
>10	4.93	2.82–8.60	<0.001	3.83	1.90–7.72	<0.001
Stage						
T1	1	–	–	1	–	–
T2	1.06	0.83–1.36	0.632	1.01	0.74–1.38	0.951
Prostate volume, ml						
≤25	1	–	–	1	–	–
>25	1.16	0.90–1.50	0.259	0.97	0.71–1.33	0.865
Positive biopsies						
≤33%	1	–	–	1	–	–
>33%	1.21	0.90–1.63	0.211	1.18	0.85–1.64	0.314

PSA = prostate-specific antigen; CI = confidence interval.

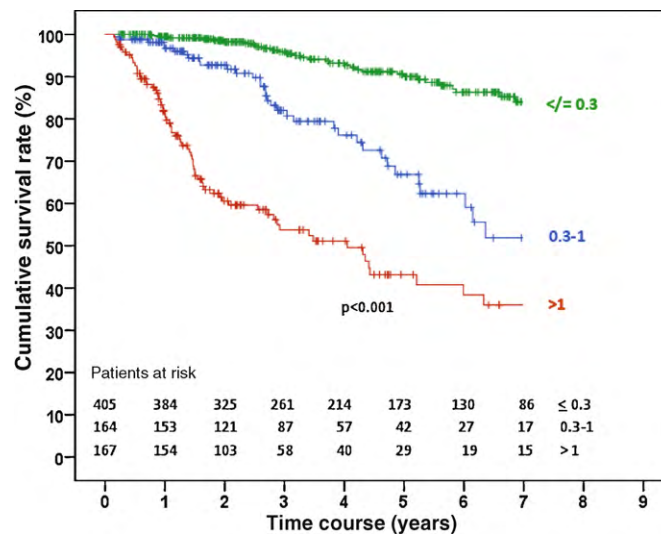


Fig. 7 – Biochemical-free survival rates in patients with localized prostate cancer following treatment with high-intensity focused ultrasound depending on prostate-specific antigen nadir levels.

3.6. Outcome prognostic factors

In the multivariate analysis (Table 4), only the PSA level and the Gleason score before the HIFU treatment was significantly linked to the rate of disease progression. Age, clinical stages, prostate volume, and percentage of positive biopsies before HIFU did not reach statistical significance. PSA nadir was a major predictive factor for HIFU success. The BFSR at 5 yr and 7 yr were 91% and 84%, respectively, for a PSA nadir ≤0.3 ng/ml, 67% and 51% for a PSA nadir of 0.31–1 ng/ml, and 42% and 35% for a PSA nadir >1 ng/ml (p < 0.001) (Fig. 7).

4. Discussion

The goal of PCa treatment is to reduce the risk of local recurrence, biochemical disease-free rate, distant metastasis, and, finally, to decrease the risk of cancer-specific death.

4.1. Local control

In this multicenter study, HIFU resulted in local control (negative biopsies) in 77.9% of our patients, which correlates well with previous published papers about both the Ablatherm device and the Sonablate device (Focus

Surgery Inc, Indianapolis, IN, USA) [11–14]. This is similar to the results reported after radiation therapy. After conformal EBRT, relatively high positive biopsy rates (21–32%) were recently reported [2,15,16]. Local control of the tumor is a major predictor of long-term disease control. In the study of Zapatero et al, multivariate analysis showed that biopsy status after EBRT at 24–36 mo was an independent predictor of DFSR and of clinical failure-free survival [16]. Similarly, in the study of Zelefski et al, multivariate analysis indicated that the strongest predictor of biochemical failure, distant metastasis, and PCa death was post-treatment biopsy status [2].

4.2. Disease-free survival rate

The BFSR after HIFU were similar to DFSR reported after conformal EBRT, especially for intermediate- and high-risk patients even with dose escalation [17,18]. However, only prospective studies or matched-pair analysis would allow a direct comparison between HIFU and EBRT. Similar to EBRT, the BFSR after HIFU was significantly influenced according to the d'Amico risk group [19]. The pre-HIFU prostate volume (<25 vs >25 ml) did not significantly influence the BFSR, even though the mean prostate volume before HIFU in this study was relatively small (median: 23 ml).

However, the Phoenix criteria are not very accurate for post-HIFU DFSR calculation: The Stuttgart criteria nadir plus 1.2 ng is certainly more sensitive [20]. In fact, in this HIFU cohort, control biopsies were often performed before the PSA increase to nadir plus 2 ng (usually at plus 1 ng above the nadir). The additional treatment survival rate is more accurate to present the real clinical outcomes after HIFU because the start of an additional treatment clearly defines clinical failure. The combination of the two previous criteria represents the real HIFU outcomes.

4.3. Early detection of recurrence

Unlike radiation therapy, HIFU allows an early feedback on treatment efficacy because the PSA nadir value was achieved within 3–6 mo after the treatment and, in addition, the phenomenon of PSA bounce is never observed after HIFU. Moreover, nadir was a major predictive factor for HIFU success [21,22]. Currently, in clinical practice in most institutions, the routine PSA cut-off value for early control biopsies is 0.3 ng/ml. Early detection of relapse significantly influenced the outcome of either the second HIFU session or post-HIFU salvage radiation therapy [23]. The predictive factor of PSA nadir value was also demonstrated after EBRT with an end point of 1.5 ng/ml, but the nadir after EBRT is usually achieved after 18 mo [24]. However, the use of control biopsy after EBRT is not common before a rise of PSA at a value of nadir plus 2, whatever the nadir value was. Color Doppler or dynamic contrast-enhanced magnetic resonance imaging have recently shown interesting results in detecting and localizing local recurrences after HIFU ablation. In the future these methods might improve treatment outcome by allowing early detection of recurrences [25–27].

4.4. Distant metastasis and cancer-specific survival rate

In this multicenter study, the metastasis-free survival rate was 97% and the CSSR was 99% at 8 yr. Those results may probably be explained by the good local control of the cancer achieved after HIFU and later using salvage radiotherapy in patients who presented a local relapse. Salvage EBRT after HIFU is able to improve the survival outcomes of a patient with a local recurrence after HIFU [23]. Patients with biopsy-proven local relapse after HIFU (84 patients) received a salvage radiation therapy that may explain these results. After conformal EBRT, Zelefski et al reported that 10-yr PSA relapse-free survival rates in patients with negative and severe treatment-effect biopsy outcomes were 59% and 49%, respectively; while in patients with positive biopsy, the corresponding outcome was only 3% [2]. Similarly, in the Zelefski et al study, the 10-yr metastasis-free survival rate in patients with negative/severe treatment-effect biopsy outcomes was 90% and the corresponding outcome in patients with positive treatment biopsy outcomes was 69%.

4.5. Improvement of the results according to technical progress

The current results were obtained in patients treated with prototypes, and the first and second generations of a commercialized HIFU device. It is difficult to compare the results achieved with the different devices because several technical improvements have been made. The last generation of the device allows real-time control of the treatment [7]. It is possible to define more accurately the apex and to determine a better treatment plan with an optimization of the targeted volume. The percentage of patients who reached a nadir value <0.3 ng increased progressively with a simultaneous reduction of the number of sessions and the number of patients with a nadir PSA >1 ng/ml, which favors better outcomes (Table 3). However, the implementation of a TURP prior to HIFU might contribute as much as technical developments to the improvement of the results. Preliminary data suggest that contrast-enhanced ultrasound can reliably show, immediately after the HIFU ablation, the location and amount of tissue that has not been destroyed after a first session of HIFU [28]. If these results are confirmed, this could allow an immediate retreatment of the incompletely destroyed areas.

5. Conclusions

Local control and DFSR achieved with HIFU were similar to those expected with conformal external beam radiation. HIFU can be repeated when necessary several months or several years after the first session and can also be followed by a salvage radiation therapy. This probably explains the excellent middle-term CSSR achieved in this multicenter study despite the presence of intermediate- and high-risk patients.

Author contributions: Sebastien Crouzet had full access to all the data in the study and takes responsibility for the integrity of the data and the accuracy of the data analysis.

Study concept and design: Gelet, Crouzet.

Acquisition of data: Rebillard, Chevallier, Rischmann, Pasticier, Garcia, Gelet.

Analysis and interpretation of data: Crouzet, Gelet, Chapelon.

Drafting of the manuscript: Crouzet, Gelet, Rouviere.

Critical revision of the manuscript for important intellectual content: Gelet, Rouviere.

Statistical analysis: Crouzet, Gelet.

Obtaining funding: None.

Administrative, technical, or material support: None.

Supervision: Gelet.

Other (specify): None.

Financial disclosures: I certify that all conflicts of interest, including specific financial interests and relationships and affiliations relevant to the subject matter or materials discussed in the manuscript (eg, employment/affiliation, grants or funding, consultancies, honoraria, stock ownership or options, expert testimony, royalties, or patents filed, received, or pending), are the following: Albert Gelet is a lecturer and consultant for EDAP (Vaulx-en-Velin, France).

Funding/Support and role of the sponsor: None.

References

- [1] Bill-Axelsson A, Holmberg L, Filen F, et al. Radical prostatectomy versus watchful waiting in localized prostate cancer: the Scandinavian Prostate Cancer Group-4 randomized trial. *J Natl Cancer Inst* 2008; 100:1144–54.
- [2] Zelefsky MJ, Reuter VE, Fuks Z, Scardino P, Shippy A. Influence of local tumor control on distant metastases and cancer related mortality after external beam radiotherapy for prostate cancer. *J Urol* 2008;179:1368–73, discussion 1373.
- [3] Poissonnier L, Murata FJ, Chapelon JY, Gelet A. Indications, techniques and outcomes of high-intensity focused ultrasound (HIFU) for the treatment of localized prostate cancer. *Ann Urol (Paris)* 2007;41: 237–53.
- [4] Blana A, Walter B, Rogenhofer S, Wieland WF. High-intensity focused ultrasound for the treatment of localized prostate cancer: 5-year experience. *Urology* 2004;63:297–300.
- [5] Blana A, Rogenhofer S, Ganzer R, et al. Morbidity associated with repeated transrectal high-intensity focused ultrasound treatment of localized prostate cancer. *World J Urol* 2006;24:585–90.
- [6] Gelet A, Chapelon JY, Margonari J, et al. Prostatic tissue destruction by high-intensity focused ultrasound: experimentation on canine prostate. *J Endourol* 1993;7:249–53.
- [7] Pichardo S, Gelet A, Curriel L, Chesnais S, Chapelon JY. New integrated imaging high intensity focused ultrasound probe for transrectal prostate cancer treatment. *Ultrasound Med Biol* 2008;34:1105–16.
- [8] Chaussy C, Thuroff S. The status of high-intensity focused ultrasound in the treatment of localized prostate cancer and the impact of a combined resection. *Curr Urol Rep* 2003;4:248–52.
- [9] Vallancien G, Prapotnich D, Cathelineau X, Baumert H, Rozet F. Transrectal focused ultrasound combined with transurethral resection of the prostate for the treatment of localized prostate cancer: feasibility study. *J Urol* 2004;171:2265–7.
- [10] Roach III M, Hanks G, Thames Jr H, et al. Defining biochemical failure following radiotherapy with or without hormonal therapy in men with clinically localized prostate cancer: recommendations of the RTOG-ASTRO Phoenix Consensus Conference. *Int J Radiat Oncol Biol Phys* 2006;65:965–74.
- [11] Poissonnier L, Chapelon J-Y, Rouvière O, et al. Control of prostate cancer by transrectal HIFU in 227 patients. *Eur Urol* 2007;51: 381–7.
- [12] Blana A, Murat FJ, Walter B, et al. First analysis of the long-term results with transrectal HIFU in patients with localised prostate cancer. *Eur Urol* 2008;53:1194–203.
- [13] Uchida T, Ohkusa H, Nagata Y, et al. Treatment of localized prostate cancer using high-intensity focused ultrasound. *BJU Int* 2006;97: 56–61.
- [14] Chaussy C, Thuroff S, Rebillard X, Gelet A. Technology insight: high-intensity focused ultrasound for urologic cancers. *Nat Clin Pract Urol* 2005;2:191–8.
- [15] Pollack A, Zagars GK, Antolak JA, Kuban DA, Rosen II. Prostate biopsy status and PSA nadir level as early surrogates for treatment failure: analysis of a prostate cancer randomized radiation dose escalation trial. *Int J Radiat Oncol Biol Phys* 2002;54:677–85.
- [16] Zapatero A, Minguez R, Nieto S, Martín de Vidales C, García-Vicente F. Post-treatment prostate biopsies in the era of three-dimensional conformal radiotherapy: what can they teach us? *Eur Urol* 2009;55:902–10.
- [17] Pollack A, Hanlon A, Horwitz EM, et al. Radiation therapy dose escalation for prostate cancer: a rationale for IMRT. *World J Urol* 2003;21:200–8.
- [18] Kuban DA, Tucker SL, Dong L, et al. Long-term results of the MD Anderson randomized dose-escalation trial for prostate cancer. *Int J Radiat Oncol Biol Phys* 2008;70:67–74.
- [19] Zelefsky MJ, Yamada Y, Fuks Z, et al. Long-term results of conformal radiotherapy for prostate cancer: impact of dose escalation on biochemical tumor control and distant metastases-free survival outcomes. *Int J Radiat Oncol Biol Phys* 2008;71:1028–33.
- [20] Blana A, Brown SC, Chaussy C, et al. High-intensity focused ultrasound for prostate cancer: comparative definitions of biochemical failure. *BJU Int* 2009;104:1058–62.
- [21] Uchida T, Illing RO, Cathcart PJ, Emberton M. To what extent does the prostate-specific antigen nadir predict subsequent treatment failure after transrectal high-intensity focused ultrasound therapy for presumed localized adenocarcinoma of the prostate? *BJU Int* 2006; 98:537–9.
- [22] Ganzer R, Rogenhofer S, Walter B, et al. PSA nadir is a significant predictor of treatment failure after high-intensity focussed ultrasound (HIFU) treatment of localised prostate cancer. *Eur Urol* 2008; 53:547–53.
- [23] Pasticier G, Chapet O, Badet L, et al. Salvage radiotherapy after high-intensity focused ultrasound for localized prostate cancer: early clinical results. *Urology* 2008;72:1305–9.
- [24] Zelefsky MJ, Shi W, Yamada Y, et al. Postradiotherapy 2-year prostate-specific antigen nadir as a predictor of long-term prostate cancer mortality. *Int J Radiat Oncol Biol Phys* 2009;75: 1350–6.
- [25] Rouvière O, Mège-Lechevallier F, Chapelon J-Y, et al. Evaluation of color Doppler in guiding prostate biopsy after HIFU ablation. *Eur Urol* 2006;50:490–7.
- [26] Rouvière O, Girouin N, Glas L, et al. Prostate cancer transrectal HIFU ablation: detection of local recurrences using T2-weighted and dynamic contrast-enhanced MRI. *Eur Radiol* 20:48–55.
- [27] Rouvière O, Vitry T, Lyonnet D. Imaging of prostate cancer local recurrences: why and how? *Eur Radiol* 20:1254–66.
- [28] Wink M, Frauscher F, Cosgrove D, et al. Contrast-enhanced ultrasound and prostate cancer; a multicentre European research coordination project. *Eur Urol* 2008;54:982–93.

Salvage high-intensity focused ultrasound (HIFU) for locally recurrent prostate cancer after failed radiation therapy: Multi-institutional analysis of 418 patients

Sebastien Crouzet*, Andreas Blana†, Francois J. Murat‡, Gilles Pasticier§, Stephen C. W. Brown¶, Giario N. Conti***, Roman Ganzer††, Olivier Chapet†††, Albert Gelet*, Christian G. Chaussy††, Cary N. Robertson§§, Stefan Thuroff¶¶ and John F. Ward***

*Department of Urology, Edouard Herriot Hospital, Lyon, France, †Department of Urology, Fuerth Hospital, Fürth, Germany, ‡Urology Department, Val d'Ouest Hospital, Ecully, §Department of Urology, CHU Pellegrin, Bordeaux, France, ¶Department of Urology, Stepping Hill Hospital, Stockport, UK, ***Department of Urology, St. Anna Hospital, Como, Italy, ††Department of Urology, University of Regensburg, Regensburg, Germany, †††Department of Radiation Oncology, Lyon Sud Hospital, Pierre Bénite, France, §§Department of Urology, Duke University, Durham, NC, USA, ¶¶Department of Urology, Harlaching Hospital, Munich, Germany, and ***Department of Urology, M. D. Anderson Cancer Center, Houston, TX, USA

S.C and A.B. shared first author.

Objective

To report the oncological outcome of salvage high-intensity focused ultrasound (S-HIFU) for locally recurrent prostate cancer after external beam radiotherapy (EBRT) from a multicentre database.

Patients and Methods

This retrospective study comprises patients from nine centres with local recurrent disease after EBRT treated with S-HIFU from 1995 to 2009. The biochemical failure-free survival (bFFS) rate was based on the 'Phoenix' definition (PSA nadir + 2 ng/mL). Secondary endpoints included progression to metastasis and cancer-specific death. Kaplan–Meier analysis was performed examining overall (OS), cancer-specific (CSS) and metastasis-free survival (MFS). Adverse events and quality of life status are reported.

Results

In all, 418 patients with a mean (SD) follow-up of 3.5 (2.5) years were included. The mean (SD) age was 68.6 (5.8) years and the PSA level before S-HIFU was 6.8 (7.8) ng/mL. The median PSA nadir after S-HIFU was 0.19 ng/mL. The OS,

CSS and MFS rates at 7 years were 72%, 82% and 81%, respectively. At 5 years the bFFS rate was 58%, 51% and 36% for pre-EBRT low-, intermediate- and high-risk patients, respectively. The 5-year bFFS rate was 67%, 42% and 22% for pre-S-HIFU PSA level ≤ 4 , 4–10 and ≥ 10 ng/mL, respectively. Complication rates decreased after the introduction of specific post-RT parameters: incontinence (grade II or III) from 32% to 19% ($P = 0.002$); bladder outlet obstruction or stenosis from 30% to 15% ($P = 0.003$); recto-urethral fistula decreased from 9% to 0.6% ($P < 0.001$). Study limitations include being a retrospective analysis from a registry with no control group.

Conclusion

S-HIFU for locally recurrent prostate cancer after failed EBRT is associated with 7-year CSS and MFS rates of $>80\%$ at a price of significant morbidity. S-HIFU should be initiated early following EBRT failure

Keywords

high-intensity focused ultrasound, PSA, biochemical failure, follow-up, salvage therapy, #ProstateCancer

Introduction

A significant proportion of patients experience a recurrence after external beam radiotherapy (EBRT) [1,2]. The recurrence rate after EBRT at 5 years in a multicentre study

was reported to be 39% and 28% for 70 and 80 Gy, respectively [3]. After intensity-modulated RT, with a median dose of 7.6 Gy, biochemical survival rates at 9 years were 77.4%, 69.6% and 53.3% for low-, intermediate- and high-risk patients, respectively [4]. In the Cancer of the Prostate

Strategic Urologic Research Endeavor (CaPSURE) population, >90% of patients with recurrent prostate cancer received palliative androgen-deprivation therapy (ADT), which suppresses PSA levels but with absolutely no chance of cure [5]. Salvage radical prostatectomy (SRP) series have reported 10-year biochemical failure-free (bFFS), metastasis-free (MFS), and cancer-specific (CSS) survival probabilities of 37%, 77%, and 83%, respectively [6]. However, SRP is associated with significant morbidity especially urinary incontinence [7].

High-intensity focused ultrasound (HIFU) has been used as a primary treatment for prostate cancer for over a decade [8–10]. More recently, the technology was evaluated as a salvage therapy for locally recurrent prostate cancer after EBRT in patients without evidence of metastasis [11]. Based on data from 290 consecutive patients, the 7-year estimated CSS rate after salvage HIFU (S-HIFU) was 80%. The progression free-survival rates were 53%, 42% and 25% for low-, intermediate-, and high-risk patients (D'Amico), respectively, suggesting that S-HIFU is a valuable therapy for radio-recurrent prostate cancer [12]. S-HIFU is intended to completely ablate all prostate tissue that remains after primary EBRT. In the present multicentre, registry study, we evaluated the oncological outcomes and the associated morbidity of S-HIFU along with the preoperative prognostics that predict oncological success for the first time in a large cohort.

Patients and Methods

The Ablatherm (EDAP-TMS, Lyon, France) treatment registry (@-Registry™) is a secure on-line database for patients who have undergone prostate HIFU using the Ablatherm device. The @-Registry was specifically designed to collect de-identified pre- and post-treatment information. Data from 3218 consecutively treated patients entered in the @-Registry between December 2005 and June 2009 were reviewed for this retrospective analysis.

Patients who underwent total gland S-HIFU for locally recurrent prostate cancer (T1–2) after EBRT were included in the analysis. The inclusion criteria were a biochemical failure [American Society for Therapeutic Radiology and Oncology (ASTRO) before 2006 and then Phoenix definition) [13,14], a positive post-EBRT biopsy, and a negative metastatic evaluation. Metastatic evaluation included a bone scan and an abdominopelvic CT, and most patients also received a prostatic MRI. All patients who received ADT within 90 days of S-HIFU were excluded from the analysis.

Contraindications for S-HIFU included anal/rectal stenosis and a rectal wall thickness >6 mm measured in by TRUS.

Total gland S-HIFU was performed using the Ablatherm HIFU device. The prostate was treated in two to four overlapping blocks from the apex to the base. Between 1995

and March 2002, standard treatment parameters were used. This entailed 100% acoustic power with a 6-s pulse of energy to create each discrete HIFU lesion with a 4-s delay between each shot. Starting in March 2002, specific post-RT parameters were adopted (4-s pulse, 6-s waiting period, 90% of the acoustic power) due to the high rate of morbidity with the protocol before 2002. These were developed considering the decreased vascularity of the previously irradiated tissue. The goal was to optimise the thermal dose delivered within the gland while minimising the possible damage probability to surrounding tissues, especially the rectal wall, which is caused by conductive heat transfer.

S-HIFU treatments were usually performed under spinal anaesthesia or general anaesthesia. Most of the patients underwent a bladder neck incision to reduce the risk of urinary retention and BOO after S-HIFU. TURP was performed if a median lobe was present. TURP and S-HIFU were performed during a single session, and patients were usually discharged from hospital 3–5 days after the procedure with or without a urinary catheter. No adjuvant ADT was used after S-HIFU.

Patient follow-up included clinical and biochemical evaluations every 3 months for the first year and every 6 months thereafter. Initially, treated patients first underwent systematic biopsies at 3 months. Additional biopsies were taken in cases of rising PSA during follow-up. Since 2008, when the PSA nadir was <0.2 ng/mL, systematic control biopsies have not taken [15]. Control biopsies were taken only in cases of rising PSA. A complete diagnostic evaluation was conducted in cases of biochemical relapse after S-HIFU. A second S-HIFU session was offered when an exclusively local recurrence was identified. Side-effects were systematically evaluated and recorded. Urinary incontinence was graded according to the Ingelman–Sundberg score (strong, moderate, minimal effort: grade I, grade II and grade III, respectively) [16].

The CSS, MFS and bFFS rates were estimated using the Kaplan–Meier method. Biochemical failure was defined as an increase of ≥ 2 ng/mL above the PSA nadir (Phoenix definition) [14]. The salvage treatment-free survival rate was defined as the time of ADT initiation. The bFFS was stratified according to the pre-radiotherapy D'Amico's risk group, the pre-S-HIFU PSA level (≤ 4 , 4.1–10, or >10 ng/mL), the pre-S-HIFU estimated Gleason score (≤ 6 , 7, ≥ 8) and the administration of ADT prior or during EBRT. The Kaplan–Meier method was also used to estimate the bFFS curves according to the different categories of each factor compared when using the log-rank test. A Cox model was used for multivariate analysis to identify independent factors linked to the risk of failure. Analysis was performed using the statistical software S-plus version 6.2. A $P < 0.05$ was chosen to identify statistically significant differences.

Results

Of the 3218 datasets collected in the @-Registry between December 2005 and June 2009, 418 patients met the inclusion criteria for the analysis (Table 1). The mean (SD) RT dose was 69.2 (6.5) Gy (median 70 Gy) and the mean (SD) time between EBRT and S-HIFU was 5.1 (2.7) years. The mean (SD) age at S-HIFU was 68.6 (5.8) years and the PSA level before S-HIFU was 6.8 (7.8) ng/mL. In all, 191 patients (45.7%) had a history of ADT (neoadjuvant, concomitant or adjuvant). No patients continued ADT after S-HIFU treatment.

The mean (SD) prostate volume before S-HIFU was 20.6 (7.9) mL and the treated volume was 22.2 (8.5) mL (average 108% of the prostate volume due to an overlap between the treated zone inside the prostate). The total number of S-HIFU sessions was 476 [one session: 364 (87.1%), two sessions: 51 (12.2%), and three sessions: three (0.7%)].

The median (range) follow-up after S-HIFU was 3.3 (1.5–5.2) years. The mean (SD) prostate volume after S-HIFU was 15.0 (8.8) mL. Due to the small prostate volume after S-HIFU, a minimum of six control biopsies were usually taken to evaluate the local control of the prostate cancer. In all, 254 patients (60.8%) underwent biopsy of which 187 (73.6%) were negative. Of the 164 patients without control biopsy, 88

Table 1 Baseline characteristics of 418 patients treated with S-HIFU after EBRT failure.

Variable	Value
Age, years	
Mean (SD)	68.6 (5.8)
Median (range)	69 (42–83)
PSA, ng/mL	
Mean (SD)	6.8 (7.8)
Median (range)	4.6 (0.0–62.0)
Prostate volume, mL	
Mean (SD)	20.6 (7.9)
Median (range)	19.0 (4.3–53.1)
Delay between Pre-EBRT and S-HIFU, years	
Mean (SD)	5.1 (2.7)
Median (range)	4.7 (0.1–17.5)
N (%)	
Previous ADT	
Yes	191 (45.7)
No	227 (54.3)
Pre-EBRT risk	
Low	48 (11.5)
Intermediate	77 (18.4)
High	119 (28.5)
Undefined	174 (41.6)
Pre-S-HIFU Gleason score	
≤6	121 (28.9)
=7	114 (23.3)
≥8	112 (26.8)
Undefined	71 (17.0)
Pre-S-HIFU PSA level, ng/mL	
≤4	173 (41.4)
4–10	166 (39.7)
≥10	76 (18.2)
Undefined	3 (0.7)

(53.6%) did not have biochemical recurrence, while 76 (46.4%) did and were placed on ADT.

The mean (SD) PSA nadir was 1.9 (5.2) ng/mL (median 0.19, range 0–54.9 ng/mL) and was reached at a mean (SD) time of 10.1 (10.7) weeks after S-HIFU. In all, 225 patients (53.8%) reached a nadir PSA level of ≤0.3 ng/mL and 203 (48.6%) ≤0.2 ng/mL.

In all, 222 patients (53.1%) did not receive any salvage treatment after S-HIFU, while 196 patients (46.9%) received ADT for recurrent local prostate cancer or metastases after S-HIFU. Of the 196 patients that received ADT after S-HIFU, 45 (23%) had positive biopsies, 75 (38.3%) had negative biopsies, and 76 (38.8%) did not have biopsies taken. Of the 222 patients that did not receive ADT after S-HIFU, 22 (9.9%) had positive biopsies, 112 (50.5%) had negative biopsies, and 88 (39.6%) did not have biopsies taken. The OS, CSS and MFS rates at 7 years were 72%, 82% and 81%, respectively (Fig. 1).

The bFFS rate at 5 years was 49%. At 5 years the bFFS rate was 58%, 51% and 36% for pre-EBRT low-, intermediate- and high-risk patients, respectively. The 5-year bFFS rate was 67%, 42% and 22% for pre-S-HIFU PSA levels of ≤4, 4–10 and ≥10 ng/mL respectively and 59%, 41% and 39% for pre-S-HIFU Gleason score of ≤6, equal to 7 and ≥8, respectively. The bFFS rate was 59% for patients without any previous ADT and 38% for those with a history of ADT (Fig. 2).

The salvage treatment-free survival rate at 5 years was 37%, and was 54%, 37% and 23% for pre-EBRT low-, intermediate- and high-risk patients, respectively. The 5-year salvage treatment-free survival rate was 49%, 33% and 20% for pre-S-

Fig. 1 OS, CSS and MFS rates in patients treated after S-HIFU

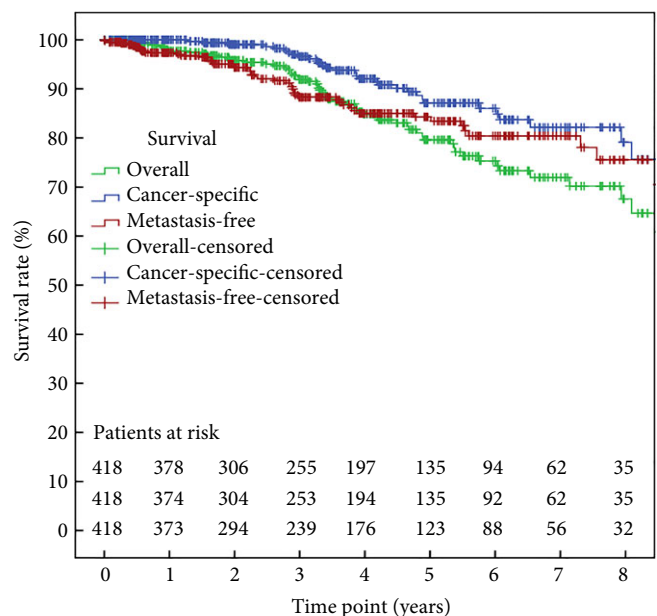
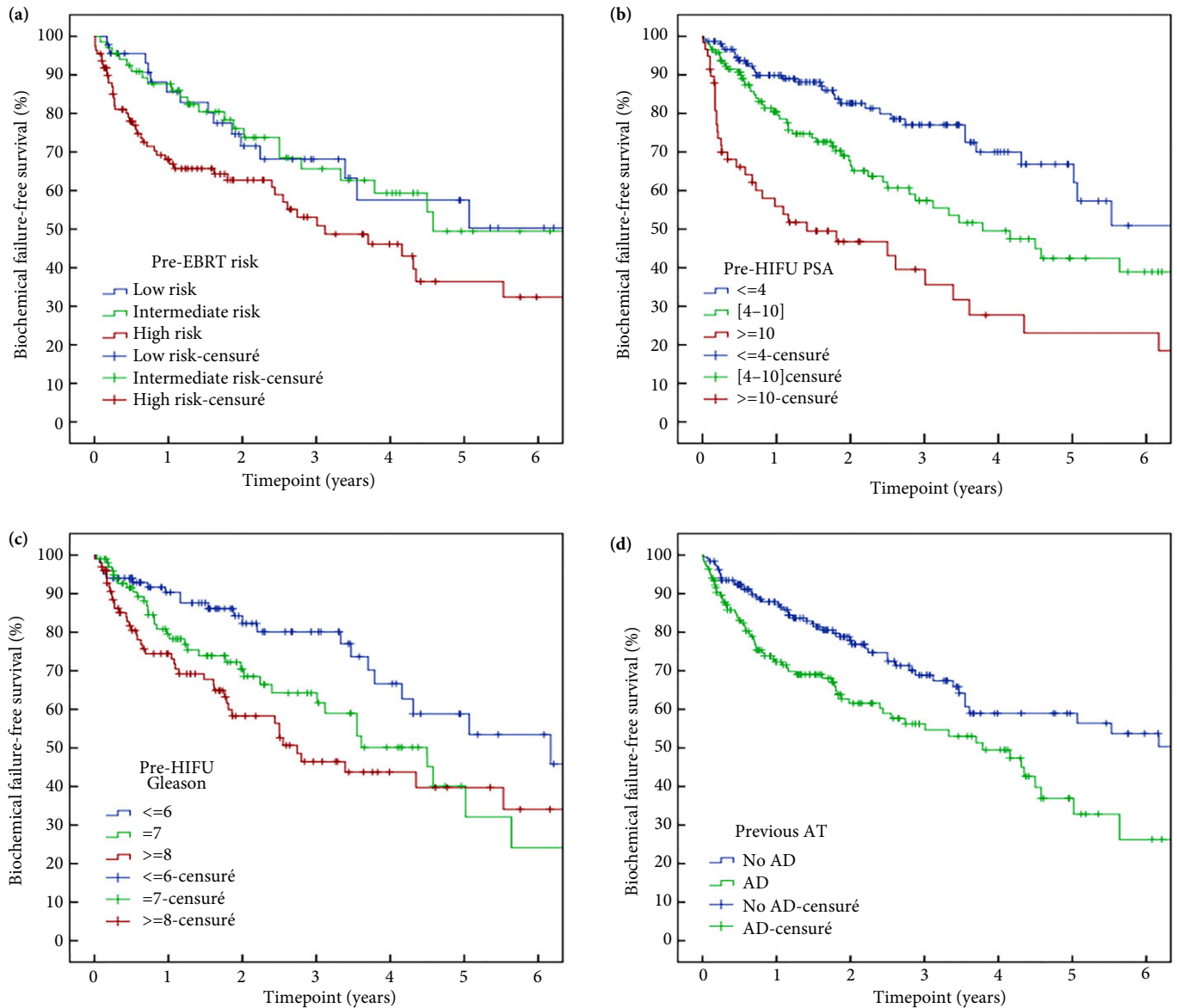


Fig. 2 bFFS rates. (a) influence of initial risk; (b) influence of pre-S-HIFU PSA level; (c) influence of pre-S-HIFU Gleason score; (d) influence of post-S-HIFU nadir PSA.



HIFU PSA levels of ≤ 4 , 4–10 and ≥ 10 ng/mL respectively and 50%, 38% and 22% for pre-S-HIFU Gleason score of ≤ 6 , equal to 7 and ≥ 8 , respectively. The 5-year salvage treatment-free survival rate for patients without any previous ADT was at 48% vs 26% for those with a history of ADT (Fig. 3).

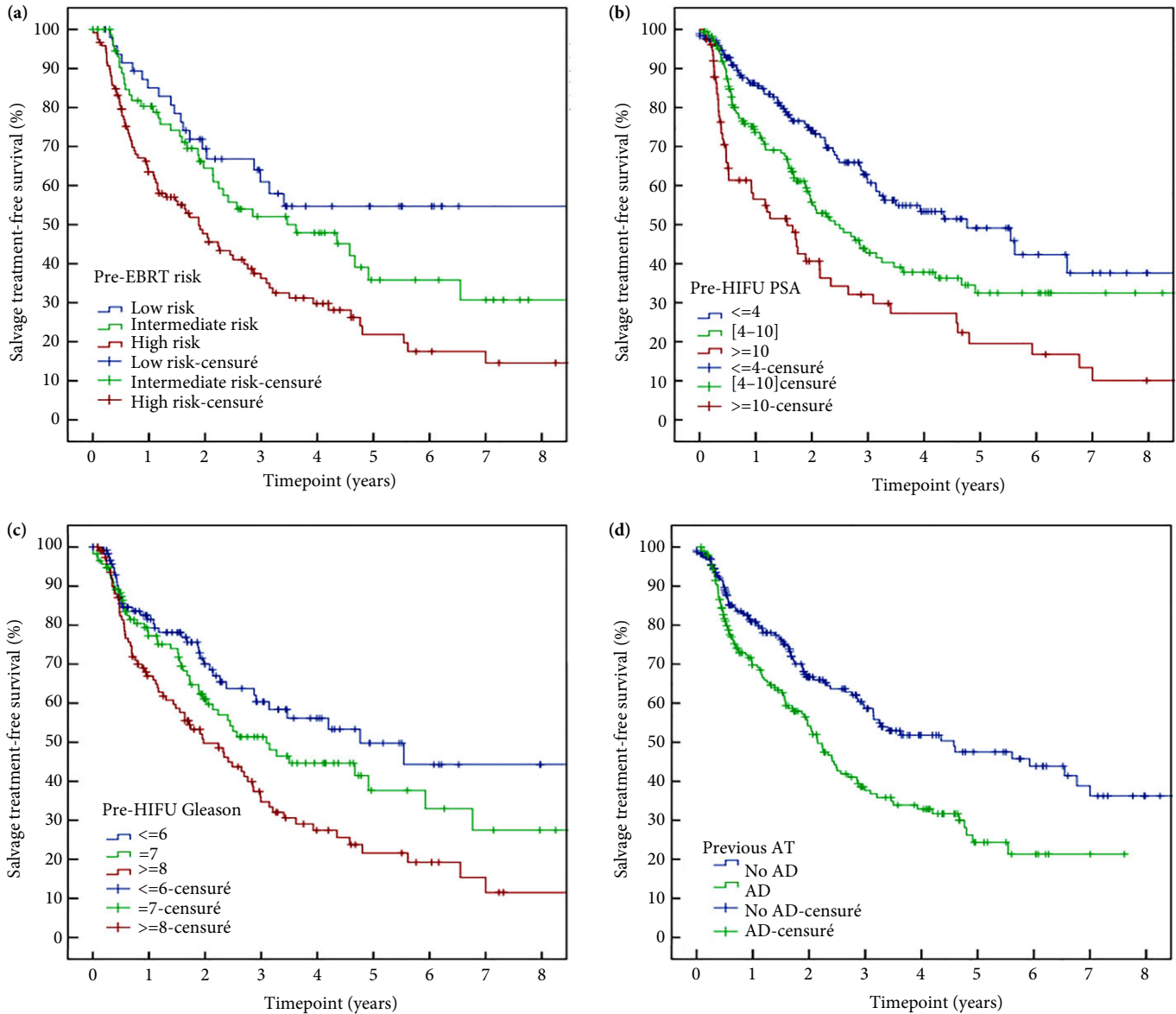
In the multivariate analysis three factors (history of ADT, pre-S-HIFU Gleason score and pre-S-HIFU PSA level) were significantly linked to biochemical recurrence and initiation of a salvage treatment (Table 2).

The PSA nadir was a major predictive factor for salvage treatment-free survival rate (Fig. 3). The salvage treatment-

free survival rate at 5 years was 56%, 16% and 8% for PSA nadir of ≤ 0.3 , 0.31–1 and > 1 ng/mL, respectively.

The specific post-RT parameters introduced in 2002 decreased the rate of many long-term complications (Table 3). Moderate and severe incontinence (grade II or III) decreased from 32% to 19%. The incidence of artificial urinary sphincter implantation was significantly reduced with the specific post-RT parameters when compared to standard parameters (15% vs 5%; $P < 0.001$). The incidence of BOO or stenosis incidence dropped from 30% to 15% ($P = 0.001$). The rate of recto-urethral fistula decreased from 9% to 0.6%.

Fig. 3 Salvage treatment-free survival rates. (a) influence of initial risk; (b) influence of pre-S-HIFU PSA level; (c) influence of pre-S-HIFU Gleason score; (d) influence of post-S-HIFU nadir PSA.



Erectile function was not evaluated. Of the nine recto-urethral fistulae, only two were successfully closed with a York-Masson procedure. The other seven, were managed with colostomy and Bricker (four) or colostomy alone (three). Osteitis was managed with prolonged antibiotics in six patients, retropubic muscular interposition in two, colostomy and Bricker in one.

Discussion

Most men with radio-recurrent prostate cancer are treated with systemic ADT [5,17]. ADT is also associated with adverse effects, including cardiac and thromboembolic

complications [18]. Patients treated with ADT or ADT followed by chemotherapy have poor outcomes. In the Zumsteg et al. [19] study, the date of biochemical failure to distant metastasis and cancer-specific mortality were 5.4 and 10.5 years respectively, despite the use of medical therapies, the estimated 5-year post-biochemical failure distant metastasis rate was 47% and the 5-year cumulative incidence of cancer-specific mortality was 18%. In our present study, after S-HIFU, the estimated MFS rate was 81% at 7 years.

The CSS rate after SRP at 10 years was reported to be 77% [20]. More recently, in a series of 404 patients undergoing SRP, at 10 years, the bFFS rate was 37%, the MFS rate was

Table 2 Initiation of salvage treatment after S-HIFU failure and biochemical failure (Phoenix definition): result of the Cox-multivariate analysis.*

Prognostic factors	Univariate		Multivariate	
	Risk ratio (95% CI)	P	Risk ratio (95% CI)	P
Initiation of salvage treatment after S-HIFU failure				
ADT	1.71 (1.29–2.27)	<0.001	2.09 (1.42–3.08)	<0.001
Pre-S-HIFU Gleason score				
≤6	1	–	1	–
=7	1.36 (0.90–2.06)	0.139	1.23 (0.73–2.07)	0.441
≥8	2.06 (1.40–3.02)	<0.001	1.82 (1.12–2.98)	0.016
Pre-S-HIFU PSA level, ng/mL				
≤4	1	–	1	–
4–10	1.59 (1.14–2.20)	0.006	1.62 (1.08–2.44)	0.021
>10	2.68 (1.85–3.88)	<0.001	2.24 (1.34–3.75)	0.002
Biochemical failure (Phoenix) after S-HIFU				
ADT	1.80 (1.25–2.59)	0.002	2.42 (1.46–4.00)	0.001
Pre-S-HIFU Gleason score				
≤6	1	–	1	–
=7	1.70 (1.01–2.85)	0.044	1.24 (0.64–2.39)	0.529
≥8	2.26 (1.37–3.71)	0.001	1.94 (1.05–3.58)	0.035
Pre-S-HIFU PSA level, ng/mL				
≤4	1	–	1	–
4–10	1.89 (1.21–2.93)	0.005	1.58 (0.92–2.72)	0.100
>10	4.12 (2.56–6.64)	<0.001	3.26 (1.76–6.05)	<0.001

*Pre-EBRT risk was not significant and was removed from the model (Cox backward stepwise method).

Table 3 Morbidity.

Adverse event	Standard HIFU parameters, % (n) (n = 74)	Post-RT HIFU parameters, % (n) (n = 314)	Overall, % (n) (n = 388)	P
Urinary incontinence, % (at risk)				
No pads	51.4 (38)	59.2 (186)	57.7 (224)	
grade 1	16 (12)	22 (69)	21 (81)	N.S.
grade 2	23 (17)	10 (31)	12 (48)	0.002
grade 3	9 (7)	9 (28)	9 (35)	N.S.
AUS	15 (11)	5 (16)	7 (27)	0.003
BOO/stenosis	30 (22)	15 (47)	18 (69)	0.003
Fistula	9 (7)	0.6 (2)	2.3 (9)	<0.001
Pubic bone osteitis	3 (2)	2 (6)	2 (8)	N.S.

AUS, artificial urinary sphincter.

77% and the CSS rate was 83% [6]. Definitive surgery for local recurrent prostate cancer after EBRT is associated with severe morbidity. The average rate of rectal injury was 4–7%, of bladder neck stricture was 24%, and the average urinary incontinence rate was 41% [21]. In a recent study, the rate of urinary incontinence was found to be 45.5% with 25.5% using 1 pad/day and 20% with ≥2 pads/day [7]. The rate of rectal injury was 3.6%. Those survival and complication data seem similar to those achieved with S-HIFU. But if only patients with specific S-HIFU parameters are evaluated, S-HIFU compares favourably with SPR. Results achieved after a robotic procedure seem similar to those of open surgery. In 2013, Yu et al. [22] reported complications and oncological outcomes of 51 robot-assisted SRPs: the estimated 3-year bFFS or progression-free survival rate was 57%. The overall

complications rate was 47% with a 35% major complications rate (Clavien–Dindo III–V): 16% bladder neck contractures, 4% thromboembolic events and 4% urosepsis. Return to urinary continence was achieved in 45% of patients.

Salvage cryotherapy is another option for this patient group. The disease-free survival rate at 10 years was 39% and the CSS rate was 87% in a report by Williams et al. [21]. The predictive factors of recurrence for salvage cryotherapy and for S-HIFU are similar (pre-salvage treatment PSA level, Gleason score, and PSA nadir). The morbidity for salvage cryotherapy is significant: recto-urethral fistula, 1–2%; obstruction/retention, 3.2–67%; chronic perineal pain, 4–14%; severe incontinence, 2–4%; and mild incontinence, 6–13% [23,24].

One concern with the localisation of the recurrence after EBRT is the localisation close to the urethra. Leibovici et al. [25] found 74% of recurrences are located within 5.0 mm of the urethra. The advantage of S-HIFU is the complete treatment without preservation of the urethra as opposed to cryotherapy.

Pisters et al. [26] compared the treatment outcomes of SRP and salvage cryotherapy for patients with locally recurrent prostate cancer after initial RT. Compared to salvage cryotherapy, SRP resulted in superior biochemical survival. In previously reported data, the progression-free survival rates after salvage cryotherapy at 5 years ranged from 40% [27] to 59% [28].

Few data are available for salvage brachytherapy with short follow-ups. The rate of morbidity was found on average for

incontinence to be 36%, recto-urethral fistula 3.4% and rectal grade 3–4 toxicity 5.6% [29]. Gomez-Veiga et al. [30] reported the main results of 10 trials of salvage brachytherapy for EBRT failure: the 5-year biochemical disease-free survival (bDFS) rates ranged from 20% to 87%. One study reported a 10-year bDFS rate of 54%. The incidence of gastrointestinal complications ranged from 5.4% to 65% and 2.7% to 20% for grade 1–2 and grade 3–4 complications, respectively.

In the present analysis, we evaluated survival rates after S-HIFU therapy for locally radio-recurrent prostate cancer in the largest case series to date. At a mean follow-up of 7 years after S-HIFU, the CSS and MFS rates were 72% and 82%, respectively. Our present results appear similar to those obtain after salvage surgery with a lower rate of severe complications using specific post-RT S-HIFU parameters. The present results support the use of S-HIFU as a definitive treatment for local recurrence after EBRT. Another series of S-HIFU performed with the Sonablate® device with a shorter follow-up (19.8 months) found a bFFS rate at 2 years of 43%, with 62% of patients being pad free [31]. The rate of BOO was 20% and the rate of recto-urethral fistula was 2.4% after one treatment.

In 2002, treatment-specific parameters for post-RT S-HIFU with Ablatherm® device were introduced to account for the vascularisation of the prostate gland and peri-prostatic tissue, resulting from RT-induced fibrosis. The incidence of side-effects dropped significantly when the dedicated acoustic parameters of the S-HIFU device were implemented. With the latest Ablatherm device the rate of recto-urethral fistula is now <1% and the rate of severe incontinence is <20%. These data compare favourably with recent data on salvage surgery [7]. The main side-effect in our present series was BOO caused by urethral stricture, bladder neck stenosis or an accumulation of captive necrotic tissue in the treated area. The decrease of BOO achieved with dedicated parameters is probably due to reduction of the shots duration and acoustic intensity (i.e. thermal dose).

An important prognostic factor was the pre-S-HIFU PSA level, which can serve as a very early identifier of local recurrence after EBRT. This suggests that, to increase the chances of a successful treatment, control biopsies should be taken as soon as a biochemical relapse is identified. The pre-S-HIFU estimated Gleason score and previous ADT are also predictive factors of success.

Early identification of local recurrence after EBRT allows the option of focal therapy using S-HIFU or salvage cryotherapy [32]. In the Ly et al. [33] study, 91 patients with biopsy confirmed radio-recurrent prostate cancer underwent salvage focal cryoablation with curative intent. The bDFS rates was 46.5% at 5 years, and there were positive biopsies after salvage focal cryoablation in four of 14 patients who underwent biopsy. Recto-urethral fistula occurred in three

patients (3.3%), urinary retention in six (6.6%), and incontinence in five (5.5%). In the Ahmed et al. [34] study, 39 patients received focal S-HIFU for localised recurrence after EBRT. The estimated progression-free survival rate was 49% at 2 years according to the Phoenix criteria and the pad-free rate was 87.2% at the last follow-up. In the two-centre study of Baco et al. [35], 48 patients received hemi-S-HIFU for unilateral radio-recurrent prostate cancer. The progression-free survival rate at 24 months was 52% and severe incontinence occurred in 8% of the patients, 17% required 1 pad/day and 75% were pad free. Focal therapies (cryoablation or HIFU) in patients with unilateral radio-recurrent prostate cancer results in less morbidity than whole gland salvage therapies. Accurate imaging and targeted biopsy are essential for identifying patients suitable for focal salvage procedures.

The present study has limitations: it is a retrospective analysis of registry data with a relatively short follow-up period. We did not evaluate PSA-doubling time, and the influence of the interval between EBRT and recurrence. The pre-EBRT D'Amico risk group was unknown in 41.6% of the patients and could represent a bias for the statistical analysis. Furthermore, the absence of a control group could have overestimated the effect of S-HIFU on the salvage treatment-free survival rate and CSS rate.

The lack of patient-reported outcome measures in the @registry is a drawback for quality of life evaluation. Concerning biochemical failure, the Phoenix definition was used in the present study, although it is not validated for HIFU treatment. To overcome this limitation we presented the results of the salvage treatment-free survival rate after S-HIFU.

In the present retrospective study, the locoregional and metastatic evaluation was not optimal for the first set of patients as positron emission tomography-choline and bone-MRI were not routinely available. Careful patient selection should be performed and the prospect of salvage treatment should be carefully weighed in the absence of level I evidence. Rectal stenosis after EBRT can represent an issue for S-HIFU. An MRI with an endorectal balloon can evaluate the size of the rectum and the rectal wall thickness before treatment.

Nonetheless, these data represent the largest case series of S-HIFU after RT failure to date, and the CSS, MFS and bFFS rates, add to the growing body of evidence that supports the expanded use of this procedure.

Conclusion

S-HIFU for locally recurrent prostate cancer after failed EBRT is associated with favourable 7-year survival rates at a price of significant morbidity, which patients should be made aware

of. Longer-term survival rates are needed, although the data presented supports the view that S-HIFU should now be considered as a definitive treatment option for patients with sufficient life expectancy to justify a salvage curative treatment.

Conflicts of Interest

Dr Crouzet is a consultant for EDAP TMS; Dr Blana, Dr Gelet and Dr Chaussy report personal fees from EDAP TMS.

References

- Zelevsky MJ, Reuter VE, Fuks Z, Scardino P, Shippy A. Influence of local tumor control on distant metastases and cancer related mortality after external beam radiotherapy for prostate cancer. *J Urol* 2008; 179: 1368–73
- Zapatero A, Minguez R, Nieto S, Martin De Vidales C, Garcia-Vicente F. Post-treatment prostate biopsies in the era of three-dimensional conformal radiotherapy: what can they teach us? *Eur Urol* 2009;55:902–9.
- Beckendorf V, Guerif S, Le Prise E et al. 70 Gy versus 80 Gy in localized prostate cancer: 5-year results of GETUG 06 randomized trial. *Int J Radiat Oncol Biol Phys* 2011; 80: 1056–63
- Vora SA, Wong WW, Schild SE et al. Outcome and toxicity for patients treated with intensity modulated radiation therapy for localized prostate cancer. *J Urol* 2013; 190: 521–6
- Jones JS. Radiorecurrent prostate cancer: an emerging and largely mismanaged epidemic. *Eur Urol* 2011; 60: 411–12
- Chade DC, Shariat SF, Cronin AM et al. Salvage radical prostatectomy for radiation-recurrent prostate cancer: a multi-institutional collaboration. *Eur Urol* 2011; 60: 205–10
- Heidenreich A, Richter S, Thuer D, Pfister D. Prognostic parameters, complications, and oncologic and functional outcome of salvage radical prostatectomy for locally recurrent prostate cancer after 21st-century radiotherapy. *Eur Urol* 2010; 57: 437–43
- Thüroff S, Chaussy C. Evolution and outcomes of 3 intensity focused ultrasound therapy for localized prostate cancer during 15 years. *J Urol* 2013; 190: 702–10
- Ganzer R, Fritsche HM, Brandtner A et al. Fourteen-year oncological and functional outcomes of high-intensity focused ultrasound in localized prostate cancer. *BJU Int* 2013; 112: 322–9
- Crouzet S, Chapelon JY, Rouvière O et al. Whole-gland ablation of localized prostate cancer with high-intensity focused ultrasound: oncologic outcomes and morbidity in 1002 patients. *Eur Urol* 2014; 65: 907–14
- Murat FJ, Poissonnier L, Rabilloud M et al. Mid-term results demonstrate salvage high-intensity focused ultrasound (HIFU) as an effective and acceptably morbid salvage treatment option for locally radiorecurrent prostate cancer. *Eur Urol* 2009; 55: 640–7
- Crouzet S, Murat FJ, Pommier P et al. Locally recurrent prostate cancer after initial radiation therapy: early salvage high-intensity focused ultrasound improves oncologic outcomes. *Radiother Oncol* 2012; 105: 198–202
- American Society for Therapeutic Radiology and Oncology Consensus Panel. Consensus statement: guidelines for PSA following radiation therapy. *Int J Radiat Oncol Biol Phys* 1997; 37: 1035–41
- Roach M 3rd, Hanks G, Thames H Jr et al. Defining biochemical failure following radiotherapy with or without hormonal therapy in men with clinically localized prostate cancer: recommendations of the RTOG-ASTRO Phoenix Consensus Conference. *Int J Radiat Oncol Biol Phys* 2006; 65: 965–74
- Ganzer R, Roggenhofer S, Walter B et al. PSA nadir is a significant predictor of treatment failure after high-intensity focussed ultrasound (HIFU) treatment of localised prostate cancer. *Eur Urol* 2008; 53: 547–53
- Ingelman-Sundberg A, Ulmsten U. Surgical treatment of female urinary stress incontinence. *Contrib Gynecol Obstet* 1983; 10: 51–69
- Grossfeld GD, Li YP, Lubeck DP, Carroll PR. Patterns of failure after primary local therapy for prostate cancer and rationale for secondary therapy. *Urology* 2002;60:57–62.
- Ehdaie B, Atoria CL, Gupta A et al. Androgen deprivation and thromboembolic events in men with prostate cancer. *Cancer* 2012; 118: 3397–406
- Zumsteg ZS, Spratt DE, Romesser PB et al. The natural history and predictors of outcome following biochemical relapse in the dose escalation era for prostate cancer patients undergoing definitive external beam radiotherapy. *Eur Urol* 2015;67:1009–16.
- Ward JF, Sebo TJ, Zincke H, Blute ML. Salvage surgery for radiorecurrent prostate cancer: contemporary outcomes. *J Urol* 2005; 173: 1156–60
- Williams AK, Martinez CH, Lu C et al. Disease-free survival following salvage cryotherapy for biopsy-proven radio-recurrent prostate cancer. *Eur Urol* 2011; 60: 405–10
- Yuh B, Ruel N, Muldrew S et al. Complications and outcomes of salvage robot-assisted radical prostatectomy: a single-institution experience. *BJU Int* 2014; 113: 769–76
- Nguyen PL, D'Amico AV, Lee AK, Suh WW. Patient selection, cancer control, and complications after salvage local therapy for post-radiation prostate-specific antigen failure: a systematic review of the literature. *Cancer* 2007; 110: 1417–28
- Mouraviev V, Spiess PE, Jones JS. Salvage cryoablation for locally recurrent prostate cancer following primary radiotherapy. *Eur Urol* 2012; 61: 1204–11
- Leibovici D, Chiong E, Pisters LL et al. Pathological characteristics of prostate cancer recurrence after radiation therapy: implications for focal salvage therapy. *J Urol* 2012; 188: 98–102
- Pisters LL, Leibovici D, Blute M et al. Locally recurrent prostate cancer after initial radiation therapy: a comparison of salvage radical prostatectomy versus cryotherapy. *J Urol* 2009; 182: 517–27
- Izawa JI, Morganstern N, Chan DM, Levy LB, Scott SM, Pisters LL. Incomplete glandular ablation after salvage cryotherapy for recurrent prostate cancer after radiotherapy. *Int J Radiat Oncol Biol Phys* 2003; 56: 468–72
- Bahn DK, Lee F, Silverman P et al. Salvage cryosurgery for recurrent prostate cancer after radiation therapy: a seven-year follow-up. *Clin Prostate Cancer* 2003; 2: 111–14
- Grado GL, Collins JM, Kriegshauser JS et al. Salvage brachytherapy for localized prostate cancer after radiotherapy failure. *Urology* 1999; 53: 2–10
- Gomez-Veiga F, Mariño A, Alvarez L et al. Brachytherapy for the treatment of recurrent prostate cancer after radiotherapy or radical prostatectomy. *BJU Int* 2012; 109(Suppl. 1): 17–21
- Ahmed HU, Cathcart P, Chalasani V et al. Whole-gland salvage high-intensity focused ultrasound therapy for localized prostate cancer after recurrence after external beam radiation therapy. *Cancer* 2012; 118: 3071–8
- Bahn D, de Castro Abreu AL, Gill IS et al. Focal cryotherapy for clinically unilateral, low-intermediate risk prostate cancer in 73 men with a median follow-up of 3.7 years. *Eur Urol* 2012; 62: 55–63
- Li YH, Elshafei A, Agarwal G, Ruckle H, Powsang J, Jones JS. Salvage focal prostate cryoablation for locally recurrent prostate cancer after radiotherapy: initial results from the cryo on-line data registry. *Prostate* 2015; 75: 1–7
- Ahmed HU, Cathcart P, McCartan N et al. Focal salvage therapy for localized prostate cancer Recurrence after external beam radiotherapy. *Cancer* 2012; 118: 4148–55

35 Baco E, Gelet A, Crouzet S et al. hemisalvage high-intensity focused ultrasound (HIFU) in unilateral radiorecurrent prostate cancer: a prospective two centre study. *BJUI Int* 2014; 114: 532–40

Correspondence: Sebastien Crouzet, Urology and Transplantation Department, Edouard Herriot Hospital, 5 Place d'Arsonval, 69437 Lyon Cedex 03, France.

e-mail: sebastien.crouzet@chu-lyon.fr

Abbreviations: ADT, androgen-deprivation therapy; bDFS, biochemical disease-free survival; bFFS, biochemical failure-free survival; CSS, cancer-specific survival; HIFU, high-intensity focused ultrasound; MFS, metastasis-free survival; OS, overall survival; SRP, salvage radical prostatectomy; (EB) RT, (external beam) radiotherapy.



Contents lists available at SciVerse ScienceDirect

Radiotherapy and Oncology

journal homepage: www.thegreenjournal.com

Original article

Locally recurrent prostate cancer after initial radiation therapy: Early salvage high-intensity focused ultrasound improves oncologic outcomes

Sébastien Crouzet^{a,d,*}, Francois-Joseph Murat^a, Pascal Pommier^b, Laura Poissonnier^a, Gilles Pasticier^c, Olivier Rouviere^a, Jean-Yves Chapelon^d, Muriel Rabilloud^e, Aurélien Belot^{e,f}, Florence Mège-Lechevallier^a, Hélène Tonoli-Catez^a, Xavier Martin^a, Albert Gelet^a

^a Edouard Herriot Hospital, Lyon; ^b Centre léon Bérard, Lyon; ^c Pellegrin Hospital, Bordeaux; ^d INSERM unit 1032, Lyon; ^e Service de Biostatistique, Hospices civils de Lyon; ^f Institut de veille sanitaire (InVS), Saint Maurice, France

ARTICLE INFO

Article history:

Received 2 March 2011

Received in revised form 19 September 2012

Accepted 20 September 2012

Available online xxxxx

Keywords:

HIFU

Prostate cancer

Prognostic factors

Radiorecurrent

Salvage treatment

ABSTRACT

Purpose: To evaluate pre-operative prognostic risk factors to predict oncologic outcome of Salvage High-Intensity Focused Ultrasound (S-HIFU) for radiorecurrent prostate cancer (PCa).

Methods and materials: A total of 290 men with biopsy-confirmed locally radiorecurrent PCa, underwent S-HIFU. D'Amico risk group before external beam radiotherapy (EBRT), Prostate Specific Antigen (PSA), estimated Gleason score prior HIFU and post HIFU biopsies were analyzed for predictive utility of local cancer control, cancer-specific, metastasis free, and progression free survival rates (PFSR).

Results: Local cancer control with negative biopsy results was obtained in 81% of the 208 patients who underwent post-S-HIFU biopsies. Median PSA nadir was 0.14 ng/ml and 127 patients did not require androgen deprivation therapy (ADT). The mean follow up was 48 months for cancer-specific survival rates. The cancer-specific and metastasis-free survival rates at 7 years were 80% and 79.6% respectively. The PFSR was significantly influenced by: the pre-HIFU PSA level (hazard ratio (HR): 1.09, 95% CI 1.04–1.13), a Gleason score ≥ 8 versus ≤ 6 (HR: 1.17, 95% CI 1.03–1.3), and a previous ADT (HR: 1.28, 95% CI 1.09–1.46). The rates of recto-urethral fistula (0.4%) and grade II/III incontinence (19.5%) indicate significant reduction in serious side effects with use of dedicated post-radiation acoustic parameters compared with standard parameters.

Conclusion: S-HIFU is an effective curative option for radiorecurrent PCa with acceptable morbidity for localized radiorecurrent PCa, but should be initiated early following EBRT failure. Use of prognostic risk factors can optimize patient selection.

© 2012 Elsevier Ireland Ltd. All rights reserved. Radiotherapy and Oncology xxx (2012) xxx–xxx

Although EBRT has long been used as a curative approach for localized prostate cancer (PCa), several studies have shown that incomplete tumor destruction occurs at higher rates than previously thought [1], and there is an absence of consensus regarding the optimal management of locally recurrent PCa following EBRT. Androgen deprivation therapy (ADT) is frequently used to delay metastatic progression. Salvage therapies are available, and include cryotherapy, brachytherapy, and radical prostatectomy (RP), but their use is technically challenging and characterized by high rates of serious side effects. Salvage high-intensity focused ultrasound (S-HIFU) has recently been evaluated as a therapeutic option for locally recurrent PCa following EBRT [2,3]. The present study evaluated pre-operative risk factors to determine

their value in predicting oncologic outcome following S-HIFU for radiorecurrent PCa.

Material and methods

Data on all patients treated with HIFU for locally recurrent PCa following EBRT between 1995 and 2009 were obtained from a prospectively entered database after IRB approval (2002–091B) (phase II study). Inclusion criteria were a biochemical failure (Astro or Phoenix definition) [4,5], positive control biopsy and negative findings of metastatic evaluation. Exclusion criteria were a non-organ confine recurrence (lymph node or bone metastasis) and biochemical failure with negative biopsy. Patients who fit the inclusion criteria were offered S-HIFU as a definitive local therapy in a single center. All metastatic evaluations included bone scan and abdomino-pelvic computerized tomography (CT); most patients received prostatic magnetic resonance image (MRI), and several high-risk patients received either fluorocholine positron

* Corresponding author. Address: Urology and Transplantation Department, Edouard Herriot Hospital, 5 place d'Arsonval, 69437 Lyon Cedex 03, France.

E-mail address: sebastien.crouzet@chu-lyon.fr (S. Crouzet).

emission tomography and computerized tomography (18F PET/CT) or total body MRI.

Procedure

All HIFU sessions were performed under spinal or general anesthesia using Ablatherm™ devices (EDAP, Vaulx-en-Velin, France) according to standard procedure [2]. Different devices were used at different time points during the study; patients were treated with prototype devices from 1995 to 1999, the first commercially available device (Ablatherm Maxis®) from 2000 to 2005, and with the second commercially available device (Ablatherm Integrated Imaging®) that allows real-time therapy control since 2005. During 1995–1996, patients were systematically treated in two sessions (one for each prostate lobe) spaced 1–3 months apart, and in a single session alone since 1997. An additional S-HIFU session was performed only in case where residual cancer foci were identified by control biopsies. Between 1995 and March 2002, standard treatment parameters were used. This entailed 100% acoustic power, varying from 26 to 35 W according to lesion length and 1550 W/cm² at the transducer focus, with a 6-s pulse of energy to create each discrete HIFU lesion with a 4-s delay between each shot. Starting in March 2002, a specific post-radiation treatment parameter was adopted (5-s pulse, 5-s waiting period, 90% of the acoustic power) because of the decreased vascularity in the previously irradiated tissue. The goal was to optimize the thermal dose delivered within the gland while minimizing the damage probability to surrounding tissues –especially the rectal wall–caused by conductive heat transfer. For S-HIFU re-treatment the shot duration was reduced to 4 s with the acoustic power lowered to 85%.

To reduce gland size, ADT was offered to any patient with a prostate volume >30 ml for 3 months prior to S-HIFU. For all patients, a bladder neck incision was performed just before HIFU to reduce the postoperative catheterization period and to avoid bladder outlet obstruction. When a median lobe was present, it was retrieved using transurethral resection of the prostate (TURP). The S-HIFU protocol involved treatment of the entire gland. There were four treatment sections defined by the ultrasound, with two sections in each lobe. The lower limit for treatment was designated as 4 mm from the apex, to reduce the risk of stress incontinence from heat accumulation and diffusion while nevertheless treating the apical tissue. A three-way catheter was inserted at the end of the procedure and removed 3–5 days later.

Immediate postoperative protocol included serial PSA measurements and beginning in March 2000 all patients underwent dynamic enhanced MRI to ascertain the rectal wall integrity and induced necrotic extension within the gland [6]. Extended patient follow-up included clinical and biochemical evaluations every 3 months for the first year and every 6 months thereafter. All patients underwent biopsy at 3 months, with additional biopsies performed only in the event of PSA rise above 1.0 ng/ml. Since 2008, systematic control biopsies were not performed when the PSA nadir was less than 0.3 ng/ml. A new metastasis evaluation was conducted in the event of biochemical relapse. A second S-HIFU session was offered when an exclusively local recurrence was identified. Side effects were systematically evaluated and recorded. Urinary incontinence was graded according to the Ingelman-Sundberg score (strong, moderate, minimal effort: grade I, grade II and grade III, respectively) obtained from patient questionnaires [7].

Statistical analysis

Specific, metastasis-free and progression-free survival rates (PFSR) were estimated with the Kaplan–Meier method. Failure was defined as either an increase of 2 ng/ml or more occurred, above the PSA nadir (Phoenix ASTRO consensus) [5], or as AD

initiation, whichever occurred first. The PFSR was stratified according to the pre-radiotherapy D'Amico's risk group, the pre-HIFU PSA level (≤ 4 ng/ml, 4.1–10 ng/ml, or >10 ng/ml), the pre-HIFU estimated Gleason score (≤ 6 , 7, ≥ 8 , or undefined), the number of pre HIFU positive biopsy sextants (0 or 1, 2 or 3, 4–6), the prostate volume (≤ 15 cc, 15–21 cc, >21 cc) and the administration of ADT before HIFU. The Kaplan–Meier method was also used to estimate the PFSR curves according to the different categories of each factor compared when using the log rank test. A Cox model was used for multivariate analysis to identify independent factors linked to the risk of failure. Analysis was performed using the statistical software S-plus version 6.2. A *p*-value <0.05 was chosen to reflect statistically significant differences.

Results

A total of 300 patients with biopsy-confirmed locally recurrent PCa after EBRT were selected for S-HIFU procedure. The procedure was halted in 10 patients due to technical difficulties including rectal stricture and/or rectal wall thickness ≥ 6 mm, resulting in the treatment of 290 patients with S-HIFU. Of these 290 patients, the mean age was 68.7 ± 5.6 years and mean PSA was 6.38 ± 7.61 ng/ml. The pre-ERBT D'Amico's risk group classification included low risk in 19% ($n = 55$), intermediate risk in 31.4% ($n = 91$), high risk in 43% ($n = 125$), and undefined in 6.6% ($n = 19$) of subjects. The pre-ERBT Gleason score was: ≤ 6 in 23% ($n = 66$), 7 in 28% ($n = 82$), ≥ 8 in 35% ($n = 102$), and undefined in 14% ($n = 40$) of subjects. The average radiation dose was 69.6 grays (36–88) and the mean time between EBRT and salvage HIFU was 60 ± 22 months. A total of 145 patients (50%) received ADT prior to HIFU, including 22.4% ($n = 65$) as combination therapy with EBRT, 22.8% ($n = 66$) as adjuvant therapy following EBRT, and 4.8% ($n = 14$) for “down sizing” to decrease prostate volume prior to S-HIFU. ADT was discontinued in all recipients prior to the initial S-HIFU. The total number of S-HIFU sessions was 341 (one session: 237 and two sessions: 52). On mean 397 shots were delivered during the first S-HIFU session corresponding to a treated volume of 21.1 cc (on average 116% of the prostate volume due to an overlap between the treated zone inside the prostate). The mean catheterization period was 4.7 days (range 3–66). The mean follow-up period was 27 months for PFSR estimation and 48 months for cancer specific and metastasis free estimations.

Following S-HIFU treatment, the mean prostate volume decreased from 18.3 ± 9.5 to 13.7 ± 10.2 cc. Due to the small prostate volume after HIFU, a minimum of eight control biopsies was usually performed to evaluate the local control of the PCa. Control biopsies after the final S-HIFU session were available in 208 patients, of which 169 (81%) were negative.

Nadir PSA, attained at a mean 5.55 months, was a mean 1.54 ± 3.38 ng/ml (median 0.14 ng/mL). A nadir PSA of ≤ 0.3 ng/ml was observed in 60.7% ($n = 176$) patients. ADT was initiated following S-HIFU in 162 patients for biochemical relapse and positive biopsy ($n = 73$), or for biochemical relapse without control biopsy performed ($n = 89$), while 127 patients did not require ADT. Metastatic disease developed in 41 patients, and 29 patients died of metastatic PCa.

The estimated cancer-specific and metastasis free survival rates at 5 and 7 years were 80% (95% CI 72.7–88.5%) and 79.6% (95% CI 73.5–86.2%), respectively. The PFSR was inversely related to the pre-EBRT D'Amico risk level ($p = 0.002$, Fig. 1). At 5 years the PFSR was 45% (95% CI 32–63%), 31% (95% CI 22–45%) and 21% (95% CI 13.6–32%) for low-, intermediate- and high-risk patients respectively. A significance difference in BDFS was found between patients who received AD in association with, or after EBRT versus those who did not ($p = 0.0017$).

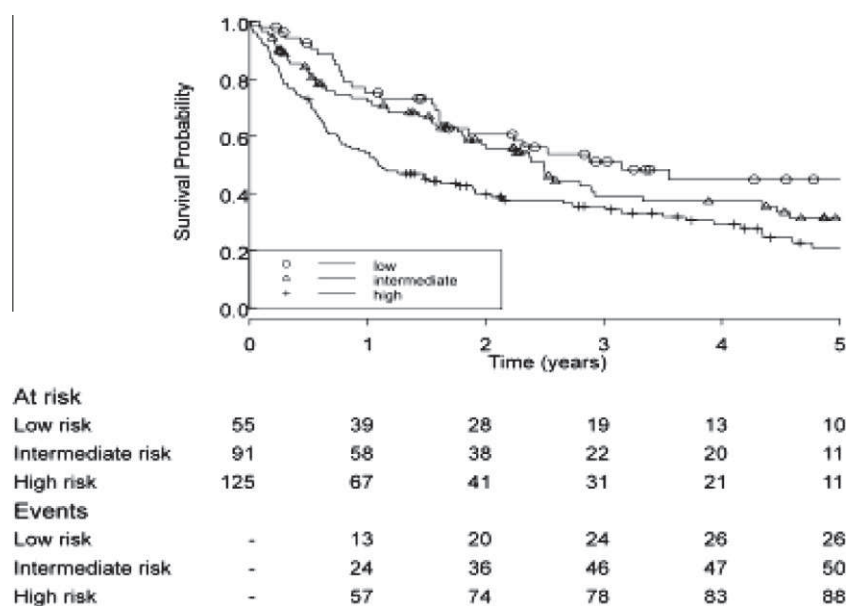


Fig. 1. Progression free survival rate according to the pre external beam radiation therapy D'Amico risk group.

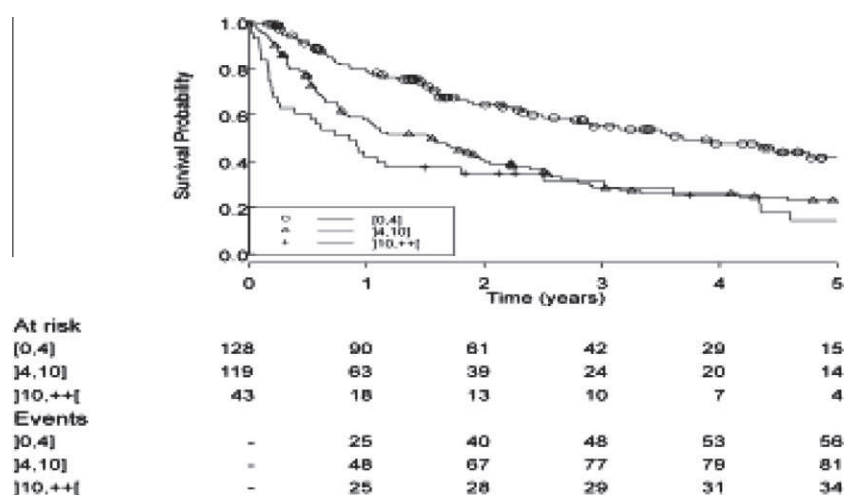


Fig. 2. Progression free survival rate according to the pre high-intensity focused ultrasound PSA value.

The PFSR was significantly associated with the pre-HIFU PSA value ($p = 0.00005$, Fig. 2). At 5 years, the PFSR was 43% (CI 33–56%), 22% (CI 15–33%) and 17% (CI 8–36%) for PSA values ≤ 4 , 4–10 and >10 , respectively. Similarly, the PFSR was related to the pre S-HIFU Gleason score. At 5 years the PFSR was 41% (95% CI 29–59%), 27% (95% CI 17–42.5%) and 20% (95% CI 13–32%) for Gleason score ≤ 6 , 7 and ≥ 8 ($p = 0.015$). Differences in PFSR by number of positive biopsy sextants or pre-S-HIFU prostate volume were not significant ($p = 0.68$ and $p = 0.67$, respectively). Nadir PSA was a major predictive factor for PFSR. The 5-years PFSR was 47.0% (95% CI 38–56%), 5% (95% CI 4–21%) and 0% for PSA nadir ≤ 0.3 ng/ml, 0.31–1 ng/ml and >1 ng/ml, respectively.

Multivariate analysis identified three predictive factors that were significantly associated with increased risk of disease progression (Table 1).

These included pre-HIFU PSA level ($p = 0.0002$), previous ADT ($p = 0.01$), and Gleason ≥ 8 (vs. Gleason ≤ 6 ; $p = 0.01$). Patients with previous ADT, or pre-HIFU Gleason ≥ 8 were (1.3, and 1.2 times more likely to experience disease progression following S-HIFU.

The prostate volume and the number of positive biopsy sextants were not statistically linked to the PFSR.

Urinary retention secondary to sloughing occurred in 9% of patients during the first 3 months post-treatment, and required prolonged catheterization or endoscopic extraction of the necrotic debris. Febrile urinary tract infections occurred in 3.4% of the cases and were treated with antibiotics. Compared with standard parameters, rates of moderate to serious morbidity decreased with use of specific post-radiation parameters introduced in 2002, including grade II or III incontinence ($p < 0.0001$ vs. standard parameters) (Table 2), artificial urinary sphincter implantation (20% vs. 5%; $p < 0.001$), and bladder outlet obstruction (30% vs. 14%; $p = 0.001$). Stenosis occurred in 49 patients, and was treated with cold-blade internal uretrotomy and/or TURP or repeated dilations ($n = 5$). Severe recurrence of stenosis occurred in five patients, which was managed with urethral stent ($n = 2$), self-catheterization ($n = 1$), supra-pubic catheter ($n = 1$), or trans-ileal urinary diversion ($n = 1$). Morbidity rates are summarized in Table 2.

Six cases of urethro-rectal fistula occurred 2–10 weeks following S-HIFU, including five cases with standard parameters (before 2002) and one case with post-radiation parameters. Urethro-rectal fistula was managed with trans-ileal urinary diversion and colostomy ($n = 5$) or the York Mason procedure ($n = 1$). Pubic bone

Table 1
Prognostic factors of progression after salvage high-intensity focused ultrasound: results of the Cox model.

Prognostic factors	Hazard ratio	95% CI	<i>p</i>
Gleason score			
≤6	1		
=7	1.04	[0.78; 1.29]	0.79
≥8	1.17	[1.03; 1.3]	0.01
PSA before S-HIFU (ng/ml) (effect for an increase of 1 unit)	1.09	[1.04; 1.13]	0.0002
Previous AD treatment			
No	1		
Yes	1.28	[1.09; 1.46]	0.01
D'Amico's risk groups			
Low	1		
Intermediate	1.00	[0.73; 1.27]	0.99
High	1.07	[0.95; 1.20]	0.27
Number of positive biopsy sextants (effect for one more positive sextant)	1.00	[0.89; 1.10]	0.95
Prostate volume cc (effect for an increase of 1 unit)	1.01	[0.98; 1.03]	0.68

The bold value are the statistically significant value
CI, confidence interval; PSA, prostate-specific antigen; S-HIFU, salvage high intensity focused ultrasound; AD, Androgen deprivation.

Table 2
Overall and according to the acoustic parameters long term complications.

	Overall % (n)	Standard parameters % (n)	Post-radiation parameters % (n)
Patients	100% (290)	19% (56)	81% (234)
Long term complications			
Urinary incontinence			
No pads	0	0	0
Grade 1	I 50% (145)	I 32% (18)	I 54% (126)
Grade 2	II 23% (68)	II 16% (9)	II 25% (59)
Grade 3	III 14% (41)	III 29% (16)	III 11% (25)
NV	NE 9% (26)	NE 10.5% (6)	NE 8% (20)
AUS	AUS 4% (12)	AUS 12.5% (7)	AUS 2% (5)
Bladder outlet obstruction	16% (46)	30% (17)	12% (29)
Urinary diversion for recurrent stricture	1.3% (4)	3.5% (2)	0.8% (2)
Urethrorectal fistula	2% (6)	9% (5)	0.4% (1)
Urinary diversion for fistula	1.7% (5)	9% (5)	0% (0)
Anal incontinence	0.7% (2)	4% (2)	0% (0)
Pubic bone osteitis	2.7% (8)	4% (2)	2.5% (6)

NV, non valuable; AUS, artificial urinary sphincter implantation.

osteitis resulting from direct contact of urine and the bone occurred in eight patients. In two cases this originated from spontaneous necrosis of the anterior part of the prostate after S-HIFU. The other six cases developed secondary to endoscopic intervention of severe stricture, and were resolved by long-term catheterization ($n = 2$), musculus rectus abdominis interposition using a retro-pubic approach ($n = 2$), or trans-ileal urinary diversion ($n = 2$). Erectile function was not evaluated.

Discussion

Concern has arisen over the failure of conventional-dose radiotherapy to eliminate PCa in a significant number of patients, resulting in increasing PSA level, the need for salvage therapy, and ultimately, in clinical recurrence. In a recent article, Zietman et al. reported a 10-years BFSR (ASTRO) of 32.3% for the conventional-dose (70.2 Gy) radiotherapy [8]. A randomized dose-escalation study by Al-Mamgani et al. found 6-year BFSR rates of 51% and 63% in the 68 Gy and 78 Gy treatment arms, respectively [9]. The prognosis for patients who experience failure following primary EBRT has yet to be defined. The most common secondary treatment after EBRT is AD which is administered to approximately 94% of these patients [10]. Despite AD and chemotherapy, outcomes for patients with recurrent PCa remain poor. The estimated 5-year

mortality risk is strongly influenced by initial Gleason score; as reported by D'Amico et al., the 5-year cancer-specific mortality rate following EBRT failure was 24%, 40%, and 59% for patients with biopsy Gleason scores of ≤6, 3 + 4, and 4 + 3 or higher, respectively [11]. Local failure following EBRT is rather frequent with rates ranging from 25% to 32% [1,12,13]. Zelefsky et al. found that following EBRT monotherapy, positive biopsy rates were 50%, 39% and 33% in patients who received 70.2 Gy, 75.6 Gy and 81 Gy, respectively.

The 10-year PSA relapse-free survival rate in patients with positive biopsy results was 3%. The 10-year metastasis risk in patients with positive biopsy was 31%. Post treatment biopsy status was also associated with an increased risk of PCa death [12].

The radical prostatectomy (RP) remains the most aggressive salvage option. Within the largest series published, the specific survival rates at 5 years were found to be 79% [14] and 85% [15]. The progression free survival rates were found to be 43% at 10 years [16] and 58% at 5 years [14]. In these series the rates of organ confined PCa were less than 40% [16]. High rates of serious morbidity were reported in these series, including rectal injury ranging from 4% [14] to 7% [17]. Urinary incontinence varies from 45% [15] to 51% [16]. Bladder outlet obstruction ranges from 21% [16] to 30% [17]. Recently, Heidenreich et al. reported the outcomes of 55 patients treated with salvage RP for EBRT failure [18]. Organ confined cancer was found in 73% of patients. With a median 23-month follow up, seven patients developed a

recurrence including two patients with metastatic dissemination. At 1-year follow-up, continence returned to normal in 80% of the patients (54.5% without the use of a pad and 25.5% with just one pad a day) and one patient developed recto urethral fistula (2%). Pisters et al. compared the treatment outcomes of salvage RP and salvage cryotherapy in patients with locally recurrent PCa following EBRT failure [19]. Compared to cryotherapy, RP resulted in superior biochemical survival. In previously reported data, 5-year biochemical survival rates in patients receiving salvage cryotherapy for EBRT failure ranged from 40% [20] to 59% [21]. The other salvage option is brachytherapy. The few published studies reported only short-term follow-up data [22,23]. The results were highly influenced by patient selection, with low- and intermediate-risk patients showing the best cancer control outcomes. In the current study, an important predictive factor of biochemical recurrence was pre-S-HIFU PSA. PSA can be used to identify early recurrence following EBRT, and our finding suggests that control biopsy should be performed as soon as possible when biochemical relapse is detected in order to increase the chance of favorable patient outcome with rapid administration of S-HIFU. The accuracy of control biopsy is strengthened by first using contrast-enhanced MRI to identify the local recurrence [24]. When it is possible to define it, the estimated Gleason score is also a prognostic factor.

The incidence of morbidity was substantially reduced with the use of dedicated acoustic parameters for the HIFU treatment. For example, the rate of urethra fistula was less than 1% and severe incontinence was less than 20%. These morbidity rates are consistent with recent data on salvage RP [18]. The most frequently occurring morbidity was bladder outlet obstructions the development of which was secondary to urethral stricture, bladder neck stenosis, or the accumulation of captive necrotic tissue in the treated area. Careful management of the obstruction is necessary in order to reduce risks of complications such as incontinence or pubic bone osteitis. The reported morbidity represents a limitation of S-HIFU, which indicates that patients with a life expectancy of less than 5 years are not appropriate candidates for this salvage therapy following EBRT failure. However, we anticipate that early identification of local recurrence after EBRT followed by rapid administration of salvage therapy with HIFU can reduce morbidity, and offer a curative option for radiorecurrent PCA that lacks many of the disadvantages associated with conventional salvage therapies.

Conclusions

Salvage HIFU for locally radiorecurrent PCa represents an effective therapeutic option with curative potential and acceptable morbidity. In appropriate patients, S-HIFU should be performed shortly following detection of EBRT failure. Use of prognostic factors can assist in the selection of appropriate patients.

Conflict of interest statement

Albert Gelet is a lecturer and consultant for EDAP, Vaulx-en-Velin, France.

References

- [1] Touma NJ, Izawa JI, Chin JL. Current status of local salvage therapies following radiation failure for prostate cancer. *J Urol* 2005;173:373–9.
- [2] Murat FJ, Poissonnier L, Rabilloud M, et al. Mid-term results demonstrate salvage high-intensity focused ultrasound (HIFU) as an effective and acceptably morbid salvage treatment option for locally radiorecurrent prostate cancer. *Eur Urol* 2009;55:640–7.
- [3] Berge V, Baco E, Karlsen SJ. A prospective study of salvage high-intensity focused ultrasound for locally radiorecurrent prostate cancer: early results. *Scand J Urol Nephrol* 2010;44(4):223–7.
- [4] Consensus statement: guidelines for PSA following radiation therapy. American Society for Therapeutic Radiology and Oncology Consensus Panel. *Int J Radiat Oncol Biol Phys* 1997;37:1035–41.
- [5] Roach 3rd M, Hanks G, Thames Jr H, et al. Defining biochemical failure following radiotherapy with or without hormonal therapy in men with clinically localized prostate cancer: recommendations of the RTOG–ASTRO Phoenix Consensus Conference. *Int J Radiat Oncol Biol Phys* 2006;65:965–74.
- [6] Rouviere O, Lyonnet D, Raudrant A, et al. MRI appearance of prostate following transrectal HIFU ablation of localized cancer. *Eur Urol* 2001;40:265–74.
- [7] Ingelman-Sundberg A, Ulmsten U. Surgical treatment of female urinary stress incontinence. *Contrib Gynecol Obstet* 1983;10:51–69.
- [8] Zietman AL, Bae K, Slater JD, et al. Randomized trial comparing conventional-dose with high-dose conformal radiation therapy in early-stage adenocarcinoma of the prostate: long-term results from proton radiation oncology group/American college of radiology 95-09. *J Clin Oncol* 2010;28:1106–11.
- [9] Al-Mamgani A, Heemsbergen WD, Levendag PC, Lebesque JV. Subgroup analysis of patients with localized prostate cancer treated within the Dutch-randomized dose escalation trial. *Radiother Oncol* 2010;96:13–8.
- [10] Agarwal PK, Sadetsky N, Konety BR, Resnick MI, Carroll PR. Treatment failure after primary and salvage therapy for prostate cancer: likelihood, patterns of care, and outcomes. *Cancer* 2008;112:307–14.
- [11] D'Amico AV, Cote K, Loffredo M, Renshaw AA, Chen MH. Pretreatment predictors of time to cancer specific death after prostate specific antigen failure. *J Urol* 2003;169:1320–4.
- [12] Zelefsky MJ, Reuter VE, Fuks Z, Scardino P, Shippey A. Influence of local tumor control on distant metastases and cancer related mortality after external beam radiotherapy for prostate cancer. *J Urol* 2008;179:1368–73. discussion 1373.
- [13] Zapatero A, Minguez R, Nieto S, Martin de Vidales C, Garcia-Vicente F. Post-treatment prostate biopsies in the era of three-dimensional conformal radiotherapy: what can they teach us? *Eur Urol* 2009;55:902–9.
- [14] Ward JF, Sebo TJ, Blute ML, Zincke H. Salvage surgery for radiorecurrent prostate cancer: contemporary outcomes. *J Urol* 2005;173:1156–60.
- [15] Sanderson KM, Penson DF, Cai J, et al. Salvage radical prostatectomy: quality of life outcomes and long-term oncological control of radiorecurrent prostate cancer. *J Urol* 2006;176:2025–31. discussion 2031–32.
- [16] Amling CL, Lerner SE, Martin SK, Slezak JM, Blute ML, Zincke H. Deoxyribonucleic acid ploidy and serum prostate specific antigen predict outcome following salvage prostatectomy for radiation refractory prostate cancer. *J Urol* 1999;161:857–62. discussion 862–3.
- [17] Stephenson AJ, Scardino PT, Bianco Jr FJ, DiBlasio CJ, Fearn PA, Eastham JA. Morbidity and functional outcomes of salvage radical prostatectomy for locally recurrent prostate cancer after radiation therapy. *J Urol* 2004;172:2239–43.
- [18] Heidenreich A, Richter S, Thuer D, Pfister D. Prognostic parameters, complications, and oncologic and functional outcome of salvage radical prostatectomy for locally recurrent prostate cancer after 21st-century radiotherapy. *Eur Urol* 2010;57:437–43.
- [19] Pisters LL, Leibovici D, Blute M, et al. Locally recurrent prostate cancer after initial radiation therapy: a comparison of salvage radical prostatectomy versus cryotherapy. *J Urol* 2009;182:517–25. discussion 525–7.
- [20] Izawa JI, Morganstern N, Chan DM, Levy LB, Scott SM, Pisters LL. Incomplete glandular ablation after salvage cryotherapy for recurrent prostate cancer after radiotherapy. *Int J Radiat Oncol Biol Phys* 2003;56:468–72.
- [21] Bahn DK, Lee F, Silverman P, et al. Salvage cryosurgery for recurrent prostate cancer after radiation therapy: a seven-year follow-up. *Clin Prostate Cancer* 2003;2:111–4.
- [22] Grado GL, Collins JM, Kriegshauser JS, et al. Salvage brachytherapy for localized prostate cancer after radiotherapy failure. *Urology* 1999;53:2–10.
- [23] Aaronson DS, Yamasaki I, Gottschalk A, et al. Salvage permanent perineal radioactive-seed implantation for treating recurrence of localized prostate adenocarcinoma after external beam radiotherapy. *BJU Int* 2009;104:600–4.
- [24] Rouviere O, Girouin N, Glas L, et al. Prostate cancer transrectal HIFU ablation: detection of local recurrences using T2-weighted and dynamic contrast-enhanced MRI. *Eur Radiol* 2010;20:48–55.

ORIGINAL ARTICLE

A prospective study of salvage high-intensity focused ultrasound for locally radiorecurrent prostate cancer: Early results

VIKTOR BERGE¹, EDUARD BACO¹ & STEINAR JOHAN KARLSEN^{1,2}

¹Department of Urology, Oslo University Hospital, Aker, Oslo, Norway, and ²Faculty of Medicine, University of Oslo, Norway

Abstract

Objective. After radical external beam radiation therapy (EBRT), local recurrence may benefit from definitive local therapy. The objective of this study was to evaluate the safety and short-term biochemical results and morbidity after salvage high-intensity focused ultrasound (HIFU) treatment in patients with biopsy-proven local prostate cancer recurrence after EBRT. **Material and methods.** From October 2006 46 patients were treated with HIFU. Bone scan and abdominal CT/MRI scan were negative. Median follow-up was 9 months (range 3–24 months). **Results.** The median prostate-specific antigen (PSA) nadir was 0.3 ng/ml (range 0–24 ng/ml). Eighteen patients (39.1%) were classified as failures. In addition, there were four patients (8.7%) with post-HIFU PSA nadir > 0.5 ng/ml. No patients died during follow-up. One patient developed urethrorectal fistulae and was successfully treated conservatively. Two patients developed urethrocutaneous fistulae. Seven patients (15.2%) and one patient (2.1%) developed grade 2 and grade 3 incontinence, respectively. Seven men (15.2%) had erectile function sufficient for intercourse pre-HIFU and only two men (4.3%) post-HIFU. **Conclusions.** Early results of salvage HIFU in patients with local recurrence of prostate cancer after radical EBRT indicate the procedure to be a reasonable treatment option, but better patient selection criteria are needed. The side-effects are not negligible.

Key Words: HIFU, prostate cancer, salvage treatment

Introduction

External beam radiation treatment (EBRT) and radical surgery are the most common radical treatments for localized prostate cancer. Following EBRT up to 60% of patients may experience disease progression within 10 years [1]. About one-third of these patients have local recurrence only [2,3]. Patients with local recurrence or persistence of cancer have a higher risk of disease progression and metastases [4]. In a recent review on published data of salvage therapies following radiation failure, Touma et al. reported local recurrence to be a strong predictor of distant metastasis [5].

There is no agreement on the optimal management for local recurrence after radiotherapy. Treatment options with curative intent include salvage prostatectomy, cryoablation and high-intensity focused ultrasound (HIFU). Treatment decisions are often based on patient comorbidities and physician expertise and preference. Few centres offer salvage surgery

to this group of patients owing to the severe morbidity profile [6].

Salvage HIFU of radiorecurrent prostate cancer has been offered at this centre as a minimally invasive treatment option for this cohort since October 2006. Since they are working in the first urological clinical unit in Scandinavia to have used this treatment modality for patients with local recurrence of disease after EBRT, the authors feel obliged to present their early, preliminary results. The aim of this study is to report the short-term biochemical results and morbidity after this procedure.

Material and methods

Patients

Since October 2006 salvage HIFU treatment has been used in 46 patients with prostate-specific antigen (PSA) recurrence after radical EBRT. The patient

characteristics before ERBT and at the time of HIFU are shown in Table I. Minimal requirements for treatment were a positive prostate biopsy a minimum of 18 months after EBRT, a negative bone scan and a negative abdominopelvic computed tomographic (CT) or magnetic resonance imaging (MRI) scan. Contraindications were inflammatory rectal disease and anal or rectal stenosis. Initially rectal wall thickness >6 mm was a contraindication, but with improved software technology, this contraindication limit was increased to >8 mm. Prostate volume >40 ml was a contraindication, and then the gland had to be downsized. This was achieved by transurethral resection of the prostate (TURP) 3 months before HIFU in one patient and by androgen deprivation treatment (ADT) in seven patients. Twenty-nine patients (63%) had a history of ADT as an adjuvant therapy in association with EBRT.

Technology

HIFU was performed with an Ablaterm second generation HIFU device (EDAP TMS, Vaulx-en-Velin, France). Primary HIFU treatment of localized prostate cancer consists of standard treatment parameters which entail 100% acoustic power with a 5 s pulse of energy to create each discrete HIFU lesion, with a 5 s delay between the formation of each lesion. Specific postradiation treatment parameters developed by the group of Gelet in Lyon [7] were used. These postradiation treatment parameters consist of a 4 s pulse and 6 s waiting period with 95% of the acoustic power. The parameters were developed in the light of the decreased vascularity of the previously irradiated tissue.

Procedure

General anaesthesia was administered during the procedure. In all patients, a bladder neck incision was performed just before HIFU to reduce the postoperative catheterization period and to avoid bladder outlet obstruction. In addition, a limited TURP was carried out in 30 (65%) of these patients. A three-way catheter was inserted at the end of the endoscopic procedure. The HIFU protocol included the treatment of the entire gland. There were four treatment sections defined by the ultrasound, two sections in each lobe. Before treating the part containing the urethra, the catheter was removed. The lower limit for treatment was 6 mm from the apex of the gland, to reduce the possibility of stress incontinence. Upon completion of the procedure, the catheter was reinserted and then removed 3–5 days later at the referring

Table I. Characteristics of 46 patients treated with salvage HIFU following radiorecurrent prostate cancer.

Mean age (range) at EBRT (years)	60.8 ± 4.9 (51–73)
Risk group (EAU definition) at EBRT, <i>n</i> (%)	
Low	1 (2.2%)
Intermediate	17 (34.8%)
High	28 (60.9%)
Median radiation dose (Gy)	70
Median time lapse (range) between EBRT and HIFU (months)	68.1 (18.2–171.2)
At salvage HIFU	
Mean age (range) (years)	67.8 ± 5.0 (53–78)
Mean (median) PSA (ng/ml)	4.9 ± 2.8 (5.5)
Gleason score at EBRT, <i>n</i> (%)	
6	12 (26.1)
7	7 (15.2)
7a	6 (13.0)
7b	6 (13.0)
8	6 (13.0)
9	2 (4.3)
10	1 (2.2)
Unknown	6 (13.0)
Mean prostate volume (range) before HIFU (ml)	20 ± 5.1 (12–37)

HIFU = high-intensity focused ultrasound; EBRT = external beam radiation therapy; EAU = European Association of Urology; PSA = prostate-specific antigen.

institution. The patients received one treatment session only. Routinely, the patients were discharged on the first postoperative day (Table II). Trimethoprim–sulfamethoxazol was administered preoperatively and prophylaxis was continued with trimethoprim 160 mg twice daily until urinary catheter removal.

PSA was measured every 3 months after HIFU at the urological outpatient clinic or at the referral hospital. Repeated biopsy after HIFU was not routinely performed.

Information on urinary continence was based on the UCLA-Prostate Cancer Index (PCI) quality of life questionnaire, which each patient was invited to answer before HIFU and a minimum of 3 months after HIFU. Gradation of incontinence is depicted in Table III, as are the parameters concerning erectile and general sexual function.

Statistics

Medians and ranges were given for continuous non-normally distributed variables. Percentages were estimated by frequency tables and cross-tabs. Association

Table II. Operative factors and complications in 46 patients treated with salvage HIFU following radiorecurrent prostate cancer.

Discharge time (days after HIFU) (range)	1 (1–2)
Follow-up (months) (range)	9 (3–24)
Dilatation for stricture, <i>n</i> (%)	2 (4.4)
Requiring intervention for stricture/necrotic tissue, <i>n</i> (%)	2 (4.4)
UTI, <i>n</i> (%)	9 (19.6)
Fistulae, <i>n</i> (%)	
Rectourethral fistulae	1 (2.2)
Urethrocuteaneous fistulae	2 (4.4)

HIFU = high-intensity focused ultrasound; UTI = urinary tract infection.

between two categorical variables was assessed by Fisher's exact test.

Failure was defined as initiated ADT or increasing PSA value at last follow-up. The failure rate was stratified according to the pretreatment European Association of Urology (EAU) risk group classification [low-risk

localized prostate cancer (PCa): cT1–T2a and Gleason score 2–6 and PSA < 10 ng/ml; intermediate-risk localized PCa: cT2b–T2c or Gleason score = 7 or PSA 10–20 ng/ml; high-risk localized PCa: cT3a or Gleason score 8–10 or PSA > 20 ng/ml] [8].

PSA doubling time (PSAdt) was calculated with at least two measurements of PSA with a 3 month interval, using log calculations at the website of the Memorial Sloan Kettering Cancer Center (<http://www.mskcc.org/mskcc/html/>).

Two-sided *p* values < 0.05 were considered significant. The analyses were performed in SPSS 17 (SPSS, Chicago, IL, USA) for Windows.

Results

The median follow-up period was 9 months (range 3–24 months). The median PSA nadir was 0.3 ng/ml (range 0–24 ng/ml). Eight patients (17.4%) had started ADT initiated by the referring institution at the last evaluation owing to increasing PSA or

Table III. Self-assessment of urinary continence and erectile function before and after HIFU.

	Before HIFU	After HIFU	<i>p</i>
Urinary continence, <i>n</i> (%)			0.001
No leakage	19 (41.3)	7 (15.2)	
Occasional dribbling (grade I)	13 (28.2)	20 (43.4)	
Frequent dribbling (grade II)	0	7 (15.2)	
No urinary control whatsoever (grade III)	0	1 (2.1)	
Missing	14 (30.4)	11 (23.9)	
Total	46	46	
Erectile function, <i>n</i> (%)			
How would you describe the usual quality of your erections during the last 4 weeks?			0.001
None at all	3 (6.5)	20 (43.5)	
Not firm enough for any sexual activity	14 (30.4)	7 (15.2)	
Firm enough for masturbation and foreplay only	9 (19.6)	8 (17.4)	
Sufficient for sexual intercourse	7 (15.2)	2 (4.3)	
Missing	13 (28.3)	9 (19.6)	
Total	46	46	
How would you characterize your sexual function the last 4 weeks?			0.002
Very bad	10 (21.7)	26 (55.5)	
Bad	15 (32.6)	6 (13.0)	
Fair	4(8.7)	4 (8.7)	
Good	4(8.7)	0	
Very good	0	0	
Missing	13(28.2)	10 (21.7)	
Total	46	46	

HIFU = high-intensity focused ultrasound.

detection of metastasis. The median time for initiating ADT after HIFU was 7.5 months (range 1–15 months). In addition, 10 patients (21.7%) had a rising PSA at the last follow-up. Accordingly, the failure rate was 39.1%. Four patients (8.7%) had a post-HIFU PSA nadir >0.5 ng/ml.

There was no difference in failure rate between high- and intermediate-risk groups ($p = 0.351$).

Twelve high- (42.9%) and five intermediate-risk patients (31.3%) failed to reach a post-HIFU PSA nadir <0.5 ng/ml.

Median PSA_{dt} was 10.3 months (range 1.7–179 months) in the high- and 15.7 months (range 1.9–50.9 months) in the intermediate-risk group. PSA_{dt} was unknown in eight high- (28.6%) and four intermediate-risk (23.5%) patients.

There was no difference in failure rate in patients with pre-HIFU PSA_{dt} <12 months compared with patients with PSA_{dt} >12 months ($p = 0.721$). Regarding the relationship between post-HIFU PSA nadir and pre-HIFU PSA_{dt} stratified for high- and intermediate-risk patients there was a tendency towards higher PSA_{dt} in patients with a PSA nadir <0.5 ng/ml in the intermediate-risk group ($p = 0.072$), but not in the high-risk group ($p = 0.691$).

Complications and side-effects are shown in Tables II and III. A detailed evaluation of the quality of life data from the UCLA-PCI questionnaires, which were offered to the patients before and after HIFU, is currently being performed.

Discussion

This study reports on short-term results only after salvage HIFU treatment. At 9 months' median follow-up the failure rate was 39.1%, defined as increasing PSA value or initiated ADT at the last follow-up. This compares well with other reports [7], even though 28 (60.9%) of the patients were in the high-risk group before radiation therapy. Murat et al. [7] reported the progression-free survival rate (PFSR) to be 53% and 42% in high- and intermediate-risk patients.

The additional four patients who did not achieve a PSA nadir <0.5 ng/ml after treatment may also be in danger of disease recurrence in the future. Seo et al. [9] found that the PSA nadir level >0.5 ng/ml was the only significant predictor on multivariate analysis associated with failure of salvage HIFU therapy. However, there is not yet a definition of successful salvage HIFU treatment based on PSA nadir. After primary HIFU, as is the case with primary cryotherapy, complete ablation of the prostate may not be attained, resulting in the release of measurable PSA from

untreated prostatic tissue [10,11]. Repeated PSA measurement over time may therefore be the best criterion for defining disease progression.

Correct staging of radiorecurrent prostate cancer still represents a great problem. There is at present no reliable diagnostic modality for the detection of micrometastasis. Patients suitable for local salvage therapy may therefore harbour micrometastasis at the time of treatment. After radiotherapy the PSA_{dt} correlates with the site of recurrence. In a study by Hancock et al. [12] patients with local recurrence had a doubling time of 13 months compared with 3 months for those with distant failure. Heidenreich et al. [13] found that PSA_{dt} >12 months was a predictor of organ- and specimen-confined prostate cancer after salvage prostatectomy ($p < 0.002$). In the present series there was no statistical significant association between PSA_{dt} before HIFU and failure, probably owing to the small size of the cohort. However, in the intermediate-risk group there was a tendency towards an association between PSA_{dt} and PSA nadir ($p = 0.072$). Further studies with a longer follow-up time are necessary to reveal whether PSA_{dt} is a marker for better selection of patients.

Twelve (42.9%) high- and five (31.3%) intermediate-risk patients failed to reach a PSA nadir <0.5 ng/ml after HIFU. Recurrence after all salvage therapies seems to be higher for patients who are high risk before radiotherapy than for intermediate- and low-risk patients [13,14]. This is probably due to a higher risk of disseminated tumour cells at the time of primary radiotherapy [15]. Undiagnosed metastasis before HIFU is certainly part of the explanation for the poor results observed in the high-risk population [7].

HIFU caused a significant deterioration in voiding and erectile function (Table III). The rate of incontinence may be reduced in some patients by not treating the apex of the prostate in cases proven cancer negative by biopsies from this region. Erectile function was considerably reduced before salvage HIFU, probably owing to advanced age and previous radiotherapy.

Since the introduction of new treatment parameters in 2002 [7], urethrorectal fistulae are rare after salvage HIFU. In the patient who developed a rectourethral fistula in the present study, MRI imaging 4 months after HIFU confirmed the fistula to be healed by prolonged bladder catheterization. It is also highly probable that the urethrocutaneous fistula formation to the symphysis pubis and groin is related to the HIFU procedure, although the authors are not aware of these complications being reported in previous publications. Both of these complications occurred at referral institutions in patients with concomitant

urinary infection and it is hypothesized that they have were precipitated by catheterization of the urethra with a very vulnerable mucosa after HIFU, causing an infectious fistula. The rare problem of urethrocutaneous fistula formation may favour bladder drainage with suprapubic catheter during the postoperative period.

In conclusion, early results of salvage HIFU in patients with local recurrence of prostate cancer after radical EBRT indicate the procedure to be a reasonable treatment option, but better patient selection criteria are still requires. However, the side-effects are not negligible.

Acknowledgements

The authors acknowledge statistician Lien My Diep at the Research Department, Aker University Hospital, for help in preparation of the manuscript

Declaration of interest: The authors report no conflicts of interest. The authors alone are responsible for the content and writing of the paper.

References

- [1] Kuban DA, Thames HD, Levy LB, Horwitz EM, Kupelian PA, Martinez AA, et al. Long-term multiinstitutional analysis of stage T1–T2 prostate cancer treated with radiotherapy in the PSA era. *Int J Radiat Oncol Biol Phys* 2003;57:915–28.
- [2] Crook J, Malone S, Perry G, Bahadur Y, Robertson S, Abdollell M. Postradiotherapy prostate biopsies: what do they really mean? Results for 498 patients. *Int J Radiat Oncol Biol Phys* 2000;48:355–67.
- [3] Pollack A, Zagars GK, Antolak JA, Kukan DA, Rosen II. Prostate biopsy status and PSA nadir level as early surrogates for treatment failure: analysis of a prostate cancer randomized radiation dose escalation trial. *Int J Radiat Oncol Biol Phys* 2002;54:677–85.
- [4] Coen JJ, Zietman AL, Thakral H, Shipley WU. Radical radiation for localized prostate cancer: local persistence of disease results in a late wave of metastases. *J Clin Oncol* 2002;20:3199–205.
- [5] Touma NJ, Izawa JI, Chin JL. Current status of local salvage therapies following radiation failure for prostate cancer. *J Urol* 2005;173:373–9.
- [6] Rukstalis DB. Treatment options after failure of radiation therapy – a review. *Rev Urol* 2002;4:S12–7.
- [7] Murat F-J, Poissonnier L, Rabilloud M, Belot A, Bouvier R, Olivier R, et al. Mid-term results demonstrate salvage high-intensity focused ultrasound (HIFU) as an effective and acceptably morbid salvage treatment option for locally radiorecurrent prostate cancer. *Eur Urol* 2009;55:640–9.
- [8] EAU guidelines address: <http://www.uroweb.org/>.
- [9] Seo SI, Jeon SS, Jo MK, Lee HM, Choi HY. Salvage high-intensity focused ultrasound (HIFU) therapy for locally recurrent prostate cancer after primary HIFU or external beam radiotherapy (EBRT). *Eur Urol Suppl* 2008;7:119.
- [10] Chin JL, Touma N, Pautler SE, Guram KS, Bella AJ, Downey DB, et al. Serial histopathology results of salvage cryoablation for prostate cancer after radiation failure. *J Urol* 2003;170:1199–202.
- [11] Izawa JI, Morganstern N, Chan DM, Levy LB, Scott SM, Pisters LL. Incomplete glandular ablation after salvage cryotherapy for recurrent prostate cancer after radiotherapy. *Int J Radiat Oncol Biol Phys* 2003;56:468–72.
- [12] Hancock SL, Cox RS, Bagshaw MA. Prostate specific antigen after radiotherapy for prostate cancer: a re-evaluation of long-term biochemical control and the kinetics of recurrence in patients treated at Stanford University. *J Urol* 1995;154:1412–7.
- [13] Heidenreich A, Richter S, Thu D, Pfister D. Prognostic parameters, complications, and oncologic and functional outcome of salvage radical prostatectomy for locally recurrent prostate cancer after 21st-century radiotherapy. *Eur Urol* 2010;57:437–43.
- [14] Langenhuijsen JF, Eveline MP, Broers EWP, Vergunst H. Cryosurgery for prostate cancer: an update on clinical results of modern cryotechnology. *Eur Urol* 2009;55:76–86.
- [15] Berg A, Berner AA, Lilleby W, Bruland ØS, Fossa SD, Nesland JM, et al. Impact of disseminated tumor cells in bone marrow at diagnosis in patients with nonmetastatic prostate cancer treated by definitive radiotherapy. *Int J Cancer* 2007;120:1603–9.

TRANSRECTAL HIGH INTENSIVE FOCUSED ULTRASOUND (HIFU) FOR THE TREATMENT OF PROSTATE CANCER: A HISTORICAL REVIEW

Authors

*Christian G. Chaussy,
MD, HonFRCSed

Chairman Emeritus
Dept. of Urology,
Klinikum Harlaching,
Univ. of Munich,
Germany
Professor of Urology
University of
Regensburg,
Harlacher Krebshilfe
e.V., Klinikum
Harlaching, Munich,
Germany
Email:
cgchaussy@gmail.com

Stefan Thüroff, MD
Vice Chairman Dept. of
Urology Klinikum
Harlaching, Munich,
Germany
Harlacher Krebshilfe
e.V., Klinikum
Harlaching, Munich,
Germany
Email: sthueroff@mnet-online.de

Abstract

Prostate cancer is diagnosed 10 years earlier and men live almost 4 years longer than 30 years ago. This means that the therapeutic necessity is more than double the time than it was then. None of the classical therapies is effective enough to cover this time frame as a monotherapy without a significant risk of aggressive recurrence during these years

These changing trends in age and extent of malignancy at diagnosis have revealed limitations in conventional curative therapies for prostate cancer, including a significant risk of cancer recurrence, and the risk of long-term genitourinary morbidity and its detrimental impact on patient quality of life (QOL). Greater awareness of the limitations in radical prostatectomy, external radiotherapy and brachytherapy have prompted the search for alternative curative therapies that offer comparable rates of cancer control and less treatment-related morbidity to better preserve QOL. High intensity focused ultrasound (HIFU) possesses characteristics that make it an attractive curative therapy option. HIFU is a non-invasive approach that uses precisely delivered ultrasound energy to achieve prostate tissue necrosis without radiation or surgical excision. In current urological oncology, HIFU is used clinically in the treatment of prostate cancer, and is under experimental investigation for therapeutic use in multiple malignancies. Clinical research on HIFU therapy for localized prostate cancer began in the 1990s, and there have now been approximately 40,000 prostate cancer patients treated with HIFU. Neoadjuvant transurethral resection of the prostate (TURP) has been combined with HIFU since 2000 to reduce prostate size, facilitate tissue destruction, and to minimize side effects. Advances in imaging technologies are expected to further improve the already superior efficacy and morbidity outcomes, and ongoing investigation of HIFU as a focal therapy in salvage and palliative indications are serving to expand the role of HIFU as a highly versatile non-invasive therapy for prostate cancer.

Keywords

HIFU: High Intensity focused Ultrasound non-invasive PCa Therapy focal therapy castration resistant PCa

Introduction

Although knowledge that tissue destruction can be achieved with high-intensity focused ultrasound (HIFU) has been around since the 1930s, efforts to clinically implement this technology were delayed due to the absence of imaging technology to monitor the procedure [1]. Basic research in the urological application of HIFU began in the 1980s, when computer technology became sufficient to facilitate the control and management of this fascinating radiation free energy source. The first clinical prototypes for use in urology emerged during this period.

Clinical trials of HIFU began in the early 1990s in Europe, Japan, and the USA, with initial evaluation as a therapy for benign prostatic hyperplasia. HIFU demonstrated safety and efficacy through the precise destruction of local tissue. Also observed was the induction of a significant shrinkage process within the treated organ and resultant therapy-related side effects. Thus, HIFU was found to possess the effective attribute needed for cancer treatment of tissue destruction, but it was not effective in infravesical de-obstruction, where obstruction was increased from shrinkage and necrotic tissue. Early clinical trials of HIFU therapy for prostate cancer during the mid-late 1990s found a relationship between the coagulated prostate volume and obstruction, and analysis of prospective

studies also found a high rate of urinary tract infections in this necrotic tissue. As the result of the association between HIFU and obstruction, and consistent with the whole-gland concept of therapy, HIFU has been routinely combined with a neoadjuvant TURP since 2000 [2,3] to debulk the tumor mass and radically resect the middle lobes, calcifications, abscesses, and bladder neck [4].

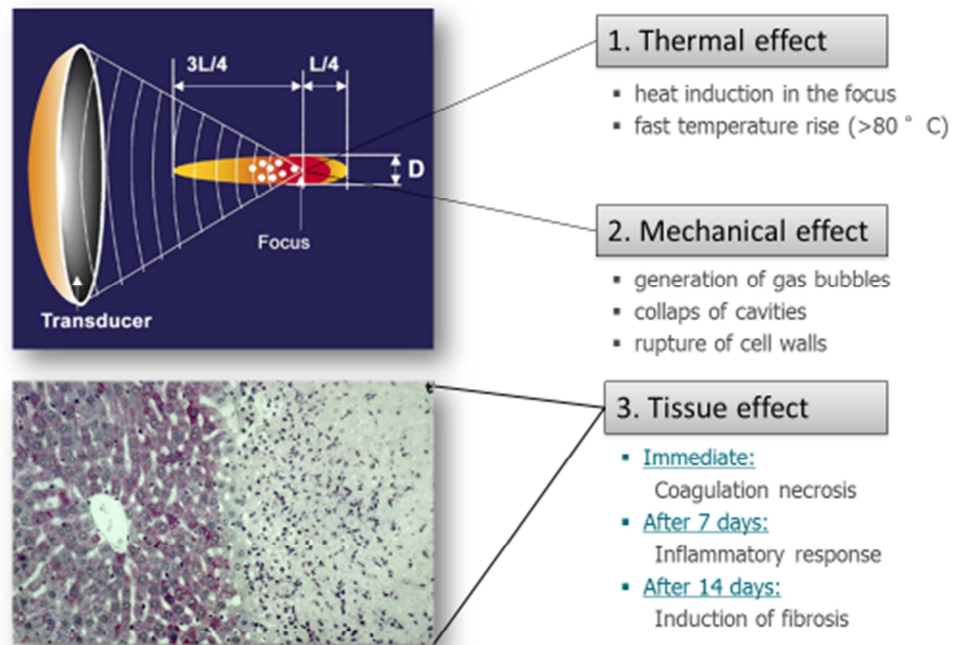
HIFU therapy has been extended to different surgical indications such as use as an extracorporeal method that allows non-invasive coagulative destruction without an open surgical procedure. The validation and international acceptance of transrectal HIFU treatment of prostate cancer has been increasing as the result of the growing clinical experience and published research on HIFU. 15-year efficacy results are available [5,6].

Material and Method

The first use of HIFU in local tissue destruction was reported in 1944 by Lynn and Putman [7]. The use of high-energy parabolic-focused ultrasound results in the mechanical alteration and changes in the biological structure of targeted volumes [1]. During the application of focused ultrasound, two different physical mechanisms account for its treatment effect: thermal and mechanical.

Figure 1: physical principle of focused energy application

High Intensity Focused Ultrasound (HIFU) Technique



The ultrasound energy produced by HIFU is absorbed by the targeted tissue and converted into heat. The extent of temperature increase in the tissue depends on the absorption coefficient of the tissue, and the size, shape and temperature sensitivity of the heated area [1]. Biological changes caused by the heating depend on the temperature level and duration of exposure. A "thermal dose", which exceeds a certain threshold, causes tissue coagulation and leads to irreversible tissue damage through coagulative necrosis [8]. The focused ultrasound waves of HIFU are capable of inducing sharp increases in temperature (around 70 °C to 100 °C) within a few seconds. During the clinical use of HIFU, the tissue-sensitive adjacent structures such as the rectum, external sphincter, and the neurovascular bundles

are spared from destruction due to the steep temperature gradient between focal tissue and surrounding region [8,9].

The mechanical effects of HIFU are induced by the impact of oscillating pressure of the ultrasound wave on the targeted tissue [1]. The pressure causes bubbles to form inside the targeted cells which increase in size to the point at which resonance is achieved. High pressure of 20,000–30,000 bars develops when these bubbles suddenly collapse, causing damage to nearby cells and the formation of a cavitation effect within the tissue which damages cell membranes [10]. The primary single lesions are small (1.7x 19–26 mm) and produce reproducible volumes of sharply demarcated ablation [9]. The small volume of tissue destroyed by a single

shot of ultrasound is termed “elementary” or “primary” lesion. To create larger lesions, several elementary lesions are made side by side, by adding multiple lesion targets to the algorithm

and either mechanically moving the transducer or by electronically positioning the focal point if a phased array is available [8,11-15].

Figure 2:

- a) multiple lesion application mode and
- b) volume coagulation (transducer movement algorithm)

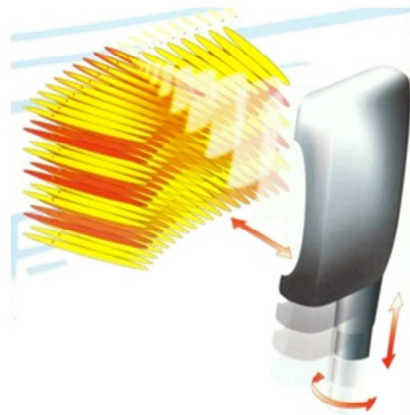


Figure 2a




Figure 2b

Experimental evaluation and clinical parameters

In vitro, in vivo, and computer simulation studies were conducted to identify and refine the ultrasound parameters required for the clinical treatment of prostatic disease. The destruction of tumors with HIFU in these studies provided the evidence that cancerous tissues can be destroyed by HIFU without inducing metastases [16],

and that prostatic tissue can effectively be targeted through transrectal delivery of HIFU [17,18].

High-intensity focused energy can be delivered as a pulsed or a continuous beam [19]. The latter process includes solar waves, microwaves and radar technology, whereas pulsed HIFU is applied as medical HIFU and extracorporeal shockwave lithotripsy. The high-frequency vibration (0.5–10

MHz) of a piezoelectric or piezoceramic transducer generates ultrasound waves, which are collected into a focal point by a concave or parabolic arrangement [10].

Essential parameters for the medical use of HIFU include the ultrasound frequency (MHz), the acoustic intensity (Watts), the duration of application (shot-time), the intervals of the pulses (delay-time), the lateral and vertical distance between elementary lesions, the longitudinal displacement of the energy source when applying multiple lesions, and the penetration depth (focal point) dependent on the applicator design [1].

These multiple technical parameters are essential in the assembly of a HIFU system with a dedicated application for specific tissue. Complex technical decisions are involved in HIFU operation, and include the selection and design of the piezoelectric energy applicator, the parameters of ultrasound treatment (MHz, Watts), the application algorithm (impulse-delay relation), the imaging system, the intraoperative target and safety features, target localization

during treatment with TRUS or MRI, and controls [1].

The ultrasonic energy transducer is characterized mainly by its operating frequency, and geometric and physical dimensions. Piezoelectric systems can be operated with sufficient energy density, reproducibility and long-term stability in accordance with the requirements of the therapy, which allow the production of geometric shapes for adaptation to changing anatomical needs [13]. Current standard urological applications use HIFU transducers with a fixed but adjustable focal point to be moved mechanically to treat a larger tissue volume [14,15].

Commercially available treatment technologies

There are two devices which differ in numerous dimensions. [Table 1] HIFU with Ablatherm® constitutes the majority of research involving prostate cancer therapy with HIFU. [20] Studies involving the Ablatherm® device are the major focus of this review.

Table 1: Technical Data of the Available HIFU Devices

Features	Sonablate 450/500® (by Sonacare)	Ablatherm int. imaging® (by EDAP-TMS)	Focal One® (by EDAP-TMS)
Rectal wall safety control	visual/manual	US/automatic	US/automatic
Applicators adjustment mode	Manual	Robotic (autofocus)	Robotic(autofocus)
Max. ventral prostatic HIFU penetration (mm)	30	24	40
HIFU power settings	manual	automatic	automatic
Rectal balloon pressure	low	high	flexible
TRUS frequency (MHZ)	4 / 6.3	7.5	7.5
HIFU frequency (MHZ)	4	3.5	3.5
Shot / delay mode	on/off, rhythmic	on/off, rhythmic	on / continuous
Treatment speed / 10cc	90min	60min	40min
TURP before?	obstructive or >40cc: Yes focal or <40cc: No	obstructive or >25cc: Yes focal or <25cc: No	obstructive or >50cc: Yes focal or <50cc: No
patients OR position	lithotomy	right lateral	right lateral

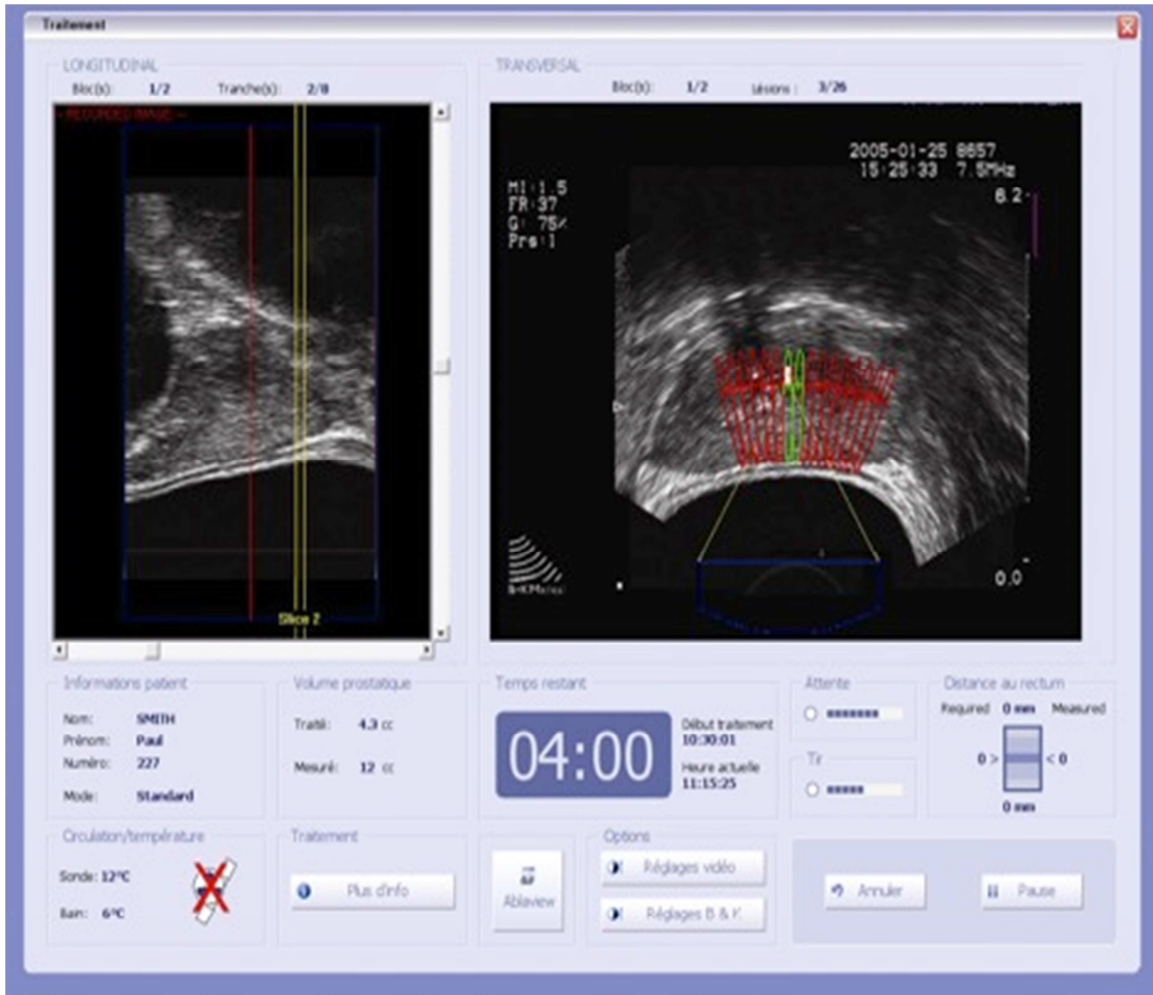
Ablatherm®

The Ablatherm® machine consists of a treatment module that includes the patient's bed, the probe positioning system, the ultrasound power generator, the cooling system for preservation of the rectal wall, and the ultrasound scanner used during the treatment localization phase. There is also a treatment and imaging endorectal probe that incorporates both an imaging probe working at 7.5 MHz and a treatment transducer focused at a maximum of 45 mm working at 3 MHz [21]. Numerous safety features have been incorporated,

starting with a safety ring that stabilizes the rectal wall mechanically during transducer movements. Consecutively a permanent control of the distance between the therapy transducer and the rectal wall, and a patient motion detector that stops treatment if the patient moves during the firing sequence have been integrated [21].

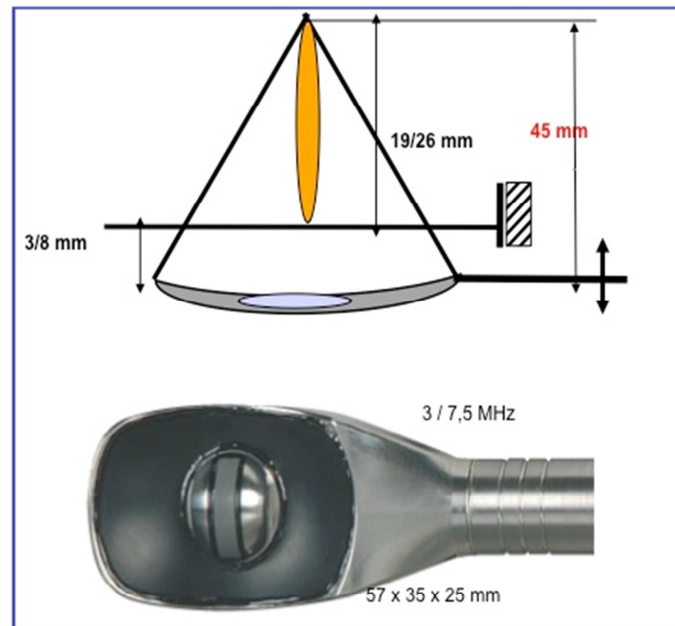The treatment parameters are selected to optimize the size of the lesion while leaving the rectal wall and surrounding tissues intact.

Figure 3: Intraoperative, 3 dimensional, real time, transrectal ultrasound for visual treatment planning and control on control screen



The size of the elementary lesion is between 19 and 26 mm in length and 1.7 mm in diameter. Because the shape of the lesion depends on gland perfusion, treatment parameters are different according to the patient's status: 5 s treatment pulse and 5 s shot interval for

the first HIFU session in primary-care treatment; 4.5 s treatment pulse and 5 s shot interval for the second session in primary care; and 4 s treatment pulse and 7 s shot interval for local relapse after external-beam radiation therapy [21].

Figure 4a: Focal point adjustment, penetration depth (19-26 mm)

HIFU is delivered as a single-session therapy applying 100 of consecutive lesions under spinal or ITN anesthesia for a duration of 1 to 2 hours. The treatment is conducted with the patient in the lateral position. The endorectal probe containing a curved piezoelectric crystal and a transrectal ultrasound (TRUS) scanner is placed in a latex balloon filled with cooling fluid and introduced into the rectum. This probe collects emitted ultrasound beams at a focal point. Following definition of the target volume boundaries by the operator, treatment is performed from the apex to the base of the prostate. Usually 4 to 6 successive target volumes are defined in order to treat the entire prostate. During the HIFU session, a Foley-type urinary catheter or a suprapubic tube is positioned [21].

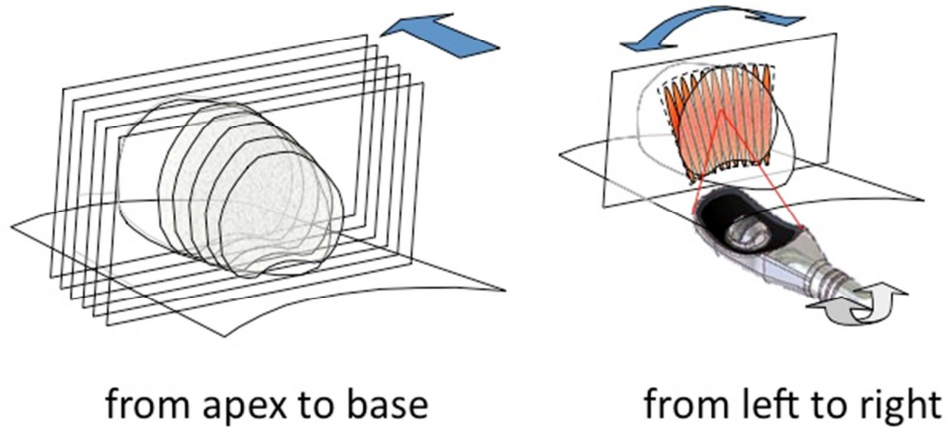
Sonablate®

Unlike the Ablatherm® machine, the Sonablate® system has no dedicated bed. Several treatment probes are available, and are selected by the operator according to the size and intraprostatic position of the elementary lesion: 10 mm in length and 2 mm in diameter for a single beam performing with 25 mm or 45 mm focal-length probes; and 10 mm in length and 3 mm in diameter for a split beam performing with 30, 35 or 40 mm focal-length probes [20,22]. Treatment parameters vary depending on operator's choice.

Treatment is performed with the patient in a lithotomy position under general anesthesia. The probe is chosen depending on prostate size, with larger glands requiring longer focal lengths.

The treatment is usually made in three consecutive layers, starting from the anterior part of the prostate and progressively moving to the posterior part, with at least one probe switch during the procedure [22].

Figure 4b: Focal point adjustment, latero-longitudinal (1.7 mm steps)



Tissue effects

The clinical potential of HIFU in the treatment of prostate cancer was established in a clinical trial where patients received HIFU 1 to 2 weeks before receiving radical prostatectomy, followed by histologic examination of the removed prostate. HIFU was delivered to regions of the prostate where biopsies had revealed cancer, and histologic examination found a sharp demarcation between HIFU-treated and untreated areas, with complete necrosis in all specimens [23]. Fat-saturated gadolinium-enhanced MRI has

demonstrated the extent of the tissue damage induced by HIFU. Treated areas appear as a non-enhancing hypointense zone surrounded by a peripheral rim of enhancement 3 to 5 mm thick. These abnormalities correspond to a nucleus of coagulation necrosis surrounded by a peripheral zone of inflammation. Treatment-induced abnormalities visible with MRI usually disappear in 3–5 months in a centripetal manner, and HIFU-induced tissue contraction results after about 6 months in small prostates of approximately 5- 10 cc [24].

Imaging

MRI is considered the gold-standard technique used for assessing the efficacy of HIFU treatment. The extent of necrosis can be clearly visualized on gadolinium-enhanced T1-weighted images, as hyposignal zones [25]. MRI has also been used to guide HIFU treatments [25,26], as it is possible to monitor the temperature changes within tissues with MRI during HIFU [25]. Magnetic resonance elastography has also been proposed as a method for assessing the effects of thermal tissue ablation by measuring the mechanical properties of the lesion [26]. It remains unclear whether elastographic changes are correlated with long-term tissue destruction and whether they reflect complete tissue coagulation at a cellular level [27]. HIFU-induced lesions are visible using standard ultrasound as hyperdense regions; however, the real extent of primary lesion destruction cannot be defined precisely because of variations across patients in interfering effects such as HIFU reflection (prostatic capsule, calcifications, catheters); absorption (untreated or pretreated tissue); and cooling (blood vessels, intraprostatic TURP cavity liquid) [28]. Techniques to improve characterization based on ultrasound, contrast-enhanced Doppler [29], and measurement of the acoustic behavior of tissues have been proposed to more accurately determine the extent of HIFU-induced lesions [30]. During 20 years of clinical experience with HIFU treatment of prostate cancer, transrectal ultrasound has been shown to be a safe reproducible technique even without "real time" temperature measurement. However, a "real time" technology that compensates for the limitations in tissue visualization mentioned above would be

an advantage that would help to optimize tissue ablation efficacy by minimizing the targeted volume [1].

Indications

The most widespread use of HIFU, and initially the only indication for its use, has been in patients with localized prostate cancer (T1–2N0M0; Gleason sum ≤ 6) who are not candidates for surgery because of age, general health status, a prohibiting comorbidity or a preference not to undergo a radical prostatectomy [1]. However, with the accumulation of clinical experience and expansion of research protocols these indications have broadened to include partial therapy in unilateral low-volume, low-GS tumors (T1–2aNx/0M0; PSA ≤ 20 ng/ml); salvage therapy in recurrent prostate cancer following radical prostatectomy, radiation therapy or hormone ablation (all TNx/0M0; all GS/PSA) [31]; advanced prostate cancer as an additional neoadjuvant debulking process (T3–4Nx/0M0; all GS/PSA); and in castration resistant prostate cancer (CRPCa) [32]. HIFU is used in intermediate- and high-risk patients. Most studies have used HIFU with inclusion of these patient groups with reasonable outcomes [33,34], but as with the other curative therapies, high-risk patients have a lower longterm success rate than low-risk patients. Remaining contraindications common to both HIFU devices include a missing or small rectum, and a damaged rectal wall from previous prostatic or rectal therapies [1].

The diagnosis of prostate cancer is based on the histopathological examination of biopsies in cases of suspicious PSA findings, digital rectal examination, magnetic resonance imaging, transrectal ultrasound (TRUS), or unexpected

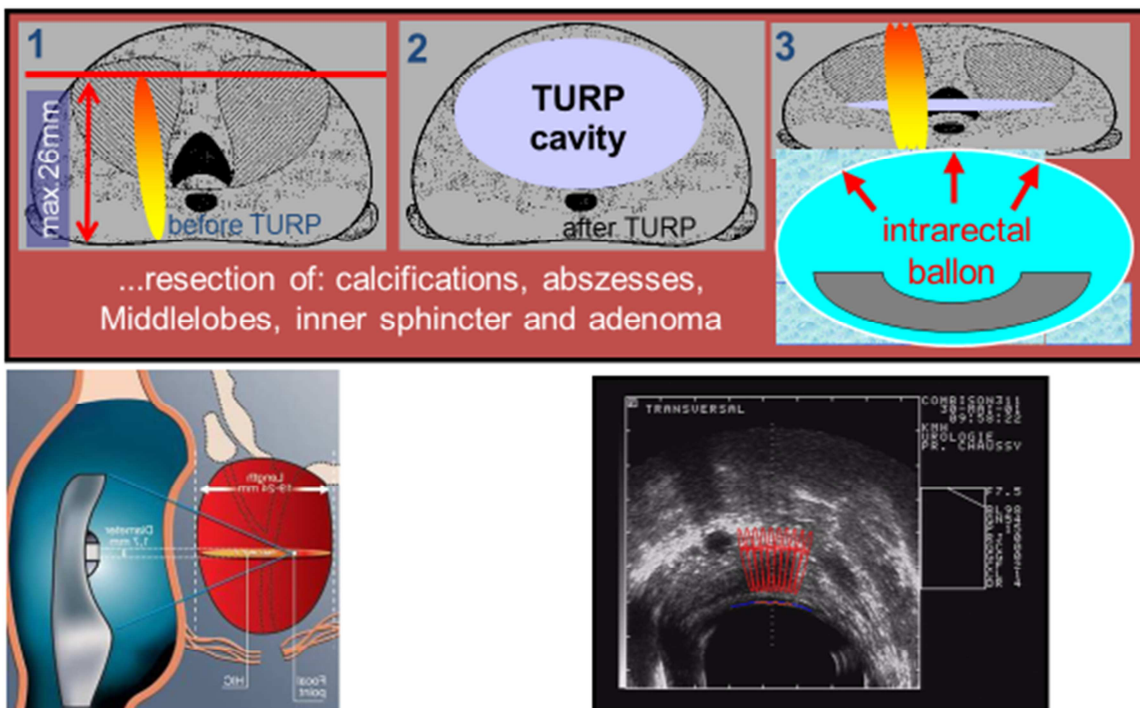
findings in resected tissue after open adenomectomy, holmium ablation, or transurethral resection [35].

TURP and HIFU

The use of TURP with HIFU became routine practice in 2000 as a means to reduce post-HIFU urethral sloughing and obstruction, and offers several other advantages over HIFU alone.

Figure 5

Compression of TUR defect by rectal balloon



The combined procedure of TURP prior to HIFU in patients with localized prostate cancer allows the instant removal of any reflecting or deviating calcifications of the transitional zone that would prevent HIFU treatment, as well as abscesses, intravesical middle lobes and large (> 40 ml) adenomas [1]. The generation of a cavity and its subsequent compression by the rectal balloon increases the accessibility of the HIFU waves to the remaining gland,

fixes the residual prostate behind the symphysis, avoids movement artefacts, and allows the complete treatment of the peripheral zone in a single HIFU session. The penetration depth of the HIFU device is 19 - 24 mm, and therefore, without a TURP, a larger gland size (> 30 ml) cannot be treated completely. TURP decreases the size of each prostate gland to approximately 25 ml to eliminate size restriction with HIFU [2,36].

Results

Localized disease

Similar to efficacy studies with external beam radiotherapy, brachytherapy, and cryoablation, biochemical markers and biopsy findings have been used as indicators of long-term cancer control with HIFU. To date there is no universal consensus on the definition of biochemical failure in patients treated with HIFU [1]. With ongoing refinements in execution and outcome measurement, the efficacy of HIFU in locally confined prostate cancer is now comparable to those of radiotherapy and radical prostatectomy, which according to the CaPSURE database are characterized by failure rates of 63% at a mean of 38 months post treatment and 30% at a mean of 34 months post treatment, respectively [37].

Early efficacy studies of HIFU defined complete response as a negative control biopsy and a PSA nadir < 4.0 ng/ml. [38,39]. Stricter criteria for treatment failure were applied by Gelet et al., with failure defined as any positive biopsy or three successive elevations in PSA with a velocity of 0.75 ng/ml/year or greater [40]. The French Urological Association guidelines in 2005 stated that biopsy was required if there were three successive elevations in PSA level over a 3-month period but not if the PSA nadir was less than 1.0 ng/ml [41]. The American Society for Therapeutic Radiology and Oncology (ASTRO) definition of disease-free status based on biochemical outcome has been applied to HIFU. PSA failure was also defined as three consecutive PSA rises after a nadir, with

the date of failure being the halfway point between the nadir date and the first rise or any rise great enough to provoke initiation of salvage therapy [34]. This definition was subsequently modified to the Phoenix definition of failure as the time at which $PSA > \text{nadir} + 2.0 \text{ ng/ml}$ was reached. A number of HIFU studies have now applied the ASTRO or Phoenix definitions.

[Table 2] provides a summary of HIFU efficacy in localized prostate cancer.

HIFU efficacy has also been reported in terms of a negative biopsy rate, which is likely to provide the best proof of definitive efficacy despite the associated sampling error. The lowest negative biopsy rate was reported by Gelet et al. in 2001 [42], which included patients treated with prototype devices. The only other series reporting a negative biopsy rate less than 80% was by Ficarra et al. [33], who included patients with high-risk prostate cancer [6]. In more recent series, negative biopsy rates have ranged from 93–96% [5,43]. Re-treatment rates have also been reported in the literature but their interpretation is confounded by the former practice of using two treatment sessions with only one prostatic lobe treated in each session. This approach was common in the studies of Gelet et al. [42] and Poissonnier et al. [6,44]. The only series that did not use this approach was the series involving high-risk patients reported by Ficarra et al. [33]. Unfortunately, the proportion of patients treated intentionally with two sessions versus those re-treated due to clinical failure was not reported in these studies.

Table 2. Robotic High-Intensity Focused Ultrasound: Efficacy Summary

Study (year)	n	Pretreatment PSA (ng/ml)	Gleason score	Stage	Median Follow-up (months)	Negative Biopsy rate (%)	Biochemical survival	Retreatment rate (%)
Chaussy et al. (2001)	184	12		T1-2 Nx		80	NR	26.1
Gelet et al. (2001)	102	8.38 (mean)	54% 2-6 46% 7-10	T1-2	19	75	66% at 5 years (ASTRO)	78.4
Poissonnier et al (2003)	120	5.67 (mean) 100% <10	64% 2-6 36% 7-10	T1-2	27	86	76.9% at 5 years (ASTRO)	1.4 Tx per patient
Thüroff et al. (2003)	402	10.9 (mean)	13.2% 2-4 77.5% 5-7 9.3% 8-10	T1-2	13	87.2	NR	36.7
Blana et al. (2004)	146	7.6 (mean)	5 ± 1.2	T1-2 NOMO	22	93.4	84% at 22 months (PSA < 1.0)	18.7
Ficarra et al. (2006)	30	18 (median)	17% 7 33% 8 37% 9 13% 10	30% T2b 70% T1-2 NOMO	6	77	90% at 1 year (PSA > 0.3)	0
Poissonnier et al (2007)	227	7.0 (mean)	67% 2-6 33% 7	T1-2	20.5	86	NR	42.7
Blana et al. (2008)	140	7.0 (mean)	5.2 ± 1.4	T1-2 NOMO	76.8 (mean)	96.4	77% at 5 years (PHOENIX)	29.3
Blana et al. (2008)	163	5 (median)	7.9 ± 3.7	T1-2 NOMO	57.6 (mean)	92.7	75% at 5 years (PHOENIX)	20.8

Blana et al. reported HIFU treatment outcomes by utilizing a large international patient series from the @-Registry [45]. Patients in the @-Registry were stratified according to D’Amico’s 2003 risk group definitions [46] and Kaplan–Meier analysis was performed to determine biochemical survival, with failure defined by the Phoenix definition (PSA nadir +2 ng/mL). The overall 5-year biochemical survival rate was 85%.

In a series of 120 patients with localized prostate cancer and PSA values of <10ng/ml, cancer-free survival rates were examined [6]. The calculated cancer-free 5-year survival rate for the overall patient population was 76.9%, 85.4% in highly differentiated tumors

(Gleason score 2-6), and 61.3% in poorly-differentiated tumors (Gleason score 7–10). There were no significant differences in survival rates based on prostate volume or the number of positive biopsies. Also, PSA nadir displayed predictive relevance, with actuarial 5-year survival rates of 86% in patients with a nadir PSA <0.5 ng/ml.

A European multicenter study reported the short-term results of 402 patients with localized prostate cancer (T1-2/N0-x/M0) treated between 1995 and 1999 [48]. At 1-year follow-up, 87.2% of control biopsies were negative. When stratified by prognostic risk, the negative biopsy rate was 92.1% in low risk (Gleason < 7) patients, 86.4% in

medium risk (Gleason 7) patients, and 82.1% in high risk (Gleason > 7) patients. PSA nadir occurred 3 to 4 months after HIFU treatment, and was significantly influenced by the prostate volume in relation to the extent of completeness of the HIFU treatment.

Blana et al. [5] reported the results of 140 patients with baseline PSA \leq 15 ng/ml and Gleason score \leq 7. TRUS biopsies 6 months following HIFU treatment were negative in 93.4% of patients. The mean PSA nadir was 0.07 ng/ml, with PSA values remaining stable at a mean of 0.16 ng/ml during the 22 month mean observation period. The rates of freedom from biochemical relapse at 5- and 7-year follow-ups were 77% and 69%, respectively, which are comparable to those reported in large

studies of standard curative therapies for localized prostate cancer [49-51].

A study with the longest patient follow-up was published in 2010 by Crouzet et al. [52]. The authors reported the results of a multicenter trial consisting of 803 patients followed for a mean of 42 ± 33 months. Based on the Phoenix definition, 5- and 7-year biochemical survival was achieved by 83% and 75% of low-risk patients, respectively, and by 72% and 63% of intermediate-risk patients, respectively. Negative biopsy rates for low- and intermediate-risk patients were 84.9% and 73.5%, respectively. Also observed was an 8-year overall, metastasis-free, and cancer-specific survival of 89%, 97%, and 99% respectively. Further longterm results after HIFU treatment are given in table 3.

Table 3

Longterm Results after HIFU Treatment

	Risk Group	n	Ten Year Cancer Specific Survival	Ten Year Metastases Free Survival
Ganzer 2013	Low	229	100%	100%
	Intermediate	211	96%	94%
Thüroff 2013	All localized (72% mod or high)	704	99%	95%
Crouzet 2013	Low	357	99%	99%
	Intermediate	452	98%	95%
	High	174	92%	86%

Ganzer R, BJU Int. 2013 Aug;112(3):322-9; Thüroff S, Chaussy C: J Urol. 2013 Aug;190(2):702-10. Crouzet S, Eur Urol. 2014 May;65(5):907-14.

Sonablate HIFU for PCa primary therapy

Authors retrieved seven case series assessing Sonablate HIFU as a primary therapy option in prostate cancer (Table 3) that were carried out by three study groups in the United Kingdom, Italy, and Japan [53 - 59]. Between 63 and 517 patients were treated with Sonablate HIFU who were recruited consecutively in four case series [54,56 - 58]. Both localized (T1–T2, N0, M0) as well as locally advanced (T3, N0, M0) prostate cancers were treated using the Sonablate device. Median patient age, reported in all but one study, was between 68 and 72 years [60–64].

Gleason score was 7 in most patients, and median preoperative prostate

volume was 22–33 mL; between 29% and 66% of men received neoadjuvant ADT. TURP was either not carried out or no information was provided. Patients received one to four HIFU treatments, but most (79–86%) were treated only once. A median follow-up was between 14 and 34 months; mean follow-up of 12 months was reported in one study [53]. The biochemical disease-free survival rate was given in six case series and varied between 78% and 84% at 1 year, 0–91% at 2 years, 20–86% at 3 years, and 45–84% at 5 years. The negative biopsy rate was assessed in five studies [54-58], but the time of biopsy was only presented in three of them [54-56]. The negative biopsy rate was 19–89% at 6 months and 77%–84% at 12 months.

Incidental disease in PBH

Histological examination reveals prostate cancer in up to 8% of the patients who undergo adenomectomy/holmium-laser enucleation or transurethral resection of the prostate (TURP) because of symptomatic benign prostatic hyperplasia. Consequently, some of these patients want a therapeutic approach for their prostate cancer [35].

Results have been reported on 65 patients treated with HIFU for incidental prostate cancer. Patients were 70 years in average, with a median initial PSA of 4.9 ng/mL and a prostate volume of 39 mL, of which an average of 20 g (1–95 g) had been resected. Histology showed 5% (5% to 50%) positive chips and an average Gleason scale of 5 (3–9). Patients were treated with single-session full-gland transrectal HIFU. At follow-up, a median PSA nadir of 0.07 ng/mL was achieved at 1.8 months, including 62% with PSA < 0.1 ng/mL and 81% with PSA < 0.5 ng/mL. A median PSA of 0.13 ng/mL, equivalent to a median PSA velocity of 0.01 ng/mL/y, was found after a median follow-up of 48 months

The PSA nadir of 0.07 ng/mL and the PSA velocity of 0.01 ng/mL/y indicated that HIFU can be used as a curative

therapy in patients with incidental prostate cancer.

Morbidity

The most common side effects of primary HIFU therapy include prolonged voiding dysfunction and retention caused by edema, necrosis or bladder outlet obstruction, as well as erectile dysfunction. Among patients receiving HIFU as primary therapy, Grade I stress incontinence occurs in 4–6% of patients, Grade II in 0–2%, and secondary infravesical obstruction in 5–10%. Severe incontinence (Grade III) and urethra-rectal fistulae are rare (<1%). Urinary tract infections are common (2–48%) but the incidence has greatly decreased with the introduction of TURP. Erectile dysfunction occurs at rates of 32–61%. Preservation of erectile function is directly dependent on the position of the primary lesion in relation to the neurovascular bundle. An approach to greater preserve potency involves leaving a 5-mm lateral margin on the contralateral side in men with positive biopsy results confined to one side of the prostate. Although sparing the contralateral side for neurovascular preservation can improve potency. This approach also results in a higher rate of re-treatment [4,44, 60–62]. Morbidity with HIFU is summarized in table 4.

Table 4. Summary of morbidity results following high-intensity focused ultrasound

Study (year) [Ref.]	Number	INC (%)	ED (%)	FIS (%)	S&S (%)	PR (%)	UTI (%)	CA (days)	Pain (%)
Blana et al. (2009) [45]	146	5.8	57.2	0.7	11.7	NR	4.1	SP:12.7	1.4
Thüroff et al. (2000) [61]	402	GI 10.6 GII 2.5 GIII 1.5	13	1.2	3.6	8.6	13.8	F:5 SP:34	NR
Gelet et al. (2003) [40]	102	GI 8.8 GII 9.8 GIII 3.9	61	1	17	5	NR	9.1	2
Chaussy et al. (2003) no TURP [2]	96	GI 9.1 GII 4.6 GIII 1.7	40	NR	27.1	NR	47.9	SP:45.1	NR
Chaussy et al. (2003) TURP [2]	175	GI 4.6 GII 2.3	31.8	NR	8	NR	11.4	SP:13.7	NR
Ficarra et al. (2006) [33]	30	7	NR	0	10	13	16	SP:12	NR
Lee et al. (2006) [84]	58	GI 16	NR	0	NR	3.4	NR	SP:15	NR
Poissonnier et al. (2007) [44]	227	GI 9.0 GII 3.0 GIII 1.0	39	0	12	9	2	7	3
Blana et al. (2008) Multi [5]	140	GI 5.0 GII 0.7	43.2	0	13.6		7.1	NR	5.7
Blana et al. (2008) Single	163	GI 6.1 GII 1,8	44.7	0	24.5		7.8	NR	3.7

To reduce the time of urinary diversion and postoperative morbidity (sludging, obstruction, infection), studies were undertaken to observe the effects of combining HIFU with TURP. In 30 patients with localized prostate cancer a one-stage (in the same anesthesia) combination therapy with TURP and HIFU was performed. At 6-month follow-up, the mean PIPSS (Post-treatment International Prostate Symptom Score) was 6.7 compared with a pre-treatment score of 7.5 [36]. In a study combining TURP and HIFU 96 patients were treated with HIFU monotherapy and 175 with combination therapy. The monotherapy group

required a suprapubic catheter for 40 days compared to 7 days in the combination group [2].

Chaussy and Thuroff compared the outcomes of a series of 175 patients treated with HIFU combined with TURP with those of 96 patients previously treated with HIFU alone [2]. No significant differences were found between the two treatment groups in PSA nadir or positive biopsy rate, consistent with subsequent studies finding comparable efficacy between HIFU plus TURP and HIFU alone [36,43,44]. However, the lower re-treatment rate in the HIFU/TURP group

at 4% compared with 25% in the HIFU alone group suggests a benefit of TURP prior to HIFU through the removal of calcifications of the transitional zone that would prevent optimal HIFU treatment. Also found was that the rate of urinary tract infections was significantly reduced in patients undergoing the combined TURP/HIFU procedure compared with HIFU alone (11.4% vs. 47.9%, $p \leq 0.001$). [Table 4]

Prediction of HIFU treatment outcome

The prediction of treatment outcome in patients receiving radical prostatectomy is based on the pathological features of the removed prostate gland such as tumor classification, nodal and margin status, and prostatectomy Gleason score. The absence of histological specimens following HIFU necessitates the use of surrogate parameters for treatment outcome. The pretreatment characteristics of disease stage, PSA level and GS at biopsy have been used prognostically in HIFU-treated patients. The results of a series published in 2001 involved 102 patients with T1–T2 disease. At a mean follow-up of 19 months, overall disease-free survival was 66% [42]. Differences in treatment outcome were observed between initial PSA < 10 ng/ml (73% vs. 50%; $p = 0.02$); Gleason score < 6 (81% vs. 46%; $p < 0.001$); and pretreatment sextant biopsy revealing one to four positive samples (68% vs. 40%; $p = 0.01$). Poissonier et al. studied the outcomes of 227 patients, and reported an actuarial 5-year DFSR of 66% [44]. DFSR varied when patients were stratified according to pre-treatment PSA level: The DFSR was 90% with PSA < 4 ng/ml versus 57% and 61% with pretreatment PSA of

4.1–10 ng/ml and 10.1–15 ng/ml, respectively.

Prostate-specific antigen nadir has been evaluated as a predictor of clinical failure following HIFU. In a 6-month study involving 115 patients, failure rates following HIFU were 11% (four out of 36) in patients with a PSA nadir of 0.0–0.2 ng/ml, compared with 46% (17 out of 37) in patients with a PSA nadir of 0.21–1 ng/ml, and 48% (20 out of 42) in patients with a PSA nadir > 1.0 ng/ml. In addition, PSA nadir was strongly associated with both preoperative PSA level and residual prostate volume. The predictive utility of PSA nadir in patients with longer follow-up was reported by Ganzer et al. [47]. Post-HIFU PSA nadir was shown to be significantly associated with treatment failure and DFSR; failure rates during follow-up were 4.5%, 30.4% and 100% for patients with PSA nadirs of ≤ 0.2 ng/ml, 0.21 to 1 ng/ml, and ≥ 1 ng/ml, respectively ($p \leq 0.001$). The actuarial DFSRs at 5 years were 95%, 55% and 0%, respectively, for the three PSA nadir groups ($p \leq 0.001$). These findings suggest that HIFU outcome is improved if a PSA nadir of less than 0.2 ng/ml is achieved.

Extended Indications

In contrast to most published trials of HIFU therapy that report the outcomes in patients with Stage T1-T2 disease or radiation failure, the results of a trial that enrolled 113 patients with Stage T3-T4 disease followed for a median of 4.6 years was presented [64]. The median PSA velocity of this cohort was 0.19 ng/mL/y and the cancer-specific survival was 96.4%. Another study reported the outcomes of 55 men with PSA progression and local biopsy-proven tumor recurrence during definitive

hormonal ablation therapy who received HIFU for hormonal resistant prostate cancer [65]. With a mean follow-up of 21 months, the prostate cancer-specific survival was 87.3%. The results of both studies are impressive and encouraging because this group of patients has a very poor prognosis and a short median survival.

Preliminary results of palliative treatment with HIFU in patients with advanced prostate cancer showed promising findings based on reductions in local morbidity such as rectal compression, infravesical obstruction, hydronephrosis, hematuria, and pelvic pain-syndromes. Unpublished data from several large patient groups ($n > 70$) with Stage T3 and CRPCa with follow-up of 10 years have shown a post-HIFU PSA velocity of 0.19 ng/ml/ year in T3 disease without additional hormone ablation. Local tumor ablation with HIFU has also resulted in a PSA reduction of 80% in CRPCa cases. There was also evidence of a synergistic effect with hormone ablative therapies that was reflected in the delay of onset of hormone resistance [66,10].

Salvage therapy

HIFU can be used as salvage therapy for locally recurrent disease following almost every curative prostate cancer modality, including external radiation, low-dose rate and high-dose rate brachytherapy cryoablation, primary HIFU, biochemically progressing PSA, and after combined pretreatment including radical prostatectomy. One of the factors accounting for the attractiveness of salvage HIFU is related to the very limited treatment options for men with recurrent disease following

curative therapy. According to CaPSURE data [37], 63% of the patients treated with XRT experience disease recurrence. Androgen deprivation therapy was used as salvage therapy in 93.5% of cases, and definitive local therapy in only 3.9% (salvage radical prostatectomy 0.9%, and cryoablation 3.0%). The appeal of salvage radical prostatectomy and cryoablation following local radiation failure is more theoretical in nature; in practice, their use represents a complex procedure associated with very high morbidity rates and procedural costs [9].

Radiotherapy failure

Murat et al. [67] reported the outcomes of 167 men who underwent salvage HIFU for locally radiorecurrent prostate cancer. The results indicate a 73% negative biopsy rate and a 5-year overall survival rate of 84%. Biochemical disease-free survival rates were not reported. No rectal complications were observed, but the urinary incontinence rate was 49.5%, similar to rates reported in salvage radical prostatectomy series. Berge et al. [68] reported the early results of a prospective study of salvage HIFU, and observed a biochemical failure rate of 39.1%. Significantly, the urinary incontinence rate was much lower in their cohort than in the Murat et al. study population, with 17.3% developing either grade II or grade III incontinence. One patient developed a rectourethral fistula.

Gelet et al. also reported the results of salvage HIFU in locally recurrent prostate cancer after external-beam radiotherapy [31]. Among the 71 patients, the mean time of recurrence after external beam radiotherapy was 38.5 months (range 6–120) and the mean

PSA prior to HIFU was 7.7 ng/ml (range 0.5–54 ng/ml). With a mean follow-up of 14.8 months (range 6–86), 80% of patients produced negative biopsies, corresponding to a 30-month actuarial negative biopsy rate of 73%. The actuarial disease-free rate, based on biopsy and PSA response, was 38% at 30 months.

Salvage HIFU represents a viable treatment option for men experiencing recurrence after radiation therapy. Although the tissue alteration from radiation therapy results in a higher postoperative morbidity rate than is seen in primary HIFU therapy alone [9], this does not alter the favorable risk-benefit ratio with the use of salvage HIFU treatment relative to the other available options [67].

Limited experience exists with salvage HIFU following brachytherapy, but it appears that this approach is not associated with a significant increase in complications compared to primary HIFU. It is absolutely necessary to

monitor the position of the seeds precisely with MRI before HIFU. There should be no seeds outside the prostate capsule, and especially between rectum and prostate as seeds in these regions would interfere with the direct entry path of the ultrasound [1].

Radical prostatectomy failure

Therapeutic options for local recurrence following radical prostatectomy are limited. HIFU offers a treatment option when local recurrence can be identified through transrectal ultrasound and verified with biopsy. After a small number of patients with post-prostatectomy failure were treated with HIFU, the treated areas showed negative biopsies in 77 % of cases. The PSA nadir averaged 0.2 ng/ml and 66 % of patients achieved a PSA Nadir <0.5 ng/ml. During follow-up of 5 years, 91% of the patients showed no biochemical progression [66,69].

[Figure 6] shows the PSA course of a patient who underwent radical prostatectomy and subsequent HIFU after 6 years.

Figure 6: Intraoperative, 3 dimensional, real time, transrectal ultrasound for visual treatment planning and control on control screen

Prostate cancer management evolution

1990 Patient lived 7 years with Prostate Cancer

Treatment strategy:

Efficacy at all price

- Single treatment approach
- Aggressive Radical Surgery
- Radical Radiotherapy



2015 Patient lives 15 years with Prostate Cancer

Treatment strategy:

disease control with QoL preservation

- Non invasive techniques
- Multi-treatment approach
- **Targeted Tissue Ablation**

Salvage radical prostatectomy following HIFU failure

Radical prostatectomy was performed in our institution in 7 patients experiencing failure following treatment with HIFU between 1996 and 2000. Prior treatment with HIFU created severe fibrotic adhesions between the rectum and Denovillier's fascia, and although this made salvage radical prostatectomy more technically demanding, it did not result in higher morbidity compared to a standard prostatectomy. The authors attribute these cases of HIFU failure to the incomplete treatment of larger sized prostate glands before the routine use of TURP [1].

Sonablate HIFU for PCa salvage therapy

All patients with a mean age of 65 had been diagnosed with an organ confined and histologically confirmed PCa following EBRT. Preoperative PSA level was 7.73 ng/mL. Patient follow-up was 7.4 (3–24) months. Half of the patients had a PSA level of <0.2 ng/mL at last follow-up. Three patients had metastatic disease whilst another two had only local, histologically confirmed, failure. Another four patients showed evidence of biochemical failure only. Overall, 71% had no evidence of a disease following salvage HIFU.

Side-effects included stricture or intervention for necrotic tissue in 11 of the 31 patients (36%), urinary tract infection or dysuria syndrome in eight (26%), and urinary incontinence in two (7%) patients. Recto-urethral fistula occurred in two patients.

The authors conclude that salvage HIFU is a minimally invasive procedure that can achieve low PSA nadirs and better cancer control in the short term, with comparable morbidity to other forms of salvage treatment. [70]

Focal and partial HIFU therapy

Over the past 25 years, the average life expectancy of men has increased almost 4 years while the average age of prostate cancer diagnosis has decreased 10 years [63,64]. Prostate cancer is also detected at a much earlier stage than two decades ago, with the majority of patient candidates for curative whole-prostate therapy. A sizable number of patients with small-volume monofocal tumor are being over-treated with whole-gland approaches that surgically remove or irradiate the entire prostate, and a great need exists for a focal approach to the treatment of small-volume single-lobe prostatic tumor.

The goal of focused HIFU therapy is to provide a partial treatment that is limited to the tumor and a safety margin in patients with noninvasive, monofocal, localized prostate cancer. Such an approach would preserve normal genitourinary function while treating the malignancy with sufficient efficacy [65,66]. Two focused treatment approaches with HIFU are currently being evaluated, a precise focal therapy that treats a maximum 30% of prostate volume without TURP, and a potency-

preserving partial therapy that excludes the contralateral lobe/capsule and neurovascular bundle by sparing 5 mm of tissue on the contralateral lobe and treating up to 90% of the prostate [21].

A critical issue in focused prostate cancer therapies concerns appropriate patient selection by eliminating those with bilateral multifocal tumor. Effective tumor visualization and mapping is essential in achieving this objective. Transperineal 3D mapping biopsies are more accurate than transrectal ultrasound-guided biopsies in excluding patients with clinically significant disease outside the areas to be ablated, and 3D biopsy has been found to increase Gleason scale gradings relative to conventional biopsy [67].

Tumor localization within the prostate of the so-called “index lesion” on which to focus therapy, and post-therapy monitoring is another important concern. The variable sensitivity of MRI [68,69] has prompted the investigation of other functional imaging techniques. Results suggest that vascular information from dynamic contrast-enhanced MRI or diffusion-weighted MRI combined with metabolic data from magnetic resonance spectroscopic imaging may greatly improve the accuracy in defining and staging prostate cancer especially in the ventral part of the prostate. [71,72]. There are also issues related to how best to monitor patients following treatment [21]. Despite these issues, the results of focused HIFU therapy are highly anticipated.

Immunologic response after HIFU therapy

Progress has been made in developing an effective immune strategy for treating prostate cancer. A number of

immunotherapy regimens are being studied including immunomodulatory cytokines/effectors, peptide and cellular immunization, viral vaccines, dendritic cell vaccines, and antibody therapies. Immunomodulatory agents, such as granulocyte-macrophage colony-stimulating factor (GM-CSF), Flt3 ligand, and IL-2, have been used to stimulate the immune system to generate an antitumor response against prostate cancer. However, the encouraging early preclinical results have not been extended into the clinical setting.

Several recent studies have examined the potential of HIFU to initiate an immune response. Wu et al. studied the effect of HIFU on systemic antitumor immunity, particularly T lymphocyte-mediated immunity in cancer patients [80]. HIFU was used to treat 16 patients with solid malignancies, including osteosarcoma, hepatocellular carcinoma and renal cell carcinoma. HIFU led to a significant increase in the population of CD4+ lymphocytes and the ratio of CD4+/CD8+ in circulation. The authors concluded that HIFU could enhance a systemic anti-tumor cellular immunity in addition to local tumor destruction in patients with solid malignancies.

The same research group investigated whether tumor antigens expressed on breast cancer cells could be preserved after HIFU treatment [81]. Primary lesions in 23 patients with biopsy-proven breast cancer were treated with HIFU, then submitted to modified radical mastectomy. Breast cancer specimens were then stained for a variety of cellular molecules, including tumor antigens and heat-shock protein 70 (HSP-70). A number of tumor antigens were identified that could provide a potential

antigen source to stimulate antitumor immune response.

It has been suggested that endogenous signals from HIFU-damaged tumor cells may trigger the activation of dendritic cells, playing a critical role in a HIFU-elicited antitumor immune response. A mouse model bearing MC-38 colon adenocarcinoma tumors was treated with thermal and mechanical HIFU exposure settings. Results showed that HIFU elicited a systemic anti-tumor immune response that was related closely to dendritic cell activation, and that dendritic cell activation was more pronounced when tumor cells were mechanically lysed by HIFU. [82,83].

Conclusion

Prostate cancer is now diagnosed at an earlier disease stage in younger patients with a longer life expectancy than it was 30 years ago before widespread PSA screening. As a result, the window for curative therapy has been extended, and with patients living longer after definitive therapy, a greater emphasis is now placed on treatment-related morbidity and its impact on patient quality of life. **[Figure 6]**

Local recurrence occurs in 10–50% of patients regardless of curative approach, and the treatment of prostate cancer has evolved from a singular treatment to a multimodal, sequential approach that greatly accommodates the use of minimally invasive therapies such as HIFU. Decreasing resources for medical care are adding to the urgency for the development and clinical use of cost-effective non-invasive therapies.

Since 2000, standardized PCa therapy with CE market Ablatherm® has progressed from an experimental therapy to a therapy under long-term investigation for primary treatment of local prostate cancer and salvage therapy after radiation failure. Preliminary data suggest that HIFU may also be effective in the treatment of focal and incidental prostate cancer, as adjuvant therapy in T3/T4 disease, and in non-metastatic castration resistant prostate cancer. This range of indications across the spectrum of prostate cancer appears to be a unique attribute of HIFU [19,31]. Additionally, HIFU can be repeated in cases of local recurrence, which is not an option with other treatment modalities for localized prostate cancer such as cryosurgery and brachytherapy.

The efficacy in cancer control of HIFU and other focal therapies will depend less on the development of therapeutic tools than on diagnostic technologies that can more accurately image and localize small but aggressive tumor lesions and multiple foci. When this goal is reached, HIFU will be the ideal therapeutic tool for focal prostate cancer treatment. To achieve this goal, several advancements in imaging technologies are being investigated for use with HIFU, including MRI, ultrasound and picture fusion of TRUS, mp MRT and fusion biopsies.

With over 20 years of clinical use in over 40,000 patients, prostate cancer is the leading application for HIFU, followed by the treatment of uterus

fibromas and myomas. Other applications for HIFU being investigated include breast cancer, brain cancer, thyroid cancer, thrombolysis and the use of HIFU as a drug delivery device.. The clinical future of HIFU will focus primarily on the treatment of soft tissue pathologies directly below the body surface with targeting volumes less than 20 cc (prostate, breast and thyroid) due to the limited penetration depth of HIFU. Drug delivery involving the accumulation of drugs in defined organ regions or genetic manipulation is anticipated to be a promising area of future HIFU research, and HIFU-provoked induction of immune response as a supportive therapy is under investigation [1].

The use of HIFU should not be viewed as a substitute or replacement for classical therapy, but instead as a therapeutic first choice in monofocal well-differentiated disease. The initial use of HIFU can help postpone the need for invasive therapies associated with greater morbidity such as surgery or radiation, allowing the patient a longer period without the risk of living with treatment-related genitourinary side effects [84]. Transrectal HIFU should be given serious consideration as a curative therapy in localized disease as well as a palliative adjuvant therapy in all other tumor stages. Ongoing improvements in imaging technologies are expected to further enhance the efficacy of HIFU. [85]

References

1. Chaussy CG. Ultrasonidos De Alta Intensidad Focalizados (HIFU) Para El Tratamiento Local Del Cancer De Prostata: Papel Actual. Arch Esp Urol,2011,64(6): 493-506.
2. Chaussy CH, Thuroff S. The status of high-intensity focused ultrasound in the treatment of localized prostate cancer and the impact of a combined resection. Curr Urol Rep,2003,4:248–252.
3. Chaussy C, Thuroff S. Results and side effects of high intensity focused ultrasound in localized prostate cancer. J Endourol,2001,15:437–440, 447–448.
4. Chaussy Ch, Thuroff S. The use of high-intensity focused ultrasound in prostate cancer. In: O Ukimura and I.S.Gill. Contemporary Interventional Ultrasonography in Urology. London: Springer, 2009:63–74.
5. Blana A, Murat FJ, Walter B, Thuroff S, Wieland WF, Chaussy C, Gelet A. First Analysis of the Long-Term Results with Transrectal HIFU in Patients with Localised Prostate Cancer. Eur Urol,2008,53(6):1194-1201.
6. Chaussy CG, Thüroff SF. Robotic high-intensity focused ultrasound for prostate cancer: what have we learned in 15 years of clinical use? Curr Urol Rep,2011,12(3):180-7.
7. Lynn JG and Putman TJ. Histological and cerebral lesions produced by focused ultrasound. Am J Pathol,1944,20:637-649.
8. ter Haar G. Intervention and therapy. Ultrasound Med Biol,2000,23(1 Suppl): S51-S54.
9. Poissonnier L, Gelet A, Chapelon JY, Bouvier R, Rouviere O, Pangaud C, Lyonnet D, Dubernard JM. Results of transrectal focused ultrasound for the treatment of localized prostate cancer (120 patients with PSA<or +10 ng/ml). Prog Urol,2003,13: 60-72.
10. Chaussy C, Thüroff S. High-intensity focused ultrasound in the management of prostate cancer. Expert Rev Med Devices,2010,7(2):209-17.
11. Chapelon JY, Margonari J, Theillère Y, Gorry F, Vernier F, Blanc E, Gelet A. Effects of high-energy focused ultrasound on kidney tissue in the rat and the dog. Eur Urol,1992,22:147-152.
12. Uchida T, Sanghvi NT, Gardner TA, Koch MO, Ishii D, Minei S, Satoh T, Hyodo T, Irie A, Baba S. Transrectal high-intensity focused ultrasound for treatment of patients with stage T1b-2n0m0 localized prostate cancer: a preliminary report. Urology,2002,59(3):394-8; discussion 398-9.
13. Chapelon JY, Cathignol D, Cain C, Ebbini E, Kluiwstra JU, Sapozhnikov OA, Fleury G, Berriet R, Chupin L, Guey JL. New piezoelectric transducers for therapeutic ultrasound. Ultrasound Med Biol,2000,26:153-159.
14. Curiel L, Chavrier F, Souchon R, Birer A, Chapelon JY. 1.5-D high intensity focused ultrasound array for non-invasive prostate cancer surgery. IEEE Trans Ultrason Ferroelectr Freq Control,2002,49(2):231-42.
15. Tan JS, Frizzell LA, Sanghvi NT, Seip R, Wu JS, Kouzmanoff, JT. Design of focused ultrasound phased arrays for

prostate treatment, *Ultrasonics Symp Proc IEEE*,2000,2:1247–1251.

16. Oosterhof GO, Cornel EB, Smits GA, Debruyne FM, Schalken JA. Influence of high intensity focused ultrasound on the development of metastases. *Eur Urol*,1997,32:91–95.

17. Foster RS, Bihrl R, Sanghvi N, Fry F, Kopecky K, Regan J, Eble J, Hennige C, Hennige LV, Donohue JP. Production of prostatic lesions in canines using transrectally administered high intensity focused ultrasound. *Eur Urol*,1993,23 330–336.

18. Gelet A, Chapelon JY, Margonari J, Theillere Y, Gorry F, Cathignol D, Blanc E. Prostatic tissue destruction by high-intensity focused ultrasound: experimentation on canine prostate. *J Endourol*,1993,7(3):249-53.

19. Chaussy C, Thüroff S, Rebillard X, Gelet A. Technology insight: High-intensity focused ultrasound for urologic cancers. *Nat Clin Pract Urol*. 2005 Apr;2(4):191-8.

20. Rebillard X, Davin JL, Soulié M; Comité de Cancérologie de l'Association Française d'Urologie. Treatment by HIFU of prostate cancer: survey of literature and treatment indications. *Prog Urol*,2003,13:1428–1456.

21. Chaussy CG, Thüroff S. Robot-assisted high-intensity focused ultrasound in focal therapy of prostate cancer. *J Endourol*,2010,24(5):843-847.

22. Ahmed HU, Dickinson L, Charman S, Weir S, McCartan N, Hindley RG, Freeman A, Kirkham AP, Sahu M, Scott R, Allen C, Van der Meulen J, Emberton

M. Focal Ablation Targeted to the Index Lesion in Multifocal Localised Prostate Cancer: A Prospective Development Study. *Eur Urol*. 2015, Dec; 68(6): 927-36

23. Beerlage HP, van Leenders GJ, Oosterhof GO, Witjes JA, Ruijter ET, van de Kaa CA, Debruyne FM, de la Rosette JJ. High-intensity focused ultrasound (HIFU) followed after one to two weeks by radical retropubic prostatectomy: results of a prospective study. *Prostate*,1999,1;39(1):41-46.

24. Rouviere O, Lyonnet D, Raudrant A, Colin-Pangaud C, Chapelon JY, Bouvier R, Dubernard JM, Gelet A. MRI appearance of prostate following transrectal HIFU ablation of localized cancer. *Eur Urol*,2001,40:265–274.

25. Hynynen K, Freund WR, Cline HE, Chung AH, Watkins RD, Vetro JP, Jolesz FA. A clinical, noninvasive, MR imaging-monitored ultrasound surgery method. *Radiographics*,1996,16:185–195.

26. Damianou C, Pavlou M, Velez O, Kyriakou K, Trimikliniotis M. High intensity focused ultrasound ablation of kidney guided by MRI. *Ultrasound Med Biol*,2004,30 397–404.

27. Wu T, Felmlee JP, Greenleaf JF, Riederer SJ, Ehman RL. Assessment of thermal tissue ablation with MR elastography. *Magn Reson Med*,2001,45:80–87.

28. Vaezy S, Shi X, Martin RW, Chi E, Nelson PI, Bailey MR, Crum LA. Real-time visualization of high-intensity focused ultrasound treatment using

ultrasound imaging. *Ultrasound Med Bio*,2001,27:33–42.

29. Sedelaar JP, Aarnink RG, van Leenders GJ, Beerlage HP, Debruyne FM, Wijkstra H, de La Rosette JJ. The application of three-dimensional contrast-enhanced ultrasound to measure volume of affected tissue after HIFU treatment for localized prostate cancer. *Eur Urol*,2000,37: 559-568.

30. Lu J, Ying H, Sun Z, Motamedi M, Bell B, Sheppard LC. In vitro measurement of speed of sound during coagulate tissue heating. *Ultrasonics Symp Proc IEEE*,1996, 2:1299–1302.

31. Gelet A, Chapelon JY, Poissonnier L, Bouvier R, Rouvière O, Curiel L, Janier M, Vallancien G. Local recurrence of prostate cancer after external beam radiotherapy: early experience of salvage therapy using high-intensity focused ultrasonography. *Urology*, 2004,63(4):625-629.

32. Chaussy C, Thueroff S. Complete remission in metastatic prostate cancer after combined local and systemic therapy. *Urology*,2006,68:197–198.

33. Ficarra V, Antoniolli SZ, Novara G, Parisi A, Fracalanza S, Martignoni G, Artibani W. Short-term outcome after high-intensity focused ultrasound in the treatment of patients with high-risk prostate cancer. *BJU Int*,2006,98(6):1193-1198.

34. ASTRO. Consensus Statement. Guidelines for PDSA following radiation therapy. *Int J Radiat Oncol Biol Phys*,1997,37,1035–1041.

35. Chaussy CG, Thueroff S.

Transrectal high-intensity focused ultrasound for local treatment of Prostate Cancer. *Urologe A*,2009;48(7):710–718.

36. Vallancien G, Prapotnich D, Cathelineau X, Baumert H, Rozet F. Transrectal focused ultrasound combined with transurethral resection of the prostate for the treatment of localized prostate cancer: feasibility study. *J Urol*,2004,171(6 Pt 1):2265-2267.

37. Agarwal PK, Sadetsky N, Konety BR, Resnick MI, Carroll PR; Cancer of the Prostate Strategic Urological Research Endeavor (CaPSURE). Treatment failure after primary and salvage therapy for prostate cancer: likelihood, patterns of care, and outcomes. *Cancer*,2008,112(2):307-314.

38. Gelet A, Chapelon JY, Bouvier R, Souchon R, Pangaud C, Abdelrahim AF, Cathignol D, Dubernard JM. Treatment of prostate cancer with transrectal focused ultrasound: early clinical experience. *Eur Urol*,1996,29(2):174-183.

39. Gelet A, Chapelon JY, Bouvier R, Pangaud C, Lasne Y. Local control of prostate cancer by transrectal high intensity focused ultrasound therapy: preliminary results. *J Urol*,1999,161(1):156-162.

40. Gelet A, Chapelon JY, Bouvier R, Rouvière O, Lasne Y, Lyonnet D, Dubernard JM. Transrectal high-intensity focused ultrasound: minimally invasive therapy of localized prostate cancer. *J Endourol*, 2000,14(6):519-528.

41. Richaud P, Moreau JL, Beuzeboc P, Rébillard X, Villers A, Peyromaure M, Cornud F, Soulié M, Davin JL. Follow-

up of prostate cancer. Guidelines of the French Urological Association Oncology Committee. *Prog Urol*,2005,15,586–592.

42. Gelet A, Chapelon JY, Bouvier R, Rouvière O, Lyonnet D, Dubernard JM. Transrectal high intensity focused ultrasound for the treatment of localized prostate cancer: factors influencing the outcome. *Eur Urol*,2001,40(2):124-129.

43. Blana A, Rogenhofer S, Ganzer R, Lunz JC, Schostak M, Wieland WF, Walter B. Eight years' experience with high-intensity focused ultrasonography for treatment of localized prostate cancer. *Urology*,2008,72(6):1329–1333.

44. Poissonnier L, Chapelon JY, Rouvière O, Curiel L, Bouvier R, Martin X, Dubernard JM, Gelet A. Control of prostate cancer by transrectal HIFU in 227 patients. *Eur Urol*,2007,51:381–387.

45. Blana A, Brown SCW, Chaussy C, Conti GN, Eastham JA, Ganzer R, Murat FJ, Rebillard X, Rewcastle JC, Robertson CN, Thueroff S, Ward JF, Gelet A. Primary prostate HIFU without pretreatment hormone therapy: biochemical survival of 763 patients tracked with the @-Registry. *Eur Urol*,2009,8(4):333(Abstract 850).

46. D'Amico AV, Moul J, Carroll PR, Sun L, Lubeck D, Chen MH. Cancer-specific mortality after surgery or radiation for patients with clinically localized prostate cancer managed during the prostate specific antigen era. *J Clin Oncol*,2003,21(11):2163–2172.

47. Ganzer R, Rogenhofer S, Walter B, Lunz JC, Schostak M, Wieland WF, Blana A. PSA nadir is a significant predictor of treatment failure after high-

intensity focused ultrasound (HIFU) treatment of localized prostate cancer. *Eur Urol*,2008,53:547-553.

48. Thüroff S, Chaussy C, Vallancien G, Wieland W, Kiel HJ, Le Duc A, Desgrandchamps F, De La Rosette JJ, Gelet A. High-intensity focused ultrasound and localized prostate cancer: efficacy results from the European multicentric study. *J Endourol*,2003,17(8):673-677.

49. Kupelian PA, Elshaikh M, Reddy CA, Zippe C, Klein EA.. Comparison of the efficacy of local therapies for localized prostate cancer in the prostate-specific antigen era: a large single institution experience with radical prostatectomy and external-beam radiotherapy. *J Clin Oncol*,2002,20:3376–3385.

50. Kuban DA, Elshaikh M, Reddy CA, Zippe C, Klein EA. Long-term multi-institutional analysis of stage T1-T2 prostate cancer treated with radiotherapy in the PSA era. *Int J Radiat Oncol Biol Phys*,2003,57 915–928.

51. Potters L, Klein EA, Kattan MW, Reddy CA, Ciezki JP, Reuther AM, Kupelian PA. Monotherapy for stage T1-T2 prostate cancer: radical prostatectomy, external beam radiotherapy, or permanent seed implantation. *Radiother Oncol*,2004,71:29–33.

52. Crouzet S, Rebillard X, Chevallier D, Rischmann P, Pasticier G, Garcia G, Rouviere O, Chapelon JY, Gelet A. Multicentric oncologic outcomes of high-intensity focused ultrasound for localized prostate cancer in 803 patients. *Eur Uro*, 2010,58(4):559-566.

53. Ahmed HU, Zacharakis E, Dudderidge T et al: High-intensity focused ultrasound in the treatment of primary prostate cancer: the first UK series. *Br J Cancer*, 2009; 101: 19–26
54. Mearini L, D’Urso L, Collura D et al: Visually directed transrectal high intensity focused ultrasound for the treatment of prostate cancer: a preliminary report on the Italian experience. *J Urol*, 2009;181: 105-11
55. Muto S, Yoshii T, Saito K et al: Focal therapy with high-intensity focused ultrasound in the treatment of localized prostate cancer. *Jpn J Clin Oncol*, 2008; 38: 192–99
56. Uchida T, Baba S, Irie A et al: Transrectal high-intensity focused ultrasound in the treatment of localized prostate cancer: a multicenter study. *Hinyokika Kyo*, 2005; 51: 651–58
57. Uchida T, Ohkusa H, Nagata Y et al: Treatment of localized prostate cancer using high-intensity focused ultrasound. *BJU Int*, 2006; 97: 56–61
58. Uchida T, Shoji S, Nakano M et al: Transrectal high-intensity focused ultrasound for the treatment of localized prostate cancer: eight-year experience. *Int J Urol*, 2009; 16: 881–86
59. Barkin J: High intensity focused Ultrasound (HIFU). *Can J Urol*, 2011; 18: 5634–43
60. Chaussy CG, Thüroff S .High-intensity focused ultrasound in localized prostate cancer. *J Endourol*,2000,14: 293–299.
61. Thüroff S, Chaussy CG. High-intensity focused ultrasound: complications and adverse events. *Mol Urol*,2000,4:183-187.
62. Thüroff S. High-Intensity focused ultrasound for prostate cancer. In: Li-Ming Su and Stephen C.Young (eds). *Early Diagnosis and Treatment of Cancer: Prostate Cancer*:Saunders Elsevier,2008 Chapter 9:177-192.
63. Thüroff S, Chaussy C, Gelet A. Focused ultrasound (HIFU) in the treatment of prostate cancer. energy/efficacy correlation. *WCE Congress*, 2001. *J Endourol*,2001,15(1 Suppl):S32 (Abstract A3-P10).
64. Chaussy CG, Thueroff SF. HIFU treatment of locally advanced prostate cancer. *J Endourol*,2010,24(1 Suppl):PS12–2.
65. Chaussy C, Thuroff S, Nanieva R. Hormone resistant prostate cancer treated by robotic high intensive ultrasound. *J Urol*,2010,(183 Suppl):e262.
66. Chaussy C, Thüroff S, Bergsdorf T. Local recurrence of prostate cancer after curative therapy. HIFU (Ablatherm) as a treatment option. *Urologe A*,2006,45(10):1271-1275.
67. Murat FJ, Poissonnier L, Rabilloud M, Belot A, Bouvier R, Rouviere O, Chapelon JY, Gelet A. Mid-term results demonstrate salvage high-intensity focused ultrasound (HIFU) as an effective and acceptably morbid salvage treatment option for locally

radiorecurrent prostate cancer. *Eur Urol*,2009,55(3):640-647.

68. Berge V, Baco E, Karlsten SJ. A prospective study of salvage high intensity focused ultrasound for locally radiorecurrent prostate cancer: early results. *Scand J Urol Nephrol*,2010,44:223–227.

69. Hayashi M, Shinmei S, Asano K. Transrectal high-intensity focused ultrasound for treatment for patients with biochemical failure after radical prostatectomy. *Int J Urol*,2008,14:1048-1050.

70. Zacharakis E, Ahmed HU, Ishag A et al. The feasibility and safety of high intensity focused ultrasound as salvage therapy for recurrent prostate cancer following external beam radiotherapy. *BJU Int.*, 2008;102:786-92

71. van Leeuwen PJ, Connolly D, Tammela TL, Auvinen A, Kranse R, Roobol MJ, Schroder FH, Gavin A. Balancing the harms and benefits of early detection of prostate cancer. *Cancer*,2010,116:4857–4865.

72. Lee DJ, Ahmed HU, Moore CM, Emberton M, Ehdiaie B. Multiparametric magnetic resonance imaging in the management and diagnosis of prostate cancer: current applications and strategies. *Curr Urol Rep.* 2014 Mar; 15(3):390

73. Roemeling S, Roobol MJ, Kattan MW, van der Kwast TH, Steyerberg EW, Schröder FH. Nomogram use for the prediction of indolent prostate cancer: impact on screen-detected populations. *Cancer*,2007,110:2218–2221.

74. Onik G, Barzell W. Transperineal. 3D mapping biopsy of the prostate: an essential tool in selecting patients for focal prostate cancer therapy. *Urol Oncol*,2008,26(5):506–510.

75. Rouvière O, Souchon R, Salomir R, Gelet A, Chapelon JY, Lyonnet D. Transrectal high-intensity focused ultrasound ablation of prostate cancer: effective treatment requiring accurate imaging. *Eur J Radiol*,2007,63(3):317-327.

76. Kirkham AP, Emberton M, Allen C. How good is MRI at detecting and characterising cancer within the prostate? *Eur Urol*,2006,50:1163–1174.

77. Kim JK, Hong SS, Choi YJ, Park SH, Ahn H, Kim CS, Cho KS. Wash-in rate on the basis of dynamic contrast-enhanced MRI: usefulness for prostate cancer detection and localization. *J Magn Reson Imaging*,2005,22(5): 639–646.

78. Haider MA, van der Kwast TH, Tanguay J, Evans AJ, Hashmi AT, Lockwood G, Trachtenberg J. Combined T2-weighted and diffusion-weighted MRI for localization of prostate cancer. *Am J Roentgenol*,2007,189(2):323–328.

79. Uchida T, Illing RO, Cathcart PJ, Emberton M. To what extent does the prostate-specific antigen nadir predict subsequent treatment failure after transrectal high-intensity focused ultrasound therapy for presumed localized adenocarcinoma of the prostate. *BJU Int*,2006,98:537–539.

80. Wu F, Wang ZB, Lu P, Xu ZL, Chen WZ, Zhu H, Jin CB. Activated anti-

tumor immunity in cancer patients after high intensity focused ultrasound ablation. *Ultrasound Med Biol*,2004,30(9):1217–1222.

81. Wu F, Wang ZB, Cao YD, Zhou Q, Zhang Y, Xu ZL, Zhu XQ. Expression of tumor antigens and heat-shock protein 70 in breast cancer cells after high intensity focused ultrasound ablation. *Ann Surg Oncol*,2007,14(3):1237–1242.

82. Hu Z, Yang XY, Liu Y, Sankin GN, Pua EC, Morse MA, Lysterly HK, Clay TM, Zhong P. Investigation of HIFU-induced antitumor immunity in a murine tumor model. *J Transl Med*,2007,5:34.

83. Lu P, Zhu XQ, Xu ZL, Zhou Q,

Zhang J, Wu F. Increased infiltration of activated tumor infiltrating lymphocytes after high intensity focused ultrasound ablation of human breast cancer. *Surgery*,2009,145(3):286–293.

84. Lee HM, Hong JH, Choi HY. High-intensity focused ultrasound therapy for clinically localized prostate cancer. *Prostate Cancer Prostatic Dis*,2006,9(4):439-443.

85. Thüroff S, Chaussy C. *Focal Therapy of Prostate Cancer. An Emerging Strategy for Minimally Invasive, Staged Treatment.* Springer Intl. Publishing, Switzerland 2015 ISBN 978-3-319-14160-2



Original article

HIFU as salvage first-line treatment for palpable, TRUS-evidenced, biopsy-proven locally recurrent prostate cancer after radical prostatectomy: A pilot study

Anastasios D. Asimakopoulos, M.D., Roberto Miano, M.D., Guido Virgili, M.D.,
Giuseppe Vespasiani, M.D., Enrico Finazzi Agrò, M.D.*

Division of Urology, Department of Surgery, Fondazione Policlinico Tor Vergata, University of Tor Vergata, Rome, Italy

Received 4 May 2010; received in revised form 29 July 2010; accepted 19 August 2010

Abstract

Objective: To test high-intensity focused ultrasound (HIFU) as salvage first-line treatment for palpable, TRUS-evidenced, biopsy-proven locally recurrent prostate cancer (CaP) after radical prostatectomy (RP).

Materials and methods: Nineteen patients with palpable, TRUS-evidenced, biopsy-proven local recurrence of CaP after RP, unwilling to undergo salvage radiotherapy (SRT), underwent HIFU as a single-session procedure. Pre-, intra-, and postoperative data including early and late complications, and oncologic outcomes (PSA nadir, biochemical recurrence (BCR)-free survival, and need of secondary adjuvant treatment) were prospectively evaluated. Success was defined as PSA nadir ≤ 0.1 ng/ml obtained within 3 months from HIFU. In case of PSA nadir > 0.1 ng/ml or PSA increase ≥ 1 ng/ml above the PSA nadir, a biopsy of the treated lesion was performed, and if negative, maximum androgen blockade (MAB) was adopted. In case of positive biopsy, RT was performed. Failure was defined as use of secondary adjuvant treatment (MAB or RT).

Results: Median follow-up was 48 months. All cases were performed as overnight procedure. No case of urethrorectal fistula or anastomotic stricture was observed. Two cases of acute urinary retention were resolved with prolonged urethral catheterization. Four cases of stress urinary incontinence were observed; 2 (mild incontinence) were resolved after pelvic floor exercises within 6 months, while 2 cases of severe incontinence required surgical minimally invasive treatment; 17/19 patients (89.5%) were classified as success. Two patients failed to show a PSA nadir < 0.1 ng/ml. During follow-up, 8/17 patients (47%) were classified as failure, with consequent total rate of failures 10/19 (52.6%). A statistically significant difference was observed in pre-HIFU median PSA (2 vs. 5.45 ng/ml, respectively, $P = 0.013$) and Gleason score of the RP specimen ($P = 0.01$) between the success and failure group.

Conclusions: Salvage first-line HIFU for palpable, TRUS-evidenced, biopsy-proven local recurrence of CaP is a feasible, minimally invasive day-case procedure, with an acceptable morbidity profile. It seems to have a good cancer control in the short- and mid-term. Patients with lower pre-HIFU PSA level and favorable pathologic Gleason score presented better oncologic outcomes. A prospective randomized trial with an adequate recruitment and follow-up is necessary to confirm our preliminary oncologic results. © 2011 Elsevier Inc. All rights reserved.

Keywords: High-intensity focused ultrasound; Prostate; Prostate cancer; Radical prostatectomy; Local recurrence

1. Introduction

Prostate cancer (CaP) is the most commonly diagnosed malignancy and the second leading cancer-related cause of death in men in the United States [1]. Although radical prostatectomy (RP) is an effective treatment for many pa-

tients with clinically localized CaP [2], treatment fails in up to one-third of patients. Without salvage therapy, 65% of men will develop distant metastasis within 10 years of biochemical recurrence (BCR) [3].

For patients with biopsy-proven or radiographically identified local recurrence after RP and in absence of identifiable metastatic disease, salvage radiotherapy (SRT) is the standard treatment [4–7]. However, it is a time-consuming therapy (it takes several weeks to complete); moreover, the additional gastrointestinal and genitourinary toxicity could

* Corresponding author. Tel.: +39 06 20902835 or +39 340 6054387; fax: +39 06 20902975.

E-mail address: tasospao2003@yahoo.com (A.D. Asimakopoulos).

be physically challenging, especially for elderly patients with co-morbidities and lower performance status [8].

To avoid the limits of the SRT, increasing interest is being focused on the minimally invasive forms of CaP treatment. Recently, Siddiqui et al. [9] reported their experience on the use of cryotherapy for patients with local recurrence after RP, demonstrating that it could be an effective alternative to SRT.

Transrectal high-intensity focused ultrasound (HIFU) has demonstrated an effective long-term cancer control in patients with low- or intermediate-risk localized CaP [10]. Its role as a salvage treatment after RT for CaP has also been evaluated [11]. However, there is only one study (case-series, Level of evidence 4) regarding the use of salvage HIFU in the post-RP setting [8].

We designed a pilot study, with no control arm, to test HIFU as first-line salvage treatment in patients with palpable, transrectal ultrasound (TRUS)-evidenced, biopsy-proven local recurrence of CaP after RP.

2. Materials and methods

2.1. Patients' enrollment and ethics

In our center, the first-line treatment for the local recurrence of CaP after RP is the SRT. However, in the period June 2003–June 2008, 19 patients with palpable, TRUS-evidenced, biopsy-proven CaP local recurrence post-RP were unwilling to undergo SRT for several reasons: distance from the reference center of RT, long waiting list, fear/apprehension of the potential collateral effects of RT, duration of treatment. These patients were enrolled in the HIFU protocol, after obtaining institutional review board approval and written informed consent of patients. The study was conducted in accordance with the Good Clinical Practice rules and with the ethical principles contained in the Declaration of Helsinki as amended in Hong Kong.

2.2. Inclusion and exclusion criteria

Inclusion criteria for first-line salvage HIFU were: palpable, TRUS-evidenced, biopsy-proven local recurrence of CaP, independently of PSA level and pathologic Gleason score; no evidence of distant metastasis assessed by means of bone scan and total body CT scan or 18F PET/CT scan. DRE findings were considered abnormal if any mass, nodule, induration, or irregularity was noted in the prostatic fossa. A gray-scale TRUS was performed by a single operator with a linear 7.5 MHz biplane probe (Technos; Esaote SpA, Rome, Italy). The TRUS findings were considered to be suggestive of local recurrence if any suspected lesion was identified at or around the area of the anastomosis, at the bladder neck, in the retrovesical space, or if any asymmetry or obvious distortion of the urethrovesical anastomosis

was noted [12]. The size of the local recurrence was determined by its greatest diameter.

The subsequent biopsies, all performed by the same operator through the transperineal route and under TRUS guide, were positive for local recurrence of CaP. The grading of the lesion was assigned according to the Gleason system.

Exclusion criteria were: evidence of distant metastasis, not TRUS-evidenced local recurrence, adjuvant external radiation or hormonal treatment, if administered after RP but before the time of the evaluation, anal stenosis or any other condition that does not permit the introduction of the HIFU probe in the rectum.

2.3. Study end-points and methodology

Primary end-point was the evaluation of the feasibility of the procedure in terms of safety and early and late morbidity. All medical and surgical complications occurring in both in-patient and out-patient setting were recorded. They were classified as early onset (<30 days) and late onset (>30 days), and graded according to the modified Clavien classification [13].

Secondary end-point was the preliminary evaluation of the oncologic efficacy of salvage HIFU in terms of PSA nadir, biochemical disease free survival (bDFS), and need of secondary adjuvant treatment (or monotherapy or SRT).

Success was defined as PSA nadir ≤ 0.1 ng/ml, obtained within 3 months [14]. In case of PSA nadir > 0.1 ng/ml or PSA increase ≥ 1 ng/ml above the PSA nadir, a biopsy of the treated lesion was performed, and if negative, hormonal therapy [maximum androgen blockade (MAB)] was adopted. In case of positive biopsy, secondary SRT was performed. Failure was defined as use of MAB or RT after first-line HIFU.

2.4. Treatment protocol and postoperative care

All patients underwent HIFU using the "re-treatment" protocol of the Ablatherm device (EDAP TMS, Vaux-en-Velin, France). Antiplatelet agents were stopped 10 days prior to HIFU treatment. HIFU was performed under spinal anesthesia, with the exception of the cases where it was not technically feasible or it was refused by the patient. A urethral catheter was inserted in all cases before surgery, removed during the procedure to permit the treatment of periurethral tissue, and replaced at the end of the treatment.

Surgical time, intra- and postoperative complications, and hospital stay were recorded. Patients were all discharged with the Foley catheter still in place; the catheter was then electively removed on an outpatient basis.

2.5. Follow-up

Follow-up visits were scheduled every 3 months during the first year and every 6 months afterwards. They included: total serum PSA, assessment of continence status (number

Table 1
Clinical and pathologic baseline characteristics of the patient cohort

Mean age at HIFU (years)	70 (60–77, SD 4.84)
Median interval RRP to HIFU (month)	40 (8–103)
RRP pathological stage (<i>n</i>)	
T2a	6
T2b	6
T2c	5
T3a	1
T3b	1
RRP Gleason score (<i>n</i>)	
≤6	4
3+4	4
4+3	5
>7	2
Missing	4
Median PSA before HIFU (ng/ml)	3.81 (0.5–8)
Pre-HIFU continent patients (%)	16/19 (84%)
Mean lesion size (mm)	23.7 (20–40)
Biopsy Gleason score of local recurrence (<i>n</i>)	
≤6	7
3+4	3
4+3	3
>7	3
Scarcely differentiated	1
Not specified	2
Median follow-up (month)	48 (13–77)

of pads/d), and radiologic imaging at the discretion of the treating physician. Erectile function was not evaluated.

2.6. Statistical analysis

Baseline characteristics and follow-up data of success and failure patients were compared by means of *t*-test (parametric) or Fisher's exact test (nonparametric data). *P* values <0.05 were considered significant. All statistics were performed with Statistica Base (software for Windows, StatSoft Italia srl, Vigonza, Padova, Italy).

3. Results

The clinical and pathologic baseline characteristics of the patient cohort are outlined in the Table 1.

The procedure was feasible in all cases and it was carried out within a mean of 32 minutes (15–43). No serious intra- or postoperative complications were observed. All patients were discharged within 24 hours with the Foley catheter still in place.

Catheter was routinely removed within 7 days and post-void residual evaluation was performed. Two cases of acute urinary retention after catheter removal required prolonged catheterization for 14 and 15 days, respectively (early complication, Grade IIIa according to the Clavien classification).

Sixteen of 19 (84%) patients achieved continence (no pad) before HIFU. Four cases of newly diagnosed stress urinary incontinence (early onset) were observed after the treatment; 2/4 patients presented a mild to moderate incontinence, resolved after pelvic-floor muscle exercises within 6 months (Grade I); 2 cases of severe incontinence required a minimally invasive day-case procedure with the placement of adjustable continence therapy (ProACT, Uromedica, Plymouth, MN) (Grade IIIb). Two opposing balloons were successfully implanted via a transperineal approach, under TRUS-guidance, paraurethraly at the level of bladder neck without complications. Three patients who were incontinent before HIFU did not report any worsening of their incontinence status. No case of urethrorectal fistula, anastomotic stricture, or persistent storage symptoms was observed.

Table 2 summarizes the early and late complications, providing a comparison with the published series of minimally invasive surgical treatment for local recurrence after RP.

Seventeen of 19 patients (89.5%) were classified as success 3 months after HIFU, showing a PSA nadir ≤0.1 ng/ml; 8/17 patients (47%) were classified as failure during follow-up (median follow-up: 48 months); 7/8 had negative biopsy of the treated lesion and showed an increase of PSA ≥1 ng/ml above PSA nadir; consequently MAB was administered; 1/8 had positive biopsy and was treated with SRT. At a median follow-up of 48 months, 9/17 (52, 9%) patients continue to be considered as "success" according to

Table 2
Complications of the published series of minimally invasive surgical treatment for local recurrence of CaP after RP

	Siddiqui et al. [9]	Murota-Kawano et al. [8]	Current study
Patients (<i>n</i>)	15	4	19
Treatment modality	Cryoablation	HIFU*	HIFU
Mean or median follow-up (months)	20	18	48
Recto-urethral fistula (<i>n</i>)	0	0	0
De novo incontinence (treatment)	2 (1 security pad 1 artificial urinary sphincter)	0	4 (2 PFME**; 2 Pro-ACT)
Worsening of pre-existing incontinence	1	0	0
Acute urinary retention	NR	0	2
Storage symptoms	1	0	0
Anastomotic stricture	NR	0	0

* 3/4 patients received first-line SRT before HIFU.

** PFME = pelvic-floor muscle exercises.

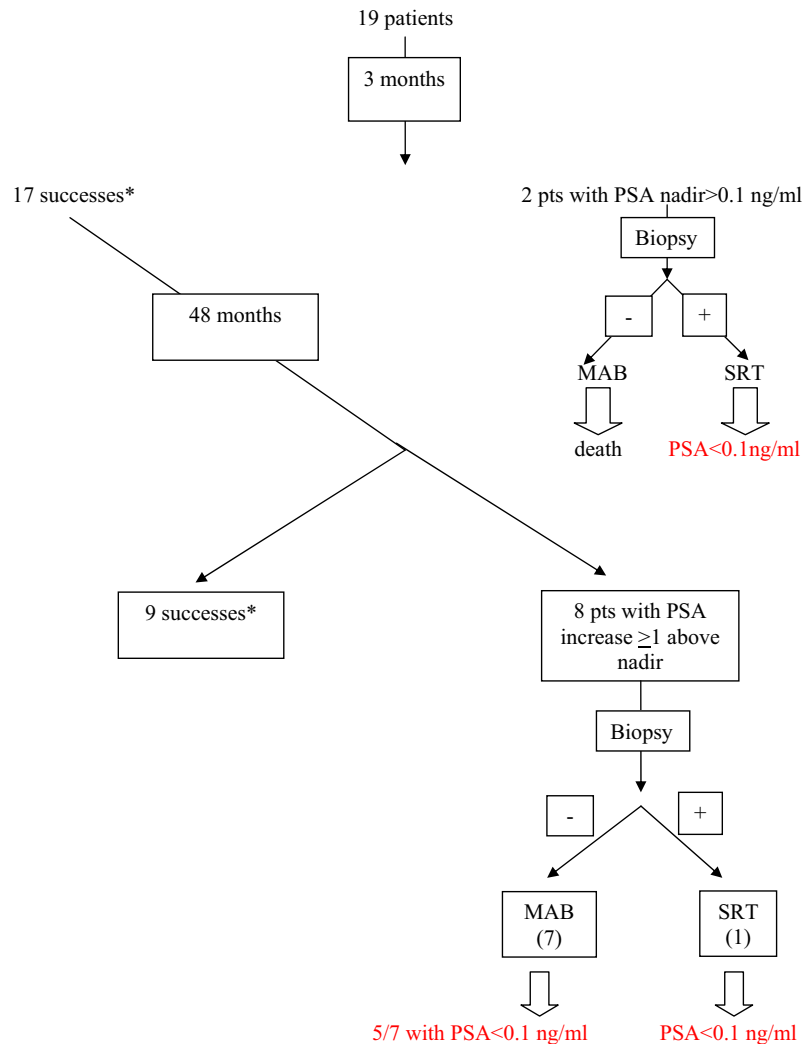


Fig. 1. Oncologic efficacy of salvage HIFU after RP palpable local failure. * PSA nadir ≤ 0.1 ng/ml. (Color version of figure is available online.)

the previous definition. Overall, the 4-year bDFS was 47.4% (9/19 patients).

Two of 19 patients failed to show a PSA nadir ≤ 0.1 ng/ml: 1 of them had positive biopsy and was treated with SRT, while the other, having negative biopsy, received MAB. The latter died during the follow-up period after development of hormone refractory CaP. Currently, 7/9 patients classified as failure present a PSA level ≤ 0.1 ng/ml, while 2/9 have a PSA > 0.1 ng/ml (1.39 and 1.74 ng/ml, respectively, after adjuvant MAB). These results are summarized in the Fig. 1.

The clinical and pathologic comparisons between the HIFU success and failure groups are outlined in Table 3. The comparison of the Gleason score was obtained after their subdivision in 2 subgroups: A ($\leq 3+4$) and B ($\geq 4+3$).

Age, median pre-RP PSA, size of lesion, local recurrence biopsy Gleason score (pre-HIFU), and mean time from RP to HIFU did not differ significantly between success and failure group. A statistically significant difference was ob-

served between the 2 groups for pre-HIFU median PSA (2 vs. 5.45 ng/ml; $P = 0.013$) and Gleason score of the RP specimen ($P = 0.01$).

4. Discussion

Primary curative procedures, such as RP and radiotherapy, are well-established therapeutic options in the management of localized CaP. Despite the improvements in both fields, there is still a significant risk of cancer recurrence after therapy and up to 27%–53% of all patients undergoing radiation therapy or RP will develop local or distant recurrences within 10 years after initial therapy, and 16%–35% of patients will receive second-line treatment within 5 years of initial therapy [15].

CaP recurrence after RP is defined as only a BCR if a detectable serum PSA value is noted in the absence of clinical evidence of local recurrence or of metastatic disease. Local recurrence has been defined to occur with ab-

Table 3
Clinical and pathologic data of HIFU success and failure groups

	Success group (n = 9)	Failure group (n = 10)	P value
Age (years)	71.1	68.7	0.3
Pre-RP PSA (ng/ml)	7.45	9.76	0.62
Pre-HIFU PSA (ng/ml)	2	5.45	0.013*
Size of lesion (mm)	25.6	20.75	0.16
RP Gleason score			P = 0.01*
Missing	1	3	
≤6	4	0	
3+4	3	1	
4+3	1	4	
>7	0	2	
Local recurrence biopsy			P = 0.62
Gleason score pre-HIFU			
≤6	4	3	
3+4	1	2	
4+3	1	2	
>7	1	2	
Scarcely differentiated	0	1	
Not specified	2	0	
Follow-up, median (month)	42	62	
RRP to HIFU			
Mean	47.3	32	0.40

* P <0.05.

normal results at DRE of the prostatic fossa in the presence of a detectable PSA value, regardless of the results of prostatic fossa biopsy [16].

For patients with biopsy-proven or radiographically identified local recurrence after RP and in absence of identifiable metastatic disease, SRT is the standard treatment. However, it is a time-consuming therapy (it takes several weeks to complete); moreover, the potential gastrointestinal and genitourinary toxicity could be physically challenging for elderly patients with co-morbidities or lower performance status [8]. Furthermore, SRT has been found to be less successful in palpable than nonpalpable local recurrence [17].

Recently, Siddiqui et al. [9] published their study on the salvage cryotherapy for biopsy-proven local recurrence of CaP after RP, reporting a success rate of 40% (6/15) and a failure rate of 60% (9/15), defined as a PSA increase greater than 0.1 ng/ml from the PSA nadir or the addition of EBRT or ADT. They also found that pre-RP and RP Gleason scores as well as lesion size were significantly lower in the success group than in the failure one. They concluded that salvage cryotherapy can be an effective and safe treatment modality, especially for patients with favorable biopsy and pathologic Gleason scores, before cryotherapy.

HIFU, a minimally invasive procedure, has been shown to provide good outcomes with limited morbidity in the treatment of CaP [18–21]. HIFU acts through coagulative necrosis of the tissue to destroy prostate cells without damaging the intervening structures [22,23]. It can be used as primary therapy with effective long-term cancer control in

patients with low- or intermediate-risk localized CaP [10]. It has also demonstrated its efficacy as a salvage treatment after primary HIFU or external beam radiation therapy (EBRT) [11].

Murota-Kawano et al. [8] published their preliminary experience on the role of salvage HIFU after RP. In their small study, 3/4 enrolled patients had RT+ADT as primary salvage treatment after RP. At 24-month of follow-up, 2/4 patients were BCR-free (defined as an increase in PSA level >0.2 ng/ml). No complications were observed.

To our knowledge, we present the largest series of salvage first-line HIFU after RP published till now.

The treatment were feasible in all cases with no major complications (Grades IV and V, according to the Clavien classification) and an acceptable morbidity profile. Four Grade III (2 Grade IIIa and 2 Grade IIIb) early complications were recorded. Cases of acute urinary retention could be explained by the local tissue inflammation/edema, usually resolved by a prolonged catheterization. Urinary incontinence is the result of thermal damage to the structures involved in the distal continence mechanism. In our series, 2 cases of mild to moderate incontinence were resolved after pelvic-floor muscle exercises, while 2 patients needed surgery.

It has to be underlined that HIFU was performed in the “re-treatment” modality: it means that a smaller quantity of focused energy is applied for less time (4 instead of 5 seconds for each shot) to recurrent cancer tissue (with regard to standard HIFU treatment). Consequently, the damage to the surrounding structures (including rectal wall and external urethral sphincter) is lower, minimizing the risk of complications, such as urethro-rectal fistula, anastomotic strictures, and incontinence. Considering also the acquired experience with HIFU as a primary treatment of CaP (almost 400 cases treated since 2003 in our center), the low morbidity rate observed in our study appears reasonable.

According to our definition, 9/19 patients (47.4%) were classified as success at our median follow-up of 48 months. Failure cases with positive biopsy of the treated lesion were treated with SRT, while MAB was applied in case of negative biopsy. In an intention-to-treat analysis, among the failure cases, 7 are currently free of BCR, increasing the percentage of bDFS patients to 16/19 (84%). Even though our results seem promising, the low number of patients treated and the absence of a control arm do not allow definitive conclusions on the oncologic efficacy of the procedure. The study population was not planned in advance, since this was a pilot study aiming to evaluate primarily the feasibility, safety, and morbidity profile of the technique. Moreover, the absence of an extended follow-up could be considered another limit since significant disease recurrence may occur with extended follow-up [24]. However, our outcomes could be used to design a prospective randomized trial, with adequate statistical power, comparing HIFU vs. SRT in the treatment of the palpable, local recurrence of CaP after RP.

The analysis of the factors that potentially influence the oncologic efficacy of the procedure revealed that a higher

pre-HIFU total PSA and/or a not-favorable Gleason score of the RP specimen could be associated with higher failure rate. As observed in previous studies for SRT [25], our study seems to confirm that lower serum PSA level prior to salvage HIFU is a predictor of favorable response. Similarly, an increased percentage of high-grade RP Gleason scores (4+3 or greater) was observed in the HIFU failure group compared with the success group (12.5% vs. 86%; $P = 0.01$), suggesting that favorable Gleason Score could be associated with better outcomes.

In our study, salvage first-line HIFU for palpable and biopsy-proven local recurrence after RP failure presented better results compared with salvage RT in the same setting. MacDonald et al. [17] reported a limited efficacy of SRT in the treatment of locally palpable recurrence after RP (42 patients) with a 5-year bDFS of 27% at 5-year follow-up. A much lower bDFS (11% at 5-year follow-up) was reported by Choo et al. [26] in 44 patients with palpable recurrence after RP. The difference in the median follow-up (4 vs. 5 years) and in the number of patients recruited could partially justify the observed bDFS in our study compared with the aforementioned ones.

Moreover, it should be underlined that in both salvage HIFU and in SRT, failure rate could be influenced by staging problems due to poorly sensitive methods being used to distinguish between local and distant recurrence [12], such as digital rectal examination (DRE), nuclear bone scanning, transrectal ultrasonography of the prostatic fossa, computed tomography (CT), magnetic resonance (MR) imaging, monoclonal antibody scanning, and positron emission tomography (PET), as well as clinical parameters such as interval from RP to PSA recurrence, postoperative PSA velocity [27], or postoperative PSA level doubling time [28]. Thus the final oncologic outcomes may be hindered since many patients who receive definitive local salvage therapy harbor micrometastases, suggesting the need of careful patient selection in order to achieve better outcomes.

Lastly, the absence of a cost analysis could represent another limitation of our study and should be part of a larger prospective trial.

5. Conclusions

HIFU as salvage first-line treatment for palpable, TRUS-evidenced, biopsy-proven local recurrence of CaP is a feasible, minimally invasive day-case procedure, with an acceptable morbidity profile. It seems to have good cancer control in the short- and mid-term. Patients with lower pre-HIFU PSA level and favorable pathologic Gleason score seem to present better oncologic outcomes. A prospective randomized trial with an adequate recruitment and follow-up is necessary to confirm our preliminary oncologic results.

References

- [1] Landis SH, Murray T, Bolden S, et al. Cancer statistics, 1999. *CA Cancer J Clin* 1999;49:8–31.
- [2] Gerber GS, Thisted RA, Scardino PT, et al. Results of radical prostatectomy in men with clinically localized prostate cancer. *JAMA* 1996;276:615–9.
- [3] Pound CR, Partin AW, Eisenberger MA, et al. Natural history of progression after PSA elevation following radical prostatectomy. *JAMA* 1999;281:1591–7.
- [4] Heidenreich A, Aus G, Bolla M, et al. EAU guidelines on prostate cancer. *Eur Urol* 2008;53:68–80.
- [5] Stephenson AJ, Shariat SF, Zelefsky MJ, et al. Salvage radiotherapy for recurrent prostate cancer after radical prostatectomy. *JAMA* 2004;291:1325–32.
- [6] Stephenson AJ, Scardino PT, Kattan MW, et al. Predicting the outcome of salvage radiation therapy for recurrent prostate cancer after radical prostatectomy. *J Clin Oncol* 2007;25:2035–41.
- [7] Chalasani V, Iansavichene AE, Lock M, et al. Salvage radiotherapy following radical prostatectomy. *Int J Urol* 2009;16:31–6.
- [8] Murota-Kawano A, Nakano M, Hongo S, et al. Salvage high-intensity focused ultrasound for biopsy-confirmed local recurrence of prostate cancer after radical prostatectomy. *BJU Int* 2010;105:1642–5.
- [9] Siddiqui SA, Mynderse LA, Zincke H, et al. Treatment of prostate cancer local recurrence after radical retropubic prostatectomy with 17-Gauge interstitial transperineal cryoablation: Initial experience. *Urology* 2007;70:80–5.
- [10] Blana A, Murat FJ, Walter B, et al. First analysis of the long-term results with transrectal HIFU in patients with localized prostate cancer. *Eur Urol* 2008;53:1194–201.
- [11] Murat FJ, Poissonnier L, Rabilloud M, et al. Mid-term results demonstrate salvage high-intensity focused ultrasound (HIFU) as an effective and acceptably morbid salvage treatment option for locally radiorecurrent prostate cancer. *Eur Urol* 2009;55:640–9.
- [12] Leventis AK, Shariat AF, Slawin KM. Local recurrence after radical prostatectomy: Correlation of US features with prostatic fossa biopsy findings. *Radiology* 2001;219:432–9.
- [13] Dindo D, Demartines N, Clavien PA. Classification of surgical complications: A new proposal with evaluation in a cohort of 6,336 patients and results of a survey. *Ann Surg* 2004;240:205–13.
- [14] Blana A, Brown SC, Chaussy C, et al. High-intensity focused ultrasound for prostate cancer: Comparative definitions of biochemical failure. *BJU Int* 2009;104:1058–62.
- [15] Heidenreich A, Aus G, Bolla M, et al. EAU guidelines on prostate cancer. *Eur Urol* 2008;53:68–80.
- [16] Pound CR, Partin AW, Epstein JI, et al. Prostate-specific antigen after anatomic radical retropubic prostatectomy: Patterns of recurrence and cancer control. *Urol Clin North Am* 1997;24:395–406.
- [17] MacDonald OK, Schild SE, Vora S, et al. Salvage radiotherapy for men with isolated rising PSA or local palpable recurrence after radical prostatectomy: Do outcomes differ? *Urology* 2004;64:760–4.
- [18] Rebillard X, Gelet A, Davin JL, et al. Transrectal high-intensity focused ultrasound in the treatment of localized prostate cancer. *J Endourol* 2005;19:693–701.
- [19] Blana A, Walter B, Rogenhofer S, et al. High-intensity focused ultrasound for the treatment of localized prostate cancer: 5-Year experience. *Urology* 2004;63:297–300.
- [20] Chaussy C, Thuroff S, Rebillard X, et al. Technology insight: High-intensity focused ultrasound for urologic cancers. *Nat Clin Pract Urol* 2005;2:191–8.
- [21] Thuroff S, Chaussy C, Vallancien G, et al. High-intensity focused ultrasound and localized prostate cancer: Efficacy results from the European multicentric study. *J Endourol* 2003;17:673–7.

- [22] Chapelon JY, Margonari J, Vernier F, et al. In vivo effects of high-intensity ultrasound on prostatic adenocarcinoma Dunning R3327. *Cancer Res* 1992;52:6353–7.
- [23] Oosterhof GO, Cornel EB, Smits GA, et al. Influence of high-intensity focused ultrasound on the development of metastases. *Eur Urol* 1997;32:91–5.
- [24] Ward JF, Blute ML, Slezak J, et al. The long-term clinical impact of biochemical recurrence of prostate cancer 5 or more years after radical prostatectomy. *J Urol* 2003;170:1872–6.
- [25] Stephenson AJ, Scardino PT, Kattan MW, et al. Predicting the outcome of salvage radiation therapy for recurrent prostate cancer after radical prostatectomy. *J Clin Oncol* 2007;25:2035–41.
- [26] Choo R, Morton G, Danjoux C, et al. Limited efficacy of salvage radiotherapy for biopsy confirmed or clinically palpable local recurrence of prostate carcinoma after surgery. *Radiother Oncol* 2005;74:163–7.
- [27] Partin AW, Pearson JD, Landis PK, et al. Evaluation of serum prostate-specific antigen velocity after radical prostatectomy to distinguish local recurrence from distant metastases. *Urology* 1994;43:649–59.
- [28] Patel A, Dorey F, Franklin J, et al. Recurrence patterns after radical retropubic prostatectomy: Clinical usefulness of prostate specific antigen doubling times and log slope prostate specific antigen. *J Urol* 1997;158:1441–5.

available at www.sciencedirect.com
journal homepage: www.europeanurology.com



European Association of Urology



Prostate Cancer

Salvage Radiotherapy After High-Intensity Focussed Ultrasound for Recurrent Localised Prostate Cancer

Julien Riviere^a, Jean-Christophe Bernhard^a, Grégoire Robert^a, Hervé Wallerand^a,
Edouard Deti^b, Sylvie Maurice-Tison^b, Jean-Michel Ardiet^c, Jean-Philippe Maire^d,
Pierre Richaud^e, Jean-Marie Ferriere^a, Philippe Ballanger^a, Albert Gelet^f, Gilles Pasticier^{a,*}

^a Urology Department, Hôpital Universitaire Pellegrin, Bordeaux, France

^b ISPED (Institut de Santé Publique, d'Epidémiologie et de Développement), University Bordeaux, Bordeaux, France

^c Radiation Therapy Department, Clinique Saint-Jean, Lyon, France

^d Radiation Therapy Department, Hôpital Universitaire Pellegrin, Bordeaux, France

^e Radiation Therapy Department, Institut Bergonié, Bordeaux, France

^f Urology Department, Hôpital Edouard Herriot, Lyon, France

Article info

Article history:

Accepted June 1, 2010

Published online ahead of
print on June 11, 2010

Keywords:

HIFU

Local recurrence

Minimally invasive surgery

Oncologic control

Prognostic factors

Prostate cancer

Salvage radiotherapy

Tolerance

Toxicity

Abstract

Background: Radiotherapy is a treatment option in the case of local failure following treatment for localised prostate cancer with high-intensity focussed ultrasound (HIFU).

Objective: Our aim was to evaluate tolerance and oncologic control with salvage radiotherapy (SRT) after HIFU failure and to identify predictive factors of success.

Design, setting, and participants: From March 1995 to March 2008, all patients who presented with histologically proven persistent local disease following HIFU and were treated with curative intent SRT (with or without hormonal treatment) were included in this single-centre retrospective study.

Intervention: Patients underwent conformal radiotherapy. The median dose of conformal treatment was 72 Gy (65–78 Gy).

Measurements: The primary outcome measure was progression-free survival (PFS) defined as no biochemical relapse (three consecutive rises in prostate-specific antigen [PSA] with a velocity >0.4 ng/ml per year or PSA >1.5 ng/ml) and no additional treatment. Predictive factors of failure were examined in univariate and multivariate analyses. Adverse events in terms of urinary and digestive toxicity, urine incontinence, and erectile dysfunction (ED) were reported.

Results and limitations: The median (range) and mean (standard deviation) follow-up of the 100 patients analysed was 33 mo (5–164 mo) and 37.2 mo (23.6 mo), respectively. Eighty-three patients received SRT alone, and 17 received SRT and androgen-deprivation therapy. For the 83 patients treated with exclusive radiation therapy, PFS was 72.5% at 5 yr and 93%, 67%, and 55% for the low-, intermediate-, and high-risk groups, respectively. In the univariate analysis, PSA level prior to SRT, risk status, PSA nadir after SRT, PSA nadir after SRT >0.2 ng/ml, and time to achieve this nadir were all predictive of failure. In the multivariate analysis, PSA nadir post-SRT with a threshold at 0.2 ng/ml and time to achieve this nadir were the significant predictive factors of failure. Gastrointestinal toxicity was low; urinary toxicity grade ≤2 was 34.5%. Four were grade 3 (4.7%), one was grade 4 (1.2%), and one was grade 5 (1.2%). The incidence of severe ED (International Index of Erectile Dysfunction-5 score 5–10) was 14% pre-HIFU, and 51.9% and 82.3% pre- and post-SRT, respectively. Because our study was retrospective, results have to be interpreted cautiously.

Conclusions: SRT provides satisfactory oncologic control after HIFU failure with little (or mild) additional toxicity. These results warrant further investigation.

© 2010 European Association of Urology. Published by Elsevier B.V. All rights reserved.

* Corresponding author. Praticien Hospitalier, Service d'Urologie et de la Transplantation, Hôpital Pellegrin, 11ème étage, Place Amélie Raba Léon, 33076 Bordeaux Cédex, France.
Tel. +33 5 56 79 98 42; Fax: +33 5 56 79 56 51.

E-mail address: gilles.pasticier@chu-bordeaux.fr (G. Pasticier).

1. Introduction

Although not validated and still controversial, feasibility and outcome with high-intensity focussed ultrasound (HIFU) in the treatment of localised prostate cancer has been established in recent years with encouraging biochemical disease-free survival rates reported [1,2]. Salvage radiotherapy (SRT) has been widely used for many years after radical prostatectomy [3], even though its benefit, the ideal candidate, and the optimal time to initiate treatment remain unclear [4–6]. An initial study on SRT after HIFU failure revealed encouraging results in a small group of patients [7]. The current report focuses on an update of the original patient series with the aim of identifying predictive factors for success of SRT for HIFU failure.

2. Patients and methods

2.1. Patient cohort

Included in this retrospective study were consecutive patients with histologically proven localised disease after one or two HIFU sessions and who were treated with external-beam radiotherapy (EBRT) with or without hormonal treatment. Patients had presented between March 1995 and March 2008 at one institution (E. Herriot University Hospital, Lyon, France) and had been selected for HIFU according to the French urologic association oncologic committee [8]. Only those patients with a minimum follow-up of 1 yr were included. Local relapse was proven by positive biopsy and the absence of extraprostatic disease on magnetic resonance imaging (MRI), computed tomography (CT) thoraco-abdominal scan, and CT bone scan. HIFU and SRT were conducted as previously described [7,9]. Patients were categorised before HIFU into low-, intermediate-, and high-risk categories according to the D'Amico classification [10]. The primary outcome was progression-free survival (PFS), which was defined on the basis of no biochemical relapse (three consecutive rises in prostate-specific antigen [PSA] with a velocity >0.4 ng/ml per year or PSA >1.5 ng/ml) and no additional treatment. All patients completed a self-assessment questionnaire, which included the Common Terminology Criteria for Adverse Event (CTCAE) v.3 [11], the Ingelman-Sundberg [12], and the International Index of Erectile Function (IIEF)-5 [13]. The CTCAE v.3 score was transformed into a questionnaire so that patients were able to self-administer it. Patients completed the assessment prior to HIFU therapy, post-HIFU, immediately prior to SRT, at 3 mo post-SRT, and at 1 yr post-SRT.

The CTCAE v.3 assessed tolerance of SRT after HIFU including urinary and gastrointestinal adverse events (AEs). Events were categorised as follows: grade 1, mild; grade 2, moderate; grade 3, severe; grade 4: life threatening or disabling; and grade 5, death related to AE. The Ingelman-Sundberg score was used to assess urinary incontinence. Grade 1 was defined as urinary incontinence for strong effort, grade 2 as urinary incontinence for moderate effort, and grade 3 as urinary incontinence for minimal effort. The IIEF-5 score ranges from a minimum of 5 (severe erectile dysfunction [ED]) to a maximum of 25 (no ED). The IIEF-5 was completed prior to HIFU, post-HIFU, immediately pre-SRT, and at 1 yr post-SRT.

2.2. Statistical analysis

Statistical analysis was performed with EPI Info and the SAS (Cary, NC, USA) program. PSA nadir as a major issue after SRT was analysed both as a continuous variable and as a noncontinuous variable with a threshold tested for different levels. Survival analysis was conducted according to

the log-rank test, and the Cox regression model was performed in multivariate analysis to identify predictive factors of failure. A p value of <0.05 was considered statistically significant.

3. Results

3.1. Patient characteristics

From March 1995 to March 2008, 870 patients underwent one or two HIFU sessions. Of these 870 patients, 156 underwent SRT and of these, 100 who had histologically proven local evidence of cancer with a minimum of 1-yr follow-up were selected for analysis (Table 1). Among these 100 consecutive patients, 83 received EBRT alone; 17 received EBRT and additional androgen-deprivation therapy (ADT). ADT included luteinising hormone-releasing hormone agonists, which were administered for 3 yr in five patients and 6 mo in 12 patients. The mean number of previous HIFU sessions conducted was 1.8. SRT was performed with a median (range) delay of 10 (2–53) mo after the last HIFU. The median (range) number of biopsies performed for each patient was 7 (2–14) with 65% of patients having at least sextant biopsies. All patients underwent conformal treatment with a median dose of 72 Gy (65–78 Gy). Median (range) and mean (standard deviation [SD]) follow-up were 33.0 mo (5–164 mo) and 37.2 mo (23.6 mo), respectively.

3.2. Primary outcome: oncologic control for 83 patients having received exclusive salvage radiotherapy

Median (range) and mean (SD) follow-up were 36.5 mo (5–164 mo) and 39.4 mo (24.2 mo), respectively. Median (range) PSA nadir after SRT was 0.09 (0–6.1) ng/ml with a median (range) time to nadir of 17.5 mo (2–48 mo). A total of 15 patients failed therapy according to the definition

Table 1 – Patient characteristics before high-intensity focussed ultrasound and before salvage radiotherapy treatment (n = 100)

Parameter	Prior HIFU Value	Prior SRT Value
Age, median (range), yr	71 (54–81)	72 (56–84)
PSA, mean (SD), ng/ml	9.85 (4.9)	2.1 (1.8)
PSA, median (range), ng/ml	8.9 (1.84–20.11)	1.5 (0–8.95)
Prostate volume, mean (SD), ml	24.4 (8.9)	10 (9)
Patients by clinical stage (TNM 2002), %		
cT1	48	–
cT2	50	–
cT3	2	–
Patients by Gleason score, %		
≤ 6	61	–
7	31	–
≥ 8	8	–
Patients by risk group, %		
Low	8	–
Intermediate	56	–
High	16	–

HIFU = high-intensity focussed ultrasound; PSA = prostate-specific antigen; SD = standard deviation; SRT = salvage radiotherapy.

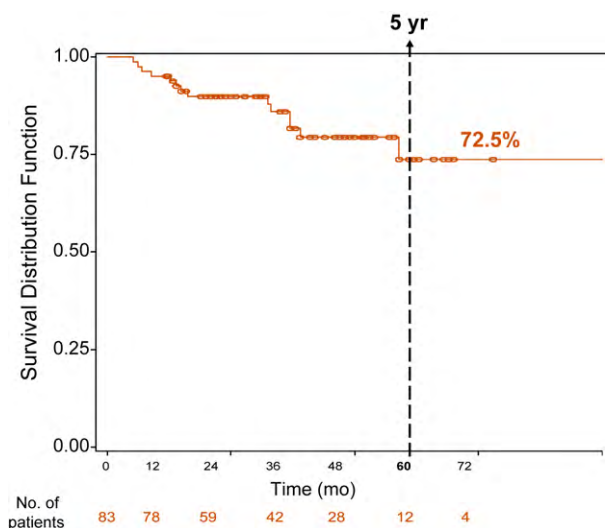


Fig. 1 – Progression-free survival for 83 patients treated by radiotherapy alone.

applied. In this group of patients, the median (range) PSA level pre-SRT was 3.76 (0.5–8.11) ng/ml, and the post-SRT PSA nadir was 0.78 (0–3.8) ng/ml. This compares with a pre-SRT PSA level of 1.3 (0.1–7) ng/ml and a post-SRT PSA nadir of 0.07 (0.02–1.41) ng/ml in patients not failing SRT. In the 15 patients failing treatment, hormonal therapy was given after a median time of 25 mo (5–64 mo) post-SRT. PFS for these 83 patients was 72.5% at 5 yr and 93.0%, 67.0%,

and 55.0% for low-, intermediate-, and high-risk groups, respectively (Figs. 1 and 2).

In univariate analysis, PSA pre-SRT, risk group status, PSA nadir post-SRT, PSA nadir post-SRT >0.2 ng/ml, and time to achieve this nadir were all predictors of failure of SRT (Fig. 3; Table 2). Gleason score, clinical stage, radiation dose, threshold of irradiation dose at 72 Gy, location of positive biopsies, percentage of positive biopsies <33%, 33–50%, and >50%, and prostate volume were not significant factors for failure of SRT. In multivariate analysis, PSA nadir post-SRT with a threshold at 0.2 ng/ml and time to achieve this nadir were both significant predictors of failure. Ten patients died, including one due to prostate cancer (metastatic dissemination); mean time of death was 4.5 yr post-SRT.

3.3. Safety

Of the 100 patients in the study, 85 (94.5%) answered the combined questionnaire. Table 3 shows the overall incidences of urinary and gastrointestinal AEs. Early events were defined as those occurring within 3 mo of radiotherapy, and late AEs were defined as those occurring at 1 yr or later. No major gastrointestinal toxicity was reported and, in particular, no cases of rectourethral fistula. Most of the grade 1 and 2 urinary toxicities were represented by urgency. Three patients experienced an acute urinary retention requiring a transurethral resection of the prostate (grade 3). One patient underwent a urinary diversion due to a chronic painful retention (grade 4). One patient died of multiorgan failure after a haemostatic cystectomy (grade 5). Fig. 4 shows the rates of urinary incontinence pre- and post-SRT. Urinary

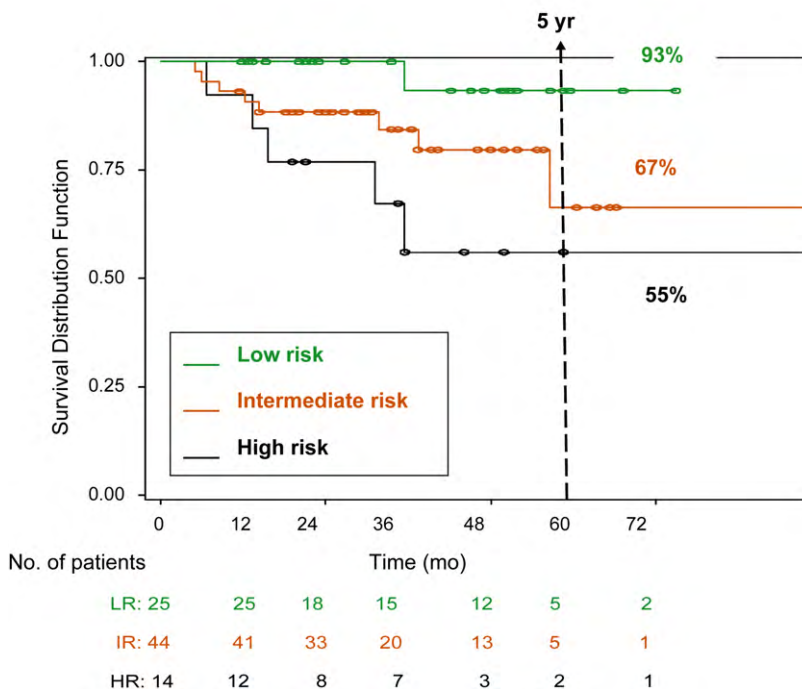


Fig. 2 – Progression-free survival according to risk group following salvage radiotherapy. LR = low risk; IR = intermediate risk; HR = high risk.

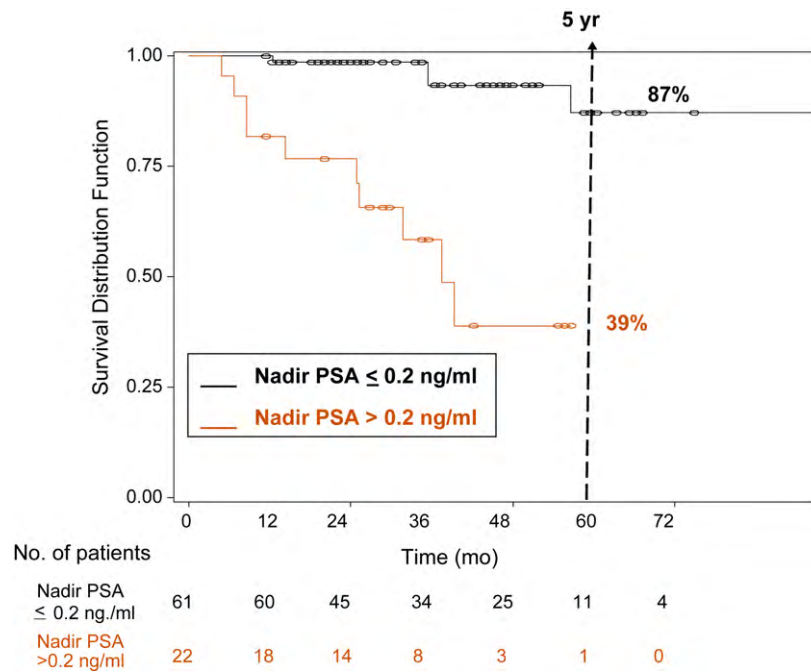


Fig. 3 – Progression-free survival according to prostate-specific antigen (PSA) nadir following salvage radiotherapy.

Table 2 – Univariate and multivariate analysis of risk factors for failure of salvage radiotherapy in patients failing high-intensity focussed ultrasound

Risk factor	Univariate analysis			Multivariate analysis		
	p value	HR*	95% CI*	p value	HR*	95% CI*
PSA pre-SRT, ng/ml	0.0035	1.43	1.12–1.8	0.223	1.197	0.896–1.599
PSA nadir post-SRT, ng/ml	<0.0001	6.5	2.45–12.1	<0.0001	6.5	3.45–13.85
PSA nadir post-SRT, <0.2 mg/ml or >0.2 ng/ml	<0.0001	12.4	3.8–40.3	<0.0001	15.1	4.17–54.62
Time to PSA nadir post-SRT, mo	0.02	1.3	1.05–2.12	0.018	0.9	0.83–0.98

CI = confidence interval; HR = hazard ratio; PSA = prostate-specific antigen; SRT = salvage radiotherapy treatment.
 * HRs and 95% CIs were derived from a Cox regression model.

incontinence (grades 1–3) increased from 28% before SRT to 32% at 1 yr post-SRT, with a peak of 39% in the 3 mo following SRT. The difference before SRT and at 1 yr after SRT was not statistically significant. A total of 79 patients completed the IIEF-5 questionnaire at all time points; six patients declined

to do so for personal reasons (Fig. 5). Results showed that the severity of ED increased following HIFU therapy and again after SRT.

4. Discussion

HIFU, although still in evaluation, has demonstrated through several publications acceptable oncologic results in the treatment of localised prostate cancer, especially for low- and intermediate-risk disease. The lack of follow-up of numerous series constitutes its main limitation, which makes this treatment still controversial; however, some have confirmed the initial encouraging results with longer follow-up, including 6.4 yr of median follow-up and >5 yr for each patient [13].

It has been shown that about 15% of patients will demonstrate a local relapse and will be therefore be candidates for active surveillance, palliative hormonal treatment, or for curative intent, radical salvage prostatectomy, or EBRT [2,14]. The potential of salvage prostatectomy

Table 3 – Severity of adverse events associated with salvage radiotherapy in patients failing high-intensity focussed ultrasound*

	Grade 1 n (%)	Grade 2 n (%)	Grade ≥3 n (%)
Early GI AEs	28.2 (24)	17.6 (15)	–
Delayed GI AEs	11.8 (10)	2.4 (2)	–
Early urinary AEs	25.8 (22)	33.7 (29)	3.5 (3)
Late urinary AEs	28.2 (24)	27.1 (23)	7.1 (6)

AE = adverse event; GI = gastrointestinal.
 * Early AEs are those occurring within 3 mo; late AEs are those occurring at ≥1 yr. GI AEs are anal incontinence, mucus in stools, diarrhoea, rectal bleeding, haemorrhoids, and/or rectal or abdominal pain. Urinary AEs are retention of urine, urgency, bladder spasms, haematuria, and/or urinary incontinence.

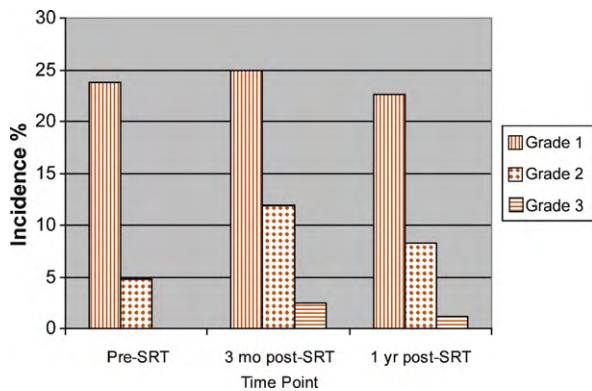


Fig. 4 – Urinary incontinence before and after salvage radiotherapy (SRT) for patients failing high-intensity ultrasound.

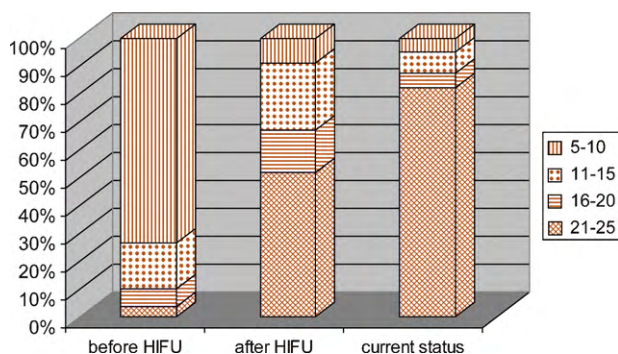


Fig. 5 – International Index of Erectile Dysfunction-5 scores in 79 patients prior to treatment with high-intensity focussed ultrasound (HIFU), following HIFU failure and immediately prior to salvage radiotherapy (SRT) for HIFU failure, and at 1 yr post-SRT. ED = erectile dysfunction.

following HIFU has been demonstrated in small groups of patients [15,16]. In addition, we reported an earlier study on the first 45 patients describing the feasibility of SRT after HIFU failure [7]. This study underlined the importance of choosing this option only in patients who had histologically proven local relapse. The 5-yr disease-free survival was 80% when patients had positive control biopsies, whereas it was only 44% in cases of isolated biochemical recurrence with negative biopsies [7]. In the current cohort of patients, local relapse was proven by positive biopsy, no extraprostatic disease based on MRI, CT thoraco-abdominal scan, and CT bone scan.

To assess the oncologic efficacy of SRT after HIFU, an acceptable definition of success (or failure) was required, taking into consideration the fact that this salvage treatment was made on a prostate gland that had already been treated with HIFU. The Phoenix definition (nadir + 2 ng/ml) would have overestimated the result because it cannot be applied to a prostate having received a preliminary physical treatment (focussed ultrasound). On the contrary, the usual definition of success of SRT after radical prostatectomy (ie, PSA <0.2 ng/ml or undetectable PSA [5,6]) would have underestimated the result because the prostate, in the case of SRT after HIFU, is

still in place. Thus, following the guidelines for patients having a rising PSA after the first treatment [17], a compromise definition was chosen. This involved a combination of the American Society for Therapeutic Radiology and Oncology definition of failure involving three rises in PSA [18] plus PSA velocity >0.4 ng/ml per year or the Bolla definition involving PSA >1.5 ng/ml [19]. The use of adjuvant treatment was considered to be a strong indicator for the failure of salvage treatment. Given that biochemical relapse after radiotherapy occurs usually between the second and third year after radiation [20], we consider that the present study with a mean follow-up of 37 mo probably reflects the true efficacy of salvage radiation after HIFU. The PFS of 72.5% achieved for the 83 patients compares very favourably with the rates of 10–55% described for salvage radiation after radical prostatectomy in a 2008 review [4].

Salvage HIFU after EBRT failure has been explored previously [21,22]. Disease-free survival rates of 53%, 42%, and 25% have been reported for low-, intermediate-, and high-risk patient groups, respectively, in a study of 167 patients with a median follow-up of 18 mo. The equivalent rates for these groups in the current study were 93%, 67%, and 55%, respectively, suggesting that salvage EBRT for HIFU provides a better outcome than vice versa. Multivariate analysis revealed that the major predictive factors for failure of SRT were PSA nadir >0.2 ng/ml and time to achieve this nadir. It has been established that in the case of isolated primary radiation treatment, a nadir PSA value of 0.2 ng/ml, as well as its delay of appearance, are correlated to biochemical-free survival [22–24] and also for the HIFU treatment [25].

In addition to the biopsy and PSA velocity assessment after HIFU, it has been recently shown that multimodality MRI has a great accuracy to detect recurrences within the prostate and guide control biopsies [26].

Although retrospectively collected, and as both the CTCAE v.3 score transformation into a questionnaire and its translation in French can constitute a bias, toxicity of radiation therapy after HIFU does not seem higher than radiation therapy alone with no grade ≥ 3 toxicity reported [27,28]. In the current study, grade 1 and 2 toxicity rates reported are equivalent to these reports. Urinary toxicity of grade ≤ 3 is slightly higher than with radiotherapy alone but not of major concern. One patient died after haemostatic cystectomy. This fatal issue underlines the fact that higher morbidity can occur in the field of salvage prostate cancer treatment when multimodality treatments are envisaged, thus requiring multidisciplinary decision making in the era of multimodality approaches for aggressive disease. Urinary incontinence rates were not significantly increased at 1 yr post-SRT from pre-SRT levels. The level of grade 3 incontinence at 1 yr post-SRT was very low at 1%. The sequence of HIFU followed by SRT was much less aggressive than data reported for salvage HIFU after EBRT failure [21], in which severe incontinence reaches 10% [21]. The follow-up period in the current study seems sufficient to avoid underestimating late complications because several investigators indicate a median interval of 14–18 mo for the appearance of complications [29,30]. With regard to ED rates, these

worsened first after the patients were initially treated with HIFU and then again after SRT. This adverse effect has once again to be balanced against the benefits gained in terms of oncologic outcome.

5. Conclusion

After a preliminary study, our study has confirmed the feasibility of radiation therapy following HIFU. On the basis of oncologic outcome plus acceptable toxicity, SRT can be considered a treatment option for HIFU failures. Oncologic results will be addressed with a longer follow-up.

Author contributions: Gilles Pasticier had full access to all the data in the study and takes responsibility for the integrity of the data and the accuracy of the data analysis.

Study concept and design: Gelet, Pasticier.

Acquisition of data: Riviere, Bernhard, Robert.

Analysis and interpretation of data: Riviere, Pasticier.

Drafting of the manuscript: Riviere, Pasticier, Richaud, Maire, Ardiét.

Critical revision of the manuscript for important intellectual content: Gelet, Pasticier, Waller, Ballanger, Ferriere.

Statistical analysis: Deti, Maurice-Tison.

Obtaining funding: None.

Administrative, technical, or material support: Richaud, Maire.

Supervision: Pasticier, Gelet.

Other (specify): None.

Financial disclosures: I certify that all conflicts of interest, including specific financial interests and relationships and affiliations relevant to the subject matter or materials discussed in the manuscript (eg, employment/affiliation, grants or funding, consultancies, honoraria, stock ownership or options, expert testimony, royalties, or patents filed, received, or pending), are the following: A. Gelet and G. Pasticier are consultants for EDAP.

Funding/Support and role of the sponsor: EDAP TMS reviewed the manuscript.

References

- Blana A, Murat FJ, Walter B, et al. First analysis of the long-term results with transrectal HIFU in patients with localised prostate cancer. *Eur Urol* 2008;53:1194–203.
- Poissonnier L, Chapelon JY, Rouvière O, et al. Control of prostate cancer by transrectal HIFU in 227 patients. *Eur Urol* 2007;51:381–7.
- Catton C, et al. Post-Operative radiotherapy following radical prostatectomy. *Eur Urol Update* 2005;3(2):107–16.
- Pasquier D, Ballereau C. Adjuvant and salvage radiotherapy after prostatectomy for prostate cancer: a literature review. *Int J Radiat Oncol Biol Phys* 2008;72:972–9.
- Stephenson AJ, Shariat SF, Zelefsky MJ, et al. Salvage radiotherapy for recurrent prostate cancer after radical prostatectomy. *JAMA* 2004;291:1325–32.
- Brooks JP, Albert PS, Wilder RB, et al. Long-term salvage radiotherapy outcome after radical prostatectomy and relapse predictors. *J Urol* 2005;174:2204–8.
- Pasticier G, Chapet O, Badet L, et al. Salvage radiotherapy after high-intensity focused ultrasound for localized prostate cancer: early clinical results. *Urology* 2008;72:1305–9.
- Soulié M, Beuzeboc P, Cornud F, et al. Prostatic cancers [in French]. *Prog Urol* 2007;17:1159–230.
- Poissonnier L, Murat F-J, Chapelon J-Y, Gelet A. Indications, techniques et résultats du traitement par ultrasons focalisés (HIFU) du cancer localisé de la prostate. *Ann Urol* 2007;41:237–53.
- D'Amico AV, Moul J, Carroll PR, Sun L, Lubeck D, Chen MH. Cancer-specific mortality after surgery or radiation for patients with clinically localized prostate cancer managed during the prostate-specific antigen era. *J Clin Oncol* 2003;21:2163–72.
- Trotti A. The evolution and application of toxicity criteria. *Semin Radiat Oncol* 2002;12(Suppl 1):1–3.
- Ingelman-Sundberg A, Ulmsten U. Surgical treatment of female urinary stress incontinence. *Contrib Gynecol Obstet* 1983;10:51–69.
- Rosen RC, Riley A, Wagner G, et al. The International Index of Erectile Function (IIEF): a multidimensional scale for assessment of erectile dysfunction. *Urology* 1997;49:822–30.
- Blana A, Walter B, Rogenhofer S, Wieland WF. High-intensity focused ultrasound for the treatment of localized prostate cancer: 5-year experience. *Urology* 2004;63:297–300.
- Stolzberg JU, Bynens B, Do M, et al. Salvage laparoscopic extraperitoneal radical prostatectomy after failed high-intensity focused ultrasound and radiotherapy for localized prostate cancer. *Urology* 2007;70:956–60.
- Liatsikos E, Bynens B, Rabenalt R, et al. Treatment of patients after failed high intensity focused ultrasound and radiotherapy for localized prostate cancer: salvage laparoscopic extraperitoneal radical prostatectomy. *J Endourol* 2008;22:2295–8.
- Scher HI, Eisenberger M, D'Amico AV, et al. Eligibility and outcomes reporting guidelines for clinical trials for patients in the state of a rising prostate-specific antigen: recommendations from the Prostate-Specific Antigen Working Group. *J Clin Oncol* 2004;22:537–56.
- Roach M, Hanks G, Thames Jr H, et al. Defining biochemical failure following radiotherapy with or without hormonal therapy in men with clinically localized prostate cancer: recommendations of the RTOG-ASTRO Phoenix Consensus Conference. *Int J Radiat Oncol Biol Phys* 2006;65:965–74.
- Bolla M, Collette L, Blank L, et al. Long-term results with immediate androgen suppression and external irradiation in patients with locally advanced prostate cancer (an EORTC study): a phase III randomised trial. *Lancet* 2002;360:103–6.
- Hanlon AL, Diratzouian H, Hanks GE. Posttreatment prostate-specific antigen nadir highly predictive of distant failure and death from prostate cancer. *Int J Radiat Oncol Biol Phys* 2002;53:297–303.
- Murat FJ, Poissonnier L, Rabilloud M, et al. Mid-term results demonstrate salvage high-intensity focused ultrasound (HIFU) as an effective and acceptably morbid salvage treatment option for locally radiorecurrent prostate cancer. *Eur Urol* 2009;55:640–9.
- Gelet A, Chapelon JY, Poissonnier L, et al. Local recurrence of prostate cancer after external beam radiotherapy: early experience of salvage therapy using high-intensity focused ultrasonography. *Urology* 2004;63:625–9.
- Shipley WU, Thames HD, Sandler HM, et al. Radiation therapy for clinically localized prostate cancer: a multi-institutional pooled analysis. *JAMA* 1999;281:1598–604.
- Critz FA. Time to achieve a prostate-specific antigen nadir of 0.2 ng/ml after simultaneous irradiation for prostate cancer. *J Urol* 2002;168:2434–8.
- Ganzer R, Rogenhofer S, Walter B, et al. PSA nadir is a significant predictor of treatment failure after high-intensity focussed ultrasound (HIFU) treatment of localised prostate cancer. *Eur Urol* 2008;53:547–53.
- Rouvière O, Girouin N, Glas L, et al. Prostate cancer transrectal HIFU ablation: detection of local recurrences using T2-weighted and dynamic contrast-enhanced MRI. *Eur Radiol* 2010;20:48–55.
- Kupelian PA, Willoughby TR, Reddy CA, et al. Hypofractionated intensity-modulated radiotherapy (70 Gy at 2.5 Gy per fraction) for

- localized prostate cancer: Cleveland Clinic experience. *Int J Radiat Oncol Biol Phys* 2007;68:1424–30.
- [28] Zelefsky MJ, Levin EJ, Hunt M, et al. Incidence of late rectal and urinary toxicities after three-dimensional conformal radiotherapy and intensity-modulated radiotherapy for localized prostate cancer. *Int J Radiat Oncol Biol Phys* 2008;70:1124–9.
- [29] Schultheiss TE, Lee WR, Hunt MA, et al. Late GI and GU complications in the treatment of prostate cancer. *Int J Radiat Oncol Biol Phys* 1997;37:3–11.
- [30] Lawton CA, Won M, Pilepich MV, et al. Long-term treatment sequelae following external beam irradiation for adenocarcinoma of the prostate: analysis of RTOG studies 7506 and 7706. *Int J Radiat Oncol Biol Phys* 1991;21:935–9.